This is a digital copy of a book that was preserved for generations on library shelves before it was carefully scanned by Google as part of a project to make the world's books discoverable online.

It has survived long enough for the copyright to expire and the book to enter the public domain. A public domain book is one that was never subject to copyright or whose legal copyright term has expired. Whether a book is in the public domain may vary country to country. Public domain books are our gateways to the past, representing a wealth of history, culture and knowledge that's often difficult to discover.

Marks, notations and other marginalia present in the original volume will appear in this file - a reminder of this book's long journey from the publisher to a library and finally to you.

Usage guidelines

Google is proud to partner with libraries to digitize public domain materials and make them widely accessible. Public domain books belong to the public and we are merely their custodians. Nevertheless, this work is expensive, so in order to keep providing this resource, we have taken steps to prevent abuse by commercial parties, including placing technical restrictions on automated querying.

We also ask that you:

+ *Make non-commercial use of the files* We designed Google Book Search for use by individuals, and we request that you use these files for personal, non-commercial purposes.
+ *Refrain from automated querying* Do not send automated queries of any sort to Google's system: If you are conducting research on machine translation, optical character recognition or other areas where access to a large amount of text is helpful, please contact us. We encourage the use of public domain materials for these purposes and may be able to help.
+ *Maintain attribution* The Google "watermark" you see on each file is essential for informing people about this project and helping them find additional materials through Google Book Search. Please do not remove it.
+ *Keep it legal* Whatever your use, remember that you are responsible for ensuring that what you are doing is legal. Do not assume that just because we believe a book is in the public domain for users in the United States, that the work is also in the public domain for users in other countries. Whether a book is still in copyright varies from country to country, and we can't offer guidance on whether any specific use of any specific book is allowed. Please do not assume that a book's appearance in Google Book Search means it can be used in any manner anywhere in the world. Copyright infringement liability can be quite severe.

About Google Book Search

Google's mission is to organize the world's information and to make it universally accessible and useful. Google Book Search helps readers discover the world's books while helping authors and publishers reach new audiences. You can search through the full text of this book on the web at `http://books.google.com/`

BOSTON
MEDICAL LIBRARY
8 THE FENWAY

TRANSACTIONS

OF THE

PATHOLOGICAL SOCIETY OF LONDON.

VOLUME SEVENTH.

INCLUDING THE REPORT OF THE PROCEEDINGS FOR THE SESSION 1855–6.

LONDON:
PRINTED FOR THE SOCIETY BY J. W. ROCHE, 15, COTTAGE ROW, BERMONDSEY.
1856.

30004

THE present publication being the Seventh Volume of Transactions, constitutes the Tenth published Annual Report of the Pathological Society's proceedings.

The COUNCIL think it right to repeat, that the exhibitors are alone responsible for the descriptions given of the Specimens exhibited by them, the only change made in the Reports furnished by the authors being such verbal alterations as were absolutely necessary.

33, GEORGE STREET, HANOVER SQUARE,
September, 1856.

TABLE OF CONTENTS

OF VOLUME VII.

	PAGE
Lists of Presidents; and of Officers and Members during the Session 1855–56	I
Lists of Specimens Exhibited during the Session 1855–56	XV
Diseases, etc. of the Nervous System . . .	1
Diseases, etc. of the Organs of Respiration . .	45
Diseases, etc. of the Organs of Circulation . .	72
Diseases, etc. of the Organs of Digestion. . .	178
Diseases, etc. of the Urinary and Generative Organs	241
Diseases, etc. of the Osseous System	282
Diseases, etc. of the Organs of Special Sense . .	324
Miscellaneous Specimens, Tumors, Entozoa, etc.	337
Index	403

Former Presidents.

ELECTED	
1846	CHARLES J. B. WILLIAMS, M.D. F.R.S.
1848	CHARLES ASTON KEY, Esq.
1850	PETER MERE LATHAM, M.D.
1852	CÆSAR H. HAWKINS, Esq.
1853	BENJAMIN GUY BABINGTON, M.D., F.R.S.

OFFICERS AND COUNCIL

OF

The Pathological Society of London,

ELECTED AT

THE GENERAL MEETING, JANUARY 1, 1856.

President.

JAMES MONCREIFF ARNOTT, Esq., F.R.S.

Vice-Presidents.

THOMAS BEVILL PEACOCK, M.D.
HENRY BENCE JONES, M.D., F.R.S.
WILLIAM JOHN LITTLE, M.D.
JAMES RISDON BENNETT, M.D.
WILLIAM FERGUSSON, Esq., F.R.S.
PRESCOTT GARDNER HEWETT, Esq.
JOHN SIMON, Esq., F.R.S.
EDWARD COCK, Esq.

Treasurer.

ALEXANDER SHAW, Esq.

Council.

EDWARD HENRY SIEVEKING, M.D.
WILLIAM BALY, M.D. F.R.S.
JOHN SYER BRISTOWE, M.D.
JOHN WILLIAM OGLE, M.D.
SAMUEL OSBORNE HABERSHON, M.D.
EDMUND LLOYD BIRKETT, M.D.
CHARLES WEST, M.D.
FRANCIS SIBSON, M.D.
WILLIAM CAMPS, M.D.
JAMES DIXON, Esq.
GEORGE POLLOCK, Esq.
HENRY GRAY, Esq., F.R.S.
WILLIAM BOWMAN, Esq., F.R.S.
HENRY HAYNES WALTON, Esq.
HENRY OBRE, Esq.
JOHN MORGAN, Esq.
WILLIAM AUGUSTUS HILLMAN, Esq.
WILLIAM OLIVER CHALK, Esq.
JONATHAN HUTCHINSON, Jun. Esq.

Honorary Secretaries.

RICHARD QUAIN, M.D. | MITCHELL HENRY, Esq.

**** Members are requested to indicate to the Secretaries, corrections when necessary.*

LIST OF MEMBERS OF THE SOCIETY.

Honorary Members.

ALISON, WILLIAM PULTENEY, M.D., F.R.S., Emeritus Professor of Medicine in the University of Edinburgh.

ANDRAL, G., M.D., Professor in the Faculty of Medicine, Paris.

*BENTLEY, EDWARD, M.D. (formerly Honorary Secretary), Physician to the City of London Hospital for Diseases of the Chest, Hackney.

CARSWELL, SIR ROBERT, M.D., Physician to His Majesty the King of the Belgians, Brussels.

CRAMPTON, SIR PHILIP, Bart., F.R.S., M.R.I.A., Surgeon-General to the Forces in Ireland.

CRUVEILHIER, J. C., M.D., Professor in the Faculty of Medicine, Paris.

HENLE, J., Professor of Anatomy and Physiology in the University of Zurich.

ROKITANSKY, CARL, M.D., Professor of Pathological Anatomy in the University of Vienna.

STOKES, WILLIAM, M.D., M.R.I.A., Regius Professor of Physic in the University of Dublin.

VOGEL, JULIUS, M.D., Professor of Clinical Medicine in the University of Giessen.

Resident and Non-Resident Members.

(C.) Present Members of Council.
† Have paid Life Subscriptions.
* Former Members of Council.
‡ Have paid Composition Fee for Transactions.

GENERAL LIST OF MEMBERS.

Elected Session

**Orig. Memb.* Adams, William, Esq., Assistant Surgeon to the Royal Orthopædic Hospital, 5, Henrietta-street, Cavendish-square.

1847-48 Aikin, Charles A., Esq., 8, Southwick-street.

1851-52 Allchin, William Henry, M.B., 7, Pembridge-villas, Westbourne-grove.

1853-54 Ancell, Henry, Esq., Surgeon to the Western General Dispensary, 3, Norfolk-crescent, Hyde-park.

Elected Session

1854-55 Armitage, Thomas Rhodes, M.D., Physician to St. Marylebone General Dispensary, 75, Wimpole-street.

**Orig. Memb.* Arnott, James Moncreiff, Esq., F.R.S. (President), 2, New Burlington-street.

1851-52 Ashton, T. J., Esq., Surgeon to the Blenheim-street Dispensary, 31, Cavendish-square.

Orig. Memb. Ashwell, Samuel, M.D., 30, Brook-street.

Orig. Memb. Babington, Benjamin Guy, M.D., F.R.S. (late President), late Physician to Guy's Hospital, 31, George-street, Hanover-square.

1854-55 Babington, C. Metcalf, L.R.C.P., Physician Accoucheur to Queen Charlotte's Lying-in Hospital, 20, Hertford-street, May-fair.

1849-50 Ballard, Thomas, Esq., 10, Southwick-place, Hyde-park.

1850-51 Baly, William, M.D., F.R.S. (C.), Physician to the Penitentiary, Millbank, and Assistant Physician to St. Bartholomew's Hospital, 45, Queen Anne-street, Cavendish-square.

1851-52 Barclay, A. Whyte, M.D., Physician to the Chelsea, &c. Dispensary, 23A, Bruton-street,

Orig. Memb. Barker, Thomas Herbert, M.D., Priory-terrace, Bedford.

1855-56 Barker, T. A., M.D., Senior Physician to St. Thomas's Hospital, 71, Lower Grosvernor-street.

**Orig. Memb.* Barlow, George Hilaro, M.D., Physician to Guy's Hospital, 5, Union-street, Southwark.

1852-53 Barwell, Richard, Esq., Assistant Surgeon to the Charing Cross Hospital, 22, Old Burlington-street.

1852-53 Bartlett, William, Esq., Surgeon to the Kensington Dispensary, Notting-hill.

1851-52 Beale, Lionel S., M.D., Physician to King's College Hospital, 27, Carey-street, Lincoln's-inn.

1855-56 Bealey, A., M.D., M.A., 27, Tavistock-square.

1852-53 Beck, Thomas S., M.D., Physician to the Farringdon Dispensary, 9A, Langham-place.

*1849-50 Beith, Robert, M.D., R.N., "Belle Isle," Hospital-ship.

1846-47 Bennet, James Henry, M.D., Physician Accoucheur to the Royal Free Hospital, 60, Grosvenor-street.

**Orig. Memb.* Bennett, James Risdon, M.D. (V.P.), Physician to St. Thomas's Hospital, and to the City of London Hospital for Diseases of the Chest, 15, Finsbury-square.

1850-51 Benwell, Henry D., Esq., 2, Kent-place, Blackheath-hill.

*1848-49 Bird, James, M.D., late Physician General, Bombay Army, 27, Hyde-park-square.

1855-56 Bird, W., Esq., Brook-green, Hammersmith.

1849-50 Birkett, Edmund Lloyd, M.D., (C.), Physician to the City of London Hospital for Diseases of the Chest, and Curator of the Museum at Guy's Hospital, 48, Russell-square.

Elected Session

Orig. Memb. Birkett, John, Esq., Surgeon to Guy's Hospital, 59, Green-street, Grosvenor-square.

1853-54 Black, Cornelius, M.B., Physician to the Chesterfield Dispensary, St. Mary's-gate, Chesterfield.

1849-50 Blagden, Robert, Esq., Surgeon to the St. George's and St. James's Dispensary, 16, Half-moon-street, Piccadilly.

1855-56 Borham, W. H., Esq., 19, Cambridge-terrace, Hyde-park.

1850-51 Bowman, William, Esq., F.R.S. (C.), Surgeon to King's College and to the Royal London Ophthalmic Hospitals, 5, Clifford-street.

Orig. Memb. Bright, Richard, M.D., F.R.S. (late V.P.), Physician Extraordinary to the Queen, 11, Savile-row.

*1846-47 Brinton, William, M.D., Senior Physician to the Royal Free Hospital, 20, Brook-street.

†1850-51 Bristowe, J. S., M.D. (C.), Assistant Physician to, and Demonstrator of Morbid Anatomy at, St. Thomas's Hospital, 3, St. Thomas's-street, Borough.

1851-52 Brodhurst, Bernard, Esq., Assistant Surgeon to the Royal Orthopædic Hospital, 14, Brook-street.

*1846-47 Brooke, Charles, M.B., F.R.S., Surgeon to Westminster Hospital, 29, Keppell-street, Russell-square.

Orig. Memb. Browne, Joseph Hullett, M.D., 37, Euston-square.

1854-55 Browne, Robert Cave, M.D., Tamworth.

1855-56 Bryant, T., Esq., Montague-place, Clapham-road.

1854-55 Buchanan, George, M.D., Resident Medical Officer, London Fever Hospital.

1850-51 Bullock, Henry, Esq., Hounslow, Middlesex.

1852-53 Burton, John M., Esq., Lee-park, Blackheath.

Orig. Memb. Busk, George, Esq., F.R.S., Surgeon to the Hospital-ship "Dreadnought," 15, Harley-street, Cavendish-square.

Orig. Memb. Camps, William, M.D. (C.), 40, Park-street, Grosvenor-square.

*1849-50 Canton, Edwin, Esq., Surgeon to the Charing Cross Hospital, 4, Montague-street, Russell-square.

1854-55 Carpenter, Alfred, Esq., High-street, Croydon.

1848-49 Carpenter, William Guest, Esq., Surgeon to the City of London Dispensary, 1, West-street, Finsbury-circus.

1855-56 Carter, H. V., Esq.

1848-49 Chalk, William Oliver, Esq. (C.), 3, Nottingham-terrace, Regent's-park.

Orig. Memb. Chevers, Norman, M.D., H.E.I.C.S.

1851-52 Childs, George Borlase, Esq., Surgeon to the Metropolitan Free Hospital, and to the City Police Force, 11, Finsbury-place, South.

1854-55 Cholmeley, William, M.D., Physician to the West London Dispensary, 6, Upper Southwick-street.

Elected Session

1851-52 Chowne, William D., M.D., Physician to the Charing Cross Hospital, 8, Connaught-place West, Hyde-park.

1853-54 Clarke, Andrew, M.D., Assistant Physician to the London Hospital, 23, Montague-place, Russell-square.

1855-56 Clarke, J. F., Esq., Senior Surgeon to the Dorcas Charity, 23, Dean-street, Soho.

1849-50 Clarke, John, Esq., L.R.C.P., Physician Accoucheur to the St. George's and St. James's Dispensary, 3, Clifford-street.

1854-55 Clover, J. Thomas, Esq., 44, Mortimer-street.

**Orig. Memb.* Cock, Edward, Esq. (V.P.), Surgeon to Guy's Hospital, 12, St. Thomas's-street, Borough.

1855-56 Cockle, J., M.D., M.A., 63, Brook-street, Hanover-square.

Orig. Memb. Cohen, Daniel Whittaker, M.D., Headley-grove House, near Dorking.

1853-54 Complin, Edward John, Esq., "Dreadnought," Hospital-ship.

1849-50 Cooper, George F., M.D., Surgeon to the Brentford Dispensary, Brentford.

1850-51 Cooper, William White, Esq., Surgeon Oculist to St. Mary's Hospital, and Surgeon to the North London Eye Infirmary, 19, Berkeley-square.

Orig. Memb. Copland, James, M.D., F.R.S. (V.P., late Treasurer), 5, Old Burlington-street.

1853-54 Cornish, William Robert, Esq., H.E.I.C.S.

**Orig. Memb.* Coulson, William, Esq., Surgeon to St. Mary's and the Magdalen Hospitals, 2, Frederick's-place, Old Jewry.

1852-53 Cousins, Edward, Esq., Surgeon to North Pancras Provident Dispensary, 49, Camden-road-villas.

**Orig. Memb.* Crisp, Edwards, M.D., 21, Parliament-street.

1848-49 Critchett, George, Esq. (formerly Honorary Secretary), Assistant Surgeon to the London, and Surgeon to the Royal London Ophthalmic Hospital, 46, Finsbury-square.

1855-56 Croft, John, Esq., Seaman's Hospital-ship, "Dreadnought."

1853-54 Cross, Robert, M.D., Physician to the Brewer's-court Dispensary, 20, New-street, Spring-gardens.

1854-55 Curgenven, J. Brendon, Esq., Grove-lane, Highgate.

1854-55 Curling, T. Blizard, Esq., F.R.S., Surgeon to the London and to the Jew's Hospitals, 39, Grosvenor-street.

1850-51 Dampier, Nathaniel John, Esq.

1854-55 Daubeney, Henry, M.D., 34A, York-street, Portman-square.

*1846-47 Davis, John Hall, M.D., Physician to the Royal Maternity Charity, and to the St. George's and St. James's Dispensary, 11, Harley-street, Cavendish-square.

**Orig. Memb.* Davies, Herbert, M.D., Physician to the Infirmary for Asthma, &c., and to the London Hospital, 23, Finsbury-square.

Elected Session

Orig. Memb. Day, George E., M.D., Professor of Anatomy and Medicine in the University of St. Andrews.

1851-52 Devenish, Samuel Weston, M.B., 7, Billiter-square.

1855-56 Dick, H., M.D., Brook-street.

Orig. Memb. Dixon, James, Esq. (C.), Surgeon to the Royal London Ophthalmic Hospital, 45, Green-street, Park-lane.

1855-56 Druitt, R., M.D., Officer of Health, St. George's, Hanover-square, 39A, Curzon-street, May-fair.

1851-52 Drury, James Samuel, M.D., 44, Albion-street, Hyde-park.

1846-47 Dudgeon, Robert E., M.D., 82, Gloucester-place, Portman-square.

1851-52 Duff, George, M.D.

1848-49 Eden, Thomas E., Esq., Surgeon Dentist to the Farringdon General Dispensary, 45, Threadneedle-street.

1853-54 Edwards, Alexander M'Kenzie, Esq., 9, Gloucester-crescent, Hyde-park.

1854-55 Edwards, George, M.D., Assistant Physician to the City of London Hospital for Diseases of the Chest, Finsbury Circus.

1854-55 Elin, George, Esq., Hertford.

1846-47 Ellis, Joseph, Esq., Sudbrook-park, Richmond, Surrey.

1851-52 Ely, George Ebenezer, M.D., Rochester.

*1846-47 Erichsen, John E., Esq., Surgeon to the University College Hospital, 48, Welbeck-street, Cavendish-square.

1853-54 Evans, Conway, Esq., M.B., Assistant Physician to King's College Hospital, 8, Lancaster-place, Strand.

*1847-48 Fergusson, William, Esq., F.R.S. (V.P.), Surgeon to King's College Hospital, 16, George-street, Hanover-square.

1851-52 Field, Octavius A., Esq., 4, Stanhope-terrace, Hyde-park.

*1846-47 Fincham, George T., M.D., Physician to the Westminster Hospital, 28, Chapel-street, Belgrave-square.

1853-54 Fisher, W. Webster, M.D., Downing Professor of Medicine, Cambridge.

1855-56 Flower, W. H., Esq., Surgeon to the Marylebone General Dispensary, 4, Mortimer-street, Cavendish-square.

1851-52 Forbes, J. Gregory, Esq., Surgeon to the Western General Dispensary, 14, Devonport-street, Hyde-park.

1849-50 Foreman, Robert Clifton, M.D., Resident Physician in the Establishment for Imbecile Children, Colville-house, Lowestoft.

Orig. Memb. Forster, John Cooper, Surgeon to the Royal Infirmary for Children, 11, Wellington-street, Southwark.

1853-54 Freeman, William Henry, Esq., 21, Spring-gardens.

Orig. Memb. Frere, J. C., Esq., Trinity College, Cambridge.

*1846-47 Fuller, Henry W., M.D., Assistant Physician to St. George's Hospital, 13, Manchester-square.

Elected Session

1854-55 Gamgee, Joseph Samson, Esq., Assistant Surgeon to the Royal Free Hospital, Woburn-place.

1855-56 Gamgee, J., Esq., Woburn-place.

1850-51 Garrett, Mark Brown, Esq., 3, New Road, St. George's East.

*1846-47 Garrod, Alfred Baring, M.D., Physician to University College Hospital, 63, Harley Street, Cavendish-square.

1855-56 Gaskoin, George, Esq., 3, Westbourne-park, Paddington.

**Orig. Memb.* Gay, John, Esq., 10, Finsbury-place, South.

1855-56 Gerber, Philip, M.D., 40, Mortimer-street, Cavendish-square.

1854-55 Gibb, George Duncan, M.D., F.G.S., Physician to the West London Dispensary, 59, Guildford-street.

1853-54 Gibbon, Septimus, M.D., Assistant Physician to the London Hospital, 33, Finsbury-square.

1854-55 Goodfellow, Stephen Jennings, M.D., Assistant Physician to Middlesex Hospital, 4, Russell-square.

1848-49 Gray, Henry, Esq., F.R.S., (C.), Surgeon to St. George's and St. James's Dispensary, 8, Wilton-street.

1846-47 Gream, George T., M.D., 2, Upper Brook-street.

1854-55 Greenhill, William Alexander, M.D., Physician to Hastings' Infirmary, Carlisle-parade, Hastings.

1849-50 Habershon, Samuel O., M.D., (C.), Assistant Physician to Guy's Hospital, 48, Finsbury-circus.

1851-52 Hacon, E. Dennis, Esq., Mare-street, Hackney.

1851-52 Hale, Robert J., M.D., 87, Gloucester-place, Portman-square.

†1851-52 Halley, Alexander, M.D., Physician to the Blenheim-street Dispensary, 7, Harley-street, Cavendish-square.

1851-52 Hansard, Richard, Esq., Surgeon to the Radcliffe Infirmary, Oxford.

*1847-48 Hare, Charles John, M.D., Assistant Physician to University College Hospital, 41, Brook-street.

1855-56 Harley, George, M.D., 4, Mortimer-street, Cavendish-square.

**Orig. Memb.* Hawkins, Cæsar H., Esq., F.R.S. (late President), Surgeon to St. George's Hospital, 26, Grosvenor-street.

1851-52 Hawkins, Charles, Esq., 22, Saville-row.

1848-49 Henry, Mitchell, Esq. (Honorary Secretary), Assistant Surgeon to the Middlesex Hospital, and Surgeon to the North London Eye Infirmary, 5, Harley-street.

**Orig. Memb.* Hewett, Prescott G., Esq. (V.P.), Assistant Surgeon to St. George's Hospital, 35, Hertford-street, May-fair.

1854-55 Hewitt, Graily, M.D., Physician to the Western General Dissary, and Assistant Physician to the Samaritan Free Hospital for Women and Children, 17, Radnor-place, Hyde-park.

1854-55 Hillier, Thomas, M.D., Officer of Health, St. Pancras, Gower-street, Bedford-square.

Elected Session

Orig. Memb. Hillman, William Augustus, Esq. (C.), Assistant Surgeon to the Westminster Hospital, 1, Argyll-street, Regent-street.

**Orig. Memb.* Hilton, John, Esq., F.R.S., Surgeon to Guy's Hospital, 10, New Broad-street.

1855-56 Hinton, J., Esq., 27, Charterhouse-square.

1852-53 Hogg, Jabez, Esq., Assistant Surgeon to the Westminster Opthalmic Hospital, 6, Gower-street.

1846-47 Holman, H. Martin, M.D., Hurstpierpoint, Sussex.

1854-55 Holmes, Timothy, Esq., Surgeon to the North London Ophthalmic Hospital, Vigo-street.

*1849-50 Holt, Barnard, Esq., Surgeon to the Westminster Hospital, 5, Parliament-street.

**Orig. Memb.* Holthouse, Carsten, Esq., Assistant Surgeon to the Westminster Hospital, Story's-gate.

*1850-51 Hodgson, Joseph, Esq., F.R.S., 60, Westbourne-terrace.

1853-54 Hood, William Charles, M.D., Resident Physician, Bethlem Hospital.

1850-51 Hore, Henry A., Esq., House Surgeon, Bristol Infirmary.

1855-56 Hudson, John, M.D., 11, Cork-street.

1854-55 Hulke, John William, Esq., Assistant Surgeon to King's College Hospital.

1854-55 Hulme, Edward Charles, Esq., Surgeon to Blenheim-street Dispensary, 19, Gower-street.

1852-53 Humby, Edwin, Esq., 1, Windsor-terrace, Madia-hill.

1852-53 Hutchinson, Jonathan, Jun., Esq. (C.), Surgeon to the Metropolitan Free Hospital, 14, Finsbury-circus.

‡1853-54 Jardine, J. L., Esq., County Hospital, Winchester.

1846-47 Jay, Edward, Esq., 51, Park-street, Grosvenor-square.

**Orig. Memb.* Jeaffreson, Henry, M.D. (V.P.), Physician to St. Bartholomew's Hospital, and Consulting Physician to the City of London Hospital for Diseases of the Chest, 2, Finsbury-square.

**Orig. Memb.* Jenner, William, M.D., Physician to the Hospital for Sick Children, and to University College Hospital, 8, Harley-street.

1854-55 Johnson, Athol A. W., Surgeon to the Hospital for Sick Children, 37, Albemarle-street.

1854-55 Johnson, Edward, M.D., 211, Regent-street.

**Orig. Memb.* Johnson, George, M.D., Physician to King's College Hospital, and to the Bishop's Court Dispensary, 3, Woburn-square.

*1846-47 Johnson, Henry Charles, Esq., Surgeon to St. George's Hospital, 6, Saville-row.

*1846-47 Jones, Charles Handfield, M.D., F.R.S., Assistant Physician to St. Mary's Hospital, Albion-street, Hyde-park.

*†*Orig. Memb.* Jones, Henry Bence, M.D., F.R.S. (V.P.), Physician to St. George's Hospital, 30, Grosvenor-street.

Elected Session
1853-54 Jones, Sydney, Esq., St. Thomas's Hospital.

1846-47 Kent, Thomas J., Esq., 30, Queen Ann-street, Cavendish-square.
1852-53 Kershaw, W. Wayland, Esq., Kingston-on-Thames.
1854-55 Kirkes, William Senhouse, M.D., Assistant Physician to St. Bartholomew's Hospital, 2, Lower Seymour-street.
1854-55 Kirby, Edmund A., Esq., 3, Powis-place, Haverstock-hill.
1851-52 Kingdon, J. Abernethy, Esq., Surgeon to the City Dispensary, 2, New Bank-buildings.

1850-51 Langmore, J. Charles, M.B., Surgeon to the Paddington Dispensary, 20, Oxford-terrace.
*1849-50 Latham, Peter Mere, M.D. (late President), 36, Grosvenor-street.
1853-54 Lawrence, Henry John Hughes, Esq., Assistant Surgeon, Coldstream Guards.
1851-52 Lee, Henry, Esq., Surgeon to King's College and the Lock Hospitals, 13, Dover-street.
1852-53 Leggatt, Alfred, Esq., Surgeon to the Chelsea Dispensary, 13, William-street, Lowndes-square.
*1849-50 Liddell, Sir John, C.B., M.D., F.R.S., Director General of Naval Hospitals and Fleets.
*1848-49 Little, William John, M.D. (V.P.), Physician to the London Hospital, 34, Brook-street.
1849-50 Littler, John Watson, Esq., Edmonton.
**Orig. Memb.* Lloyd, Edward, M.D., Physician to the Royal General Dispensary, 4, Suffolk-place, Pall-mall.
1852-53 Lloyd, Eusebius A., Esq., Surgeon to St. Bartholomew's Hospital, 14, Bedford-row.
1851-52 Lonsdale, Edward, Esq., Surgeon to the Royal Orthopædic Hospital, 26, Montague-street, Russell-square.

1855-56 Macann, A., Esq., 22, King-street, Portman-square.
1851-52 Mackenzie, Frederick William, M.D., Physician to the Paddington Dispensary for the Diseases of Women, &c., 11, Chester-place, Hyde-park-square.
1853-54 Macmurdo, Gilbert, Esq., F.R.S., Surgeon to St. Thomas's Hospital, New Broad-street.
1851-52 M'Shane, Charles, Esq., Surgeon, R.N.
1851-52 Markham, William O., M.D., Assistant Physician to St. Mary's Hospital, 33, Clarges-street.
1846-47 Marshall, John, Esq., Assistant Surgeon to University College Hospital, 10, Savile-row.
1852-53 Martyn, S., M.D., Physician to the Bristol General Hospital, 44, St. Michael's Hill, Bristol.
1851-52 May, George, M.B., Reading.

Elected Session

1854-55 Mills, Charles, Esq., 13, Conduit-street West, Hyde-park.

1846-47 Morgan, John, Esq. (C.), 5, Albion-place, Hyde-park-square.

1852-53 Moseley, George, Esq., Surgeon to the Dispensary, Sandgate.

1854-55 Murchison, Charles, M.D., Physician to Westminster General Dispensary, 21, Upper Seymour-street.

1855-56 Nasmyth, Robert, M.D., 49, Brook-street.

1850-51 Obré, Henry, Esq. (C.), 1, Melcombe-place, Dorset-square.

1852-53 O'Connor, William, M.D., Physician to the Royal Free Hospital, 30, Upper Montagu-street, Montagu-square.

1852-53 Ogle, James Adely, M.D., Regius Professor of Medicine, Oxford.

1850-51 Ogle, John W., M.B. (C.), Physician to St. George's and St. James's Dispensary, and Pathological Curator to St. George's Hospital Museum, 13, Upper Brook-street.

1853-54 Ogle, William, L.R.C.P., Physician to the Royal Pimlico Dispensary, Chester-terrace, Eaton-square.

‡1855-56 Oldfield, Edmund, Esq., Ashill, Watton, Norfolk.

1854-55 Panton, P., M.D., 20, Gloucester-terrace.

1853-54 Parkinson, George, Esq., Clarendon-lodge, Maida-hill.

1853-54 Part, James, Esq., 7, Camden-road-villas, Camden-town.

**Orig. Memb.* Partridge, Richard, Esq., F.R.S. (late V.P.), Surgeon to King's College Hospital, 17, New-street, Spring-gardens.

**Orig. Memb.* Peacock, Thomas Bevill, M.D. (V.P., late Honorary Secretary), Assistant Physician to St. Thomas's Hospital, and Physician to the City of London Hospital for Diseases of the Chest, 20, Finsbury-circus.

**Orig. Memb.* Poland, Alfred, Esq., Assistant Surgeon to Guy's, and Surgeon to the Royal London Ophthalmic Hospitals, 4, St. Thomas's-street, Borough.

1846-47 Pollock, George, Esq. (C., late Honorary Secretary), Assistant Surgeon to St. George's Hospital, 27, Grosvenor-street.

1850-51 Pollock, James Edward, M.D., Assistant Physician to the Hospital for Consumption and Diseases of the Chest, Brompton, 4, Chandos-street, Cavendish-square.

1854-55 Potts, William, Esq., 12, North Audley-street.

†1848-49 Purnell, John James, Esq., 4, Melbourn-place, Acre-lane, Brixton.

1850-51 Pyle, John, Esq., Surgeon to the North London Eye Infirmary, 56, Oxford-terrace, Hyde-park-square.

**Orig. Memb.* Quain, Richard, M.D. (Honorary Secretary), Physician to the Hospital for Consumption and Diseases of the Chest, at Brompton, 23, Harley-street, Cavendish-square.

1855-56 Rae, J., Esq., Surgeon, R.N., Greenwich Hospital.

Elected Session

Orig. Memb. Ramsbotham, Francis H., M.D. (late V.P.), Physician Accoucher to the London Hospital, 7, Portman-square.

1847-48 Randall, John, M.D., 14, Portman-street, Portman-square.

1846-47 Ray, Edward, Esq., Dulwich.

1852-53 Rees, George Augustus, M.D., Medical Officer, General Dispensary for Children, 45, Finsbury-square.

1854-55 Reynolds, J. Russell, M.D., Assistant Physician to the Hospital for Sick Children, 38, Grosvenor-street.

Orig. Memb Ridge, Joseph, M.D., 39, Dorset-square.

1852-53 Richardson, Benjamin Ward, M.D., Physician to the Infirmary for Asthma, &c., 12, Hinde-street, Manchester-square.

Orig. Memb. Roe, Hamilton George, M.D., Physician to the Westminster Hospital, and to the Hospital for Consumption and Diseases of the Chest, at Brompton, 26, Upper Brook-street.

1855-56 Roberts, John Henry, Esq., 10, Finchley-road.

1851-52 Rook, H. T., M.D., Assistant Surgeon to the Hospital-ship, "Dreadnought."

1852-53 Salter, Henry Hyde, M.D., F.R.S., Assistant Physician to Charing-cross Hospital, 6, Montague-street, Russell-square.

1853-54 Salter, Samuel James A., M.B., F.L.S., 17, New Broad-street.

1852-53 Sanderson, Hugh James, Esq., Surgeon to Hospital for Women, 26, Upper Berkeley-street.

1854-55 Sanderson, John S. B., M.D., Physician to the Western General Dispensary, 36, Newnham-square.

*1846-47 Sankey, W. H. O., M.B., Hanwell Lunatic Asylum.

Orig. Memb. Scott, John, M.D., 13, Stratton-street.

1853-54 Scott, John, Esq., Surgeon to the Hospital for Women, Soho-square, 53, High-street, Camden-town.

1846-47 Seaton, Edward C., Surgeon to the Chelsea, Brompton, &c., Dispensary, 33, Sloane-street, Knightsbridge.

1852-53 Semple, Robert Hunter, M.D., Physician to the Northern Dispensary, 8, Torrington-square.

Orig. Memb. Shaw, Alexander, Esq. (Treasurer), Surgeon to the Middlesex Hospital, 25, Henrietta-street, Cavendish-square.

1855-56 Sibley, Septimus W., Esq., Medical Registrar to the Middlesex Hospital, 14, New Burlington-street.

1848-49 Sibson, Francis, M.D., F.R.S. (C.), Physician to St. Mary's Hospital, 40, Brook-street.

1847-48 Sieveking, Edward H., M.D. (C.), Assistant Physician to St. Mary's Hospital, 3, Bentinck-street, Manchester-square.

1850-51 Simmonds, James B., Esq., Professor, Royal Veterinary College.

Orig Memb. Simon, John, Esq., F.R.S. (V.P.), Surgeon to St. Thomas's Hospital, 1, Cumberland-street, Hyde-park.

Orig. Memb. Smith, Ebenezer Pye, Esq., 7, Billiter-square.

Elected Session

1854-55 Smith, Edward, M.D., Assistant Physician to the Hospital for Consumption and Diseases of the Chest, at Brompton, 63, Grosvenor-street.

1846-47 Smith, Protheroe, M.D., Physician to the Hospital for Women, 21, Park-street, Grosvenor-square.

1851-52 Smith, W. Tyler, M.D., Physician Accoucher to St. Mary's Hospital, 7, Upper Grosvenor-street.

1855-56 Smith, H. Spencer, Esq., Senior Assistant-Surgeon to St. Mary's Hospital, 48, Sussex-gardens, Hyde-park.

1850-51 Snow, John, M.D., 18, Sackville-street.

1854-55 Squire, William, Esq., 6, Orchard-street, Portman-square.

*1847-48 Solly, Samuel, Esq., F.R.S., Surgeon to St. Thomas's Hospital, 18, St. Helen's-place.

1850-51 Stanley, Edward, Esq., F.R.S. (V.P.), Surgeon to St. Bartholomew's Hospital, 23A, Brook-street.

1854-55 Stewart, William Edward, Esq., Surgeon to St. Marylebone Provident Dispensary, 8, Weymouth-street, Portland-place.

†1853-54 Streatfield, T. F., Esq., 1, Finsbury-square.

†1850-51 Sutherland, Alexander John, M.D., F.R.S., Physician to St. Luke's Hospital, Richmond-terrace, Whitehall.

Orig. Memb. Tamplin, R. W., Esq., Surgeon to the Royal Orthopædic Hospital, 33, Old Burlington-street.

‡1855-56 Tapp, W. Denning, Esq., Surgeon to the Dorset County Hospital, Dorchester.

1850-51 Tatum, Thomas, Esq., Surgeon to St. George's Hospital, 3, George-street, Hanover-square.

1851-52 Taylor, Robert, Esq., Surgeon to the Central London Eye Infirmary, 10, George-street, Hanover-square.

1848-49 Tebay, Thomas G., Esq., 1, Little Smith-street, Westminster.

1852-53 Thompson, Henry, Esq., Surgeon to the Marylebone Infirmary, and Assistant Surgeon to University College Hospital, 16, Wimpole-street.

1851-52 Thompson, Theophilus, M.D., F.R.S., Physician to the Hospital for Consumption and Diseases of the Chest, at Brompton, 3, Bedford-square.

1851-52 Todd, Robert Bentley, M.D., F.R.S., Physician to King's College Hospital, 26, Brook-street.

**Orig. Memb.* Toynbee, Joseph, Esq., F.R.S., Surgeon Aurist to St. Mary's Hospital, 18, Savile-row.

1851-52 Trotter, John William, Esq., Assistant Surgeon, Coldstream Guards.

1847-48 Tuke, T. Harrington, M.D., Manor-house, Chiswick.

1852-53 Tulloch, James S., M.D., 1, Pembridge-place, Bayswater.

Elected Session

1853-54 Van der Byl, Philip, M.D., Physician to the Northern Dispensary, 1, Oxford-square.

1854-55 Vasy, Charles, Esq., 5, New Bond-street.

1850-51 Wagstaff, W. R., M.D.

Orig. Memb. Waite, Charles D., M.D., Physician to the Western General Dispensary. 2, Old Burlington-street.

1851-52 Walker, J. Butterworth, Esq., 8, Hamilton-place, St. John's-wood.

Orig. Memb. Walton, Henry Haynes, Esq. (C.), Surgeon to the Central London Ophthalmic Hospital, and Assistant Surgeon to St Mary's Hospital, 69, Brook-street.

‡*Orig. Memb.* Ward, Joseph, Esq., Epsom, Surrey.

**Orig. Memb.* Ward, Nathaniel, Esq. (formerly Honorary Secretary), Assistant Surgeon to the London Hospital, 1, Broad-street-buildings.

*1846-47 Ward, T. Ogier, M.D., Surgeon to the Kensington Dispensary, 9, Leonard-place, Kensington.

**Orig. Memb.* Ware, James T., Esq., Surgeon to the Finsbury Dispensary, 51, Russell-square.

1855-56 Watson, Thomas, M.D., Consulting Physician to King's College Hospital, 16, Henrietta-street, Cavendish-square.

1854-55 Webb, Francis Cornelius, M.D., 39, Great Coram-street.

1851-52 Welch, Henry James, Esq., 1, Dalston-terrace.

1853-54 Wells, Thomas Spencer, Esq.

1850-51 West, Charles, M.D. (C.), Physician Accoucheur to St. Bartholomew's Hospital, and Physician to the Hospital for Sick Children, 96, Wimpole-street.

1854-55 Wilks, Samuel, M.D., Assistant Physician to, and Demonstrator of Morbid Anatomy at, Guy's Hospital, 17, St. Thomas's-street, Southwark.

**Orig. Memb.* Williams, C. J. B., M.D., F.R.S. (formerly President), Consulting Physician to the Hospital for Consumption and Diseases of the Chest, at Brompton, 49, Upper Brook-street.

1854-55 Wood, Barnes, M.D., Gloucester-terrace.

1850-51 Wood, John, Esq., Assistant Surgeon to King's College Hospital, 21, Newcastle street, Strand.

1854-55 Wood, William, M.D., Kensington-house, Kensington.

1853-54 Wordsworth, John C., Esq., Assistant Surgeon to the London Hospital, 41, Finsbury-square.

1852-53 Wright, Edward, Esq., Montague-place, Clapham-road.

LIST OF SPECIMENS

EXHIBITED AT THE MEETINGS OF THE SOCIETY DURING THE SESSION 1855–56.

DISEASES, ETC. OF THE NERVOUS SYSTEM.

1. Fibro-fatty Tumor of the Dura Mater.	Mr. Sibley.
2. Deposit of Bone on the Dura Mater.	Mr. Obre.
3. Melanotic Carcinomatous Deposit connected with the Dura Mater, the Lining of the Ventricles, and the Seventh and Ninth Pairs of Cranial Nerves.	Dr. J. W. Ogle.
4. Encysted Coagulum in the Arachnoid Cavity.	Mr. Flower.
5. Large Circumscribed Tumor from the Brain.	Mr. Hutchinson.
6. Large Cyst in the Left Corpus Striatum, in connexion with Atrophy and partial Paralysis of the Right Arm. Also partial Paralysis, without Atrophy, of the Right Leg.	Dr. J. W. Ogle.

7.	
Fibro-cellular Deposit occupying the Left Optic Thalamus.	Dr. J. W. Ogle.
8.	
Yellow Softening and Abscesses within the substance of the Middle Lobe of the Brain, coincident with disease of the Tympanic Cavity of the Temporal Bone.	Dr. J. W. Ogle.
9.	
Gangrenous Abscess of the Brain, induced by Disease of the Internal Ear.	Dr. Theophilus Thompson.
10.	
Tumor from the Brain.	Dr. Hillier.
Report on this Specimen.	Mr. Hutchinson.
11.	
Tumor of the Brain.	Mr. Part.
Report on this Specimen.	Dr. J. W. Ogle.
12.	
Tumor on the Pons Varolii.	Dr. Wilks.
13.	
Tumor of the Cerebellum.	Dr. J. S. Bristowe.
14.	
Large Cyst containing six ounces of fluid, pressing on the under surface of the Cerebellum, and occupying the Fourth Ventricle.	Dr. J. W. Ogle.
15.	
Chronic Inflammation and Ossification of the Membranes of the Spinal Cord.	Dr. Wilks.

16.

Tumor of the Spinal Cord. — Dr. Wilks.

17.

Carcinomatous Growth pressing upon the Cervical part of the Spinal Cord, and producing Paraplegia. — Dr. J. W. Ogle.

18.

Tumor connected with the Spinal Cord. — Dr. Risdon Bennett.

DISEASES, ETC. OF THE ORGANS OF RESPIRATION.

1.

Cancerous Ulceration of the Mamma, which perforated the walls of the Chest, so as to form a free opening into the Cavity of the Pleura. — Mr. Shaw.

2.

Malignant Disease in the Anterior Mediastinum and in other organs. — Dr. Barker.

3.

Intra-thoracic Cancer. — Dr. J. Risdon Bennett.

4.

Malformed Trachea and Œsophagus: Congenital Communication between them. — Dr. J. W. Ogle.

5.

Ulceration of the Larynx in reference to Local Applications. — Dr. Quain.

6.

Fibrinous Cast expectorated in a case of Hæmoptysis. — Dr. Peacock.

7.

Fibrinous Casts of the Bronchial Tubes.	Dr. Crisp.

8.

The Lungs of Four Children who died from Hooping-cough.	Dr. Graily Hewitt.

9.

Lobar Pneumonia of the whole of the Left Lung, and Disseminated Carnification, with Emphysema, of the Right Lung, in an Infant.	Dr. Gibb.

10.

Cephaloma of the Lungs.	Dr. Theophilus Thompson.

11.

Cancer (?) of the Lungs, with Irreducible Omental Hernia.	Dr. Brinton.

DISEASES, ETC. OF THE ORGANS OF CIRCULATION.

1.

Calcified Pericardium in a case of Cerebral Apoplexy, with a multitude of small Gall-stones in the Gall-bladder.	Dr. Quain.
Report on the Specimen of Calcification.	Dr. H. Salter, and Mr. J. Salter.

2.

Extensive Effusion into the Pericardium.	Dr. Barker.

3.

Two Cases of Malformation of the Heart.	Dr. Peacock.

4. Congenital Malformation of the Heart in a Youth.	Dr. Quain for Dr. Cubsham.
5. Disease of the Aortic Valves and the adjoining Texture of the Heart; Formation of a False Aneurism of the Heart, communicating with the Aorta, giving rise there to Fibrinous-like Vegetations, and probably communicating also with the Right Auricle and with the Surface of the Heart.	Dr. Quain.
6. Specimens of Diseased Heart.	Dr. Peacock.
7. Disease of the Mitral and Aortic Valves.	Dr. Semple.
8. Diseased Aortic Valves.	Dr. Peacock.
9. Hypertrophy of the Heart, with Diseased Valves.	Dr. Semple.
10. Specimen of Enlarged Heart, with the thickening of the Mitral and Tricuspid Valves.	Dr. Pollock, for Dr. Hamilton Roe.
11. Aneurism of the Heart.	Dr. Quain, for Mr. Rae.
12. Case of Diseased Heart.	Dr. Barker.

13. Aneurismal Dilatations of the Coronary Arteries of the Heart and their Branches.	Dr Bristowe.
14. Aneurism of the Aorta compressing the Pulmonary Artery and causing Death by Angina Pectoris.	Mr. Hutchinson.
15. Rupture of an Aneurismal Pouch of the Root of the Aorta. Death by Gradual Hæmorrhage into the Pericardium.	Dr. J. W. Ogle.
16. Aneurism of the Ascending Aorta, bulging into the Right Ventricle of the Heart, and considerably obstructing the Orifice of the Pulmonary Artery, associated with an Aneurismal Pouch of the Septum of the Ventricle.	Dr. J. W. Ogle.
17. Case of Dissecting Aneurism of the Aorta.	Dr. Latham for Dr. Swaine.
18. Blocking up of both Internal Carotid Arteries by Coagulum, and consequent Death.	Dr. Peacock and Dr. Bristowe.
19. Obstruction of the Middle Cerebral Artery by a Fibrinous Plug, in connexion with Vegetations on the Aortic Valves.	Dr. Van der Byl.

Report on this Specimen.	Dr. Harr.
20.	
Case of Aneurism of the Basilar Artery, associated with total Deafness.	Dr. Van der Byl.
21.	
Aneurism of the Middle Cerebral Artery.	Mr. Squire.
22.	
Aneurism of the Middle Cerebral Artery: Extravasation of Blood from bursting thereof: Death in a few hours.	Dr. J. W. Ogle.
23.	
Aneurism of the Posterior Cerebral Artery, forming a Laminated Tumor within the Brain.	Dr. Van der Byl.
24.	
Contusion of the Abdomen, causing Laceration of the Vena Cava; with Rupture, Inversion, and Invagination, in a Tubular Form, of portion of the Inner and Middle Coats of the Aorta.	Mr. Shaw.
25.	
Specimen of Calcareous Deposit of unusual size, containing true Bone-structure, in an Iliac Vein.	Dr. J. W. Ogle.
26.	
Softening Clots in the Heart, in a case of associated Renal Disease,—Hypertrophy of the Heart,—Pulmonary and Cerebral Apoplexy.	Dr. Bristowe.

27.

Fibrinous Deposits in the Substance of the Heart.	Dr. Bence Jones.
Examination of the Deposit.	Mr. Gray.

28.

Fibrinous Deposits in the Spleen, Kidneys, &c. from a Case of Carditis, with Softening of the Brain.	Dr. Van der Byl.
Report on the preceding Case.	Mr. Erichsen.

29.

Fibrinous Coagulum, obstructing the Left Common Iliac Artery, and causing Gangrene of the Leg.	Mr. W. H. Flower.

30.

Large quantity of Fibrinous Deposit within the substance of the Kidney, the Supra-renal Capsule, the Renal and Supra-renal Veins, perfectly converted into Fat. Total Obliteration of the Inferior Vena Cava of old standing.	Dr. J. W. Ogle.

DISEASES, ETC. OF THE ORGANS OF DIGESTION.

1.

Specimens of Imperfectly Calcified Dentine.	Mr. James Salter.

2.

Specimen of Dentine of Repair.	Mr. James Salter.

3.

Papilloma, or Warty Growth on the Palate.	Mr. Hilton and Dr. Wilks.

4. Malignant Disease of the Cardiac End of the Œsophagus.	Dr. Quain.
5. Stomach in a Case of Poisoning by Essential Oil of Almonds.	Dr. Quain.
6. Perforating Ulcer of the Stomach.	Dr. Quain for Dr. Black.
7. Intussusception of the Cæcum and part of the Ileum into the Colon in an Adult; Death after four months' symptoms.	Mr. Hutchinson.
8. Internal Strangulation of Small Intestine.	Mr. Obre.
9. Case of Ileus produced by Invagination of a portion of Bowel, which was subsequently discharged by stool. Recovery.	Dr. Quain for Dr. Black.
10. Fatal Intestinal Obstruction in consequence of a Twist in the Mesentery, and the falling of some folds of Intestine over a true Diverticulum.	Mr. Nathaniel Ward.
11. Stricture of the Sigmoid Flexure of the Colon, with Perforating Ulcer, fatal five weeks after Labour.	Dr. Gibb for Dr. H. G. Wright.

12.

Perforation of Cæcal Appendix from an Intestinal Concretion.	Dr. Wilks.

13.

Tuphlo-enteritis from Hardened Fæces in the Appendix Vermiformis.	Dr. Ogier Ward.

14.

Villous Disease of the Colon.	Mr. Sibley.

15.

Unique Congenital Malformation, associated with Umbilical Hernia and a Pendulous Artificial Anus.	Dr. Gibb.

16.

Specimen of Strangulated Femoral Hernia.	Mr. H. Obre.

17.

Omental Crural Hernia, spontaneously cured by Adhesion of the Omentum around the Neck of the Sac. From a Female.	Mr. John Wood.

18.

A Case of Triple Umbilical Hernia, containing various portions of the Abdominal Viscera.	Dr. Quain for Mr. W. H. Borham.

19.

A Specimen of Strangulation and Ulceration of the Small Intestine.	Mr. Nathaniel Ward.

20.

A Case of Hydatids of the Liver, attended with Hæmorrhage into the Stomach and Bowels, proceeding along the Bile-Ducts from one of the Hydatid Cysts.	Dr. Hillier.

21.

Hydatids in the Liver.	Dr. Barker.

22.

Cirrhosis of the Liver, accompanied with profuse Hæmorrhage into the Stomach and Intestines.	Dr. Hillier.

23.

Cystic Disease of the Liver, associated with similar Disease of the Kidneys.	Dr. Bristowe.
Report on this Specimen.	Dr. Lionel Beale.

24.

Cystic Disease of the Liver and Kidney.	Dr. Wilks.

25.

Hypertrophied Spleen. Leuchœmia. Cirrhosis of Liver. Deposit of Carbonate of Lime on Lining Membrane of Gall Bladder.	Dr. Murchison.

DISEASES, ETC. OF THE URINARY AND GENERATIVE ORGANS.

1.

Cystic Disease of the Testis occurring in an Infant, and probably Congenital.	Mr. Athol A. Johnson.

2. Thick Walled Cyst in the Tunica Albuginea Testis.	Mr. Hutchinson.
3. Stricture of the Urethra. Great Hypertrophy and Sacculation of Bladder in a man æt. 42.	Mr. Henry Thompson.
4. Polypoid Growth from the Verumontanum.	Mr. Henry Thompson.
5. Tumor of the Prostate Gland.	Mr. Henry Gray.
6. Enlargement of the Prostate due to Fibrous Tumors. Diseased and Sacculated Bladder.	Mr. Henry Thompson.
7. Intra-Glandular Tumor of the Prostate.	Mr. Henry Thompson.
8. Villous Disease of the Bladder.	Mr. Sibley.
9. Calculus in the Female Bladder impeding Parturition, removed by operation.	Mr. Erichsen.
10. Calculous Matter removed from a Boy, æt. 10, by the Operation of Lithotrity.	Mr. Blizard Curling.
11. A Lithic Acid Calculus, which was removed by Dilatation from the Bladder of a Lady, æt. about 40.	Dr. Crisp.

12. Abnormal Ureters from a Girl, æt. 10.	Mr. John Wood.
13. Stricture of the Ureter, with Extensive Absorption and Dilatation of the Kidney.	Mr. Henry Gray.
14. Impacted Calculus with Sacculated Kidney.	Dr. Peacock.
15. Specimen of a Single Kidney found in the body, of a horse-shoe shape.	Dr. B. Jones.
16. Atrophied Kidneys.	Mr. Obre.
Report on these Specimens.	Dr. Bristowe and Mr. Gray.
17. Large Cancerous Growth of the Kidney in a Child.	Dr. Van der Byl.
18. Diseased Supra-renal Bodies.	Mr. Hutchinson for Mr. Bakewell.
Report on this Specimen.	Dr. Wilks.
19. Procidentia Uteri of Large Size.	Mr. Potts.
20. Congenital Absence of the Uterus and its Appendages.	Dr. Quain for Dr. Ormerod.
21. Ovarian Tumor weighing one hundred and six pounds. Great Elongation of the Cervix Uteri and Vagina.	Dr. Gibb.
Report on this Specimen.	Dr. Hare.

22.

Multilocular Ovarian Tumor, with Intra-Cystic Growths covered with Ciliated Epithelium.	Dr. Wilks.

DISEASES, ETC. OF THE OSSEOUS SYSTEM.

1.

Fracture of the Occipital Bone, with Bony Union.	Mr. Henry Gray.

2.

Necrosis of the Condyle, the Angle, and part of the Horizontal Ramus of the Lower Jaw, after Typhus Fever.	Mr. John Birkett.

3.

Necrosis of the Symphysis and portions of the Horizontal Rami of the Lower Jaw, consequent upon Cancrum Oris. Reparation of the loss thus sustained by the Development of New Bone.	Mr. John Birkett.

4.

Case of Ankylosis at the Upper End of the Spinal Column.	Mr. John Wood.
Report on this Specimen.	Mr. Shaw and Mr. Gray.

5.

Specimen of Scrofulous Necrosis and Caries of the two Last Dorsal and Two Upper Lumbar Vertebræ, without Psoas Abscess, but with Abscess passing backwards and upwards, and opening externally opposite the Spinous Processes of the last Cervical, and First Dorsal Vertebræ.	Mr. W. Adams.

6. A Specimen of Pelvis Oblique Ovata from a Female Subject.	Mr. John Wood.
7. Impacted Fracture of the Cervix Femoris ununited by Bone. Longitudinal Fracture through the great Trochanter and Upper part of the Shaft, with Bony union.	Mr. John Wood.
8. Section of an Impacted Fracture of the Neck of the Thigh-bone, from a subject diseased with Mollities Ossium.	Mr. John Wood.
9. Excision of the Head of the Femur, for Disease of the Hip-joint.	Mr. Shaw.
10. Compound Fracture of the Thigh, with Laceration of the Main Vessels, produced by a Ramrod discharged from a Cannon.	Mr. Prescott Hewett.
11. Necrosis symmetrically affecting both Condyles of the Femur, and communicating with the Knee-joint.	Mr. W. Adams.
12. Deposit of Crystalline Urate of Soda in the Cavity of the Knee-joints.	Dr. Bence Jones.

13.	
Ankylosis of the Knee-joint in an aged Male subject.	Mr. John Wood.
14.	
Softened Ankylosis of the Knee-joint.	Mr. Bryant.
15.	
The Parts involved in an Excision of the Knee-joint, showing Abscesses in the Head of the Tibia.	Mr. Hutchinson.
16.	
A Cast showing a Rupture of the Ligamentum Patellæ subsequent to Fracture of the Patella.	Mr. W. H. Flower.
17.	
Crude Tubercle in the Tibia.	Mr. Erichsen.
Report on this Specimen.	Mr. Gray.
18.	
Cysto-myeloid Tumor of the Upper Head of the Tibia.	Mr. Shaw, with Mr. Sibley and Mr. Flower.
Report on this Specimen.	Mr. Henry Gray and Mr. Hutchinson.
19.	
Parts removed in an Excision of the Elbow-joint.	Mr. Hutchinson.
20.	
Pendulous Ossific Growths in the Elbow-joint.	Mr. John Wood.

DISEASES, ETC. OF THE ORGANS OF SPECIAL SENSE.

1. Large Malignant Tumor growing from the Orbit.	Mr. Hutchinson for Mr. G. B. Childs.
Report on this Specimen.	Dr. Bristowe.
2. On the Cortical and Nuclear Cataracts of Adults.	Mr. Robert Taylor.
3. Atrophy of the Optic Nerves and Tracts of both sides and of the Optic Commissure. Total Blindness for Twelve or Fourteen Years.	Dr. J. W. Ogle.
4. Extraction from the Left Ear of a Boy, of greater part of the Petrosal Portion of the Temporal Bone, including the Meatus Auditorius Internus and Labyrinth, separated by Necrosis.	Mr. Shaw.

MISCELLANEOUS SPECIMENS, TUMORS, ENTOZOA, ETC.

1. Recurrent Tumor of Orbit, followed by similar Growths on the other side of the Head, on the Dura Mater, and under the Costal Pleura.	Dr. T. Hillier.
2. Example of Multiple Fibrous Tumors.	Mr. Sibley.

3.	
Tumor in connexion with the Scapula.	Mr. Sidney Jones.
Report on this Specimen.	Dr. Bristowe and Mr. Sydney Jones.
4.	
Myeloid Tumor of the Humerus.	Dr. Bristowe.
5.	
Specimen of Myeloid Tumor of the Head of the Tibia.	Mr. Charles Hawkins.
6.	
Large Malignant Tumor of the Thigh, for which Amputation was performed at the Hip-joint.	Mr. Blizard Curling.
7.	
Fibro-cystic Tumor involving the Condyles and Lower part of the Femur.	Mr. Borlase Childs.
Report on this Specimen.	Dr. Bristowe.
8.	
Report on a Specimen of Osteo-sarcoma, presented to the Society by Mr. Fergusson.	Dr. Ogle and Mr. James Salter.
9.	
Pulsating Erectile Tumor in the Cheek.	Mr. Hutchinson.
10.	
Mammary Glandular Tumor.	Mr. Henry Thompson.
11.	
Large Glandular Tumor from the Axilla, simulating the characters of Scirrhus.	Mr. Hutchinson.

12. Case of Cystic Growth developed in the Mammary Gland.	Mr. John Birkett.
13. Drawing of Warts which disappeared under the use of Magnesia.	Mr. Part.
14. Case of Extensive Dissecting Abscess of the Lower Extremity from Pyæmia.	Mr. Part.
15. Case of Carcinoma of the Bones of the Cranium, the Vertebræ, the Ribs, and most of the Internal Organs of the Body.	Dr. J. W. Ogle.
16. Portions of the Lumbar Glands, Liver, Lungs, and Heart of a Man who died five months after the removal of the Testicle for Malignant Disease.	Mr. Henry Thompson.
17. Specimens illustrating the seat of Cancer.	Dr. J. S. Bristowe.
18. Case of Talipes Equino Varus, with Disease of the Knee-joint.	Dr. Murchison.
19. Hairs and Crusts from a Case of Ringworm, showing Peculiarities in the Growth of the Characteristic Fungus.	Mr. Hutchinson.

20. The Vegetable Fungus of Common Ringworm, Tinea Tonsurans.	Mr. Henry Thompson.
21. Microscopic Specimens of the Vegetable Fungus found in two Cases of Pityriasis Versicolor.	Mr. Henry Thompson.
22. Extensive Scabs on the Mucous Membrane of the Colon, associated with Submucous Cysts containing Calcareous Particles in Herpes Phlyctenodes in the Horse.	Mr. John Gamgee.
23. Case of Melanic Cancer in the Horse.	Dr. Quain for Dr. Black.
24. Calculus from the Bladder of a Field Mouse.—Mus Sylvaticus.	Dr. Gibb.
25. Tubercles in the Lungs of a Pony.	Dr. Quain for Dr. Babington.

REPORT.

ERRATUM AND ADDENDUM.

Page 80, line 29, *for* "Arterisous" *read* "Arteriosus."

Dr. Theophilus Thompson desires to add after the words "twenty years," eight lines from bottom of p. 17, "but which during the preceding week had been suppressed." He also desires to say in reference to this case "that wet cotton had been used, with relief to his deafness, as a substitute for the membrana tympani."

REPORT.

SESSION 1855–56.

I.—DISEASES, ETC. OF THE NERVOUS SYSTEM.

1. *Fibro-fatty Tumor of the Dura Mater.*

A woman, æt. about 30, was admitted into the Middlesex Hospital on the 22nd of August, 1855, under the care of Dr. Hawkins. She had fallen down in the street whilst walking a few minutes before. She was nearly unconscious, but still made some attempts to answer questions; the pupils small and insensible; the respiration slightly stertorous; the pulse steady and infrequent. On the following day she remained in the same drowsy condition, but was able to protrude the tongue. After this she appeared to pass into a state of profound sleep, from which it was not possible to arouse her, and she became quite unable to swallow. The motions were passed beneath her; the urine retained. During the whole time no paralysis of the face or extremities could be detected. She died on the 30th of August, the ninth day after her seizure.

Very little could be ascertained of the previous history of the woman, as she was, of course, unable to give any account of herself; and she was not claimed by any relations or friends. The sister of the Accident Ward recognised her as having been in the Hospital six years before, when she was either knocked down or run over by a cart. She then appears to have suffered from concussion. Since that time she had been frequently seen in the neighbourhood; and, although a woman of loose habits, appeared to have enjoyed good health.

Post-mortem examination.—The body was well formed and well nourished. The skull of moderate thickness, healthy;

dura mater rather thicker than usual. On opening it anteriorly, about two ounces of turbid brownish-yellow fluid escaped, giving a sensation of grease to the fingers. In the fluid were several bodies of the consistence of cheese; and also some glistening soft white masses, the largest of which was about the size of a pea. The fluid escaped from a sort of cyst formed between the anterior and middle lobes on the left side, and was bounded by adhesions of the arachnoid. The anterior portion of the left middle lobe was firmly adherent to the dura mater. The dura mater itself, however, separated easily from the bones, leaving the adjacent portion of the sphenoid and temporal perfectly healthy.

The adherent portion of brain was occupied by a body rather larger than a hazel-nut, which appeared to be embedded in the substance of the brain, destroying the external portion. On section it presented a yellowish colour, and was of the consistence of soft cheese.

The dura mater was nearly one-third of an inch in thickness, and exhibited a white, somewhat glistening, tough section; but appeared to pass, by almost imperceptible gradations, into the yellow substance last described. In this thickened portion of dura mater there was a piece of bone of considerable size. The rest of the brain was tolerably firm, and was not more vascular than usual. There were about two drachms of clear serum in the ventricles. The choroid was of dark colour.

The lungs were bound to the chest by firm adhesions; they were both rather congested, and a portion of the left lower lobe was in a state of red hepatisation.

There was a good deal of fat on the heart externally. The amount of atheroma on the aorta was slight; liver firm, dark, rather greasy; spleen firm, large; kidneys both rather dark, but otherwise healthy.

Microscopical examination.—The white glistening bodies which floated in the fluid of the cyst, consisted entirely of adipose tissue (Plate I. Fig. 1.); the cells being all very transparent, considerably smaller than those of ordinary fat, mostly polyhedral, a few, however, being spheroidal. No nuclei were seen in them. Numerous plates of cholesterine were lying among the tissue, but external to the fat cells.

DESCRIPTION OF PLATE I.

Figures 1 to 5 illustrate the minute structure of Mr. Sibley's case of Fibro-Fatty Tumor of the Dura Mater, p. 1.

Fig. 1. Fatty tissue and cholesterine from the white glistening bodies found floating in the fluid of the cyst.

Fig. 2. Osseous portion of the dura mater.

Fig. 3. Large granular corpuscles from the cheese-like portion of brain.

These three figures are magnified about 150 diameters.

Fig. 4. Bundles of cylindrical fibrillæ from the thick portion of the dura mater. Magnified 300 diameters.

Fig. 5. Large granular cells from the turbid fluid of cyst. Magnified 150 diameters.

Figure 6 illustrates the microscopic structure of the Tumor from the Brain, described by Mr. Hutchinson, p. 7.

Magnified 400 diameters.

Fig 1.

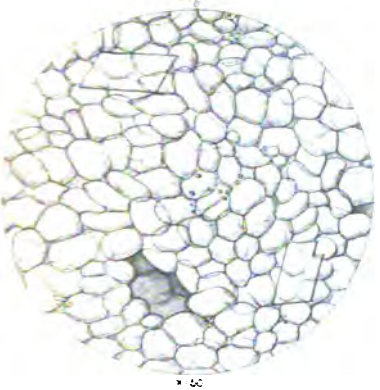

× 50

Fig. 2.

× 150

Fig 3.

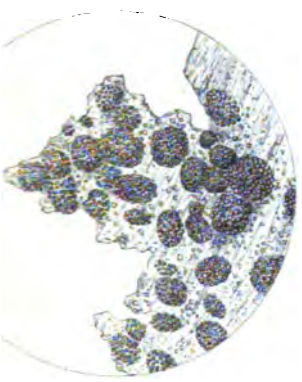

× 150

Fig 4

× 300

Fig 5

× 150

Fig 6

× 400

W. H. Flower & T. W. del. Tuffen West sc.

W. West

The turbid *fluid* from the cyst (Plate I. Fig. 5.) exhibited numerous large cells, all more or less granular; some completely filled with fatty granules. A few of them, however, were rendered quite transparent by acetic acid, and exhibited no nuclei. In size they varied from the diameter of a blood corpuscle to six or seven times that diameter. There was also a large quantity of granules, and a number of plates of cholesterine, floating in the fluid.

The cheese-like portion of the brain was composed of large compound granular corpuscles (Plate I. Fig. 3.) similar to those found in the cyst. Some of these were enveloped in a cell wall, whilst others appeared to be nothing more than an aggregation of granules of fat. These corpuscles seemed to be embedded in a broken down tissue, in which no trace of nerve cells or of nerve tubes could be detected.

Some granular corpuscles were found in the grey substance of the brain as far as two inches from the tumor, and in a portion of the brain which appeared to the naked eye to be perfectly healthy.

The *thick portion of the dura mater* was formed of cylindrical fibrillæ, which, for the most part, were arranged in bundles parallel to one another (Plate I. Fig. 4.). The bundles themselves, however, were interlaced. Some of the fibrillæ appeared to be fusiform. Acetic acid rendered the section transparent, but did not bring out any elastic fibres.

The *osseous portion* of the dura mater (Plate I. Fig. 2.) exhibited the usual structure of well formed true bone. In parts this bone was in a state of active development; in other parts it was undergoing absorption.

The appearances above described leave no doubt that there had been at one time a fatty tumor growing in the brain, or in its membranes; and that this tumor had excited inflammation, and had become broken down, destroying the brain tissue for some distance around. It is not, however, clear whether the fatty tumor was associated in the same growth with the fibrous thickening of the dura mater, or had been a separate tumor in the substance of the brain. The former hypothesis is by far the most probable, as fibrous and fatty tumors are not in-

frequently associated together. Wedl gives an example of cholesteatoma and cisto-sarcoma associated in the same tumor.

Although the fragments of fat tissue found in the cyst contained a large amount of cholesterine, they did not present any evidence of the laminated arrangement usually noticed in cholesteatoma, as described by Drs. Bristowe and Thurnam.* Whether the origin of the growth may in any way be traced to the injury received six years before, is perhaps rather a matter for speculation than for induction.

Mr. SIBLEY, *6th of November*, 1855.

---

2. *Deposit of Bone on the Dura Mater.*

A needlewoman æt. 67, five years a patient at the Somerset County Asylum, from an early age showed symptoms of enfeebled mind, and latterly suffered from delusions that persons entered her house and robbed her of her clothes. She was also impressed with exalted ideas of her consequence, and a delusion that she was married to a clergyman; she was occasionally noisy and abusive, but expressed herself clearly on religious subjects; she died from marasmus, refusing, in her last illness, food or medicine.

Post-mortem.—The body weighed fifty-three pounds; head small, only twenty inches in circumference. Cerebral veins congested with blood. Attached to the dura mater near the middle of the right cerebral hemisphere, and about an inch from the falx, was an irregularly shaped bone deposit, weighing seven grains; it was embedded in the brain between two convolutions. The cerebral structure was firm; the left cerebral hemisphere weighed half an ounce more than the right; the brain altogether weighed eight ounces and a half below the average, being thirty-three ounces and a half avoirdupois. The bone deposit was subjected to microscopical examination, and showed all the characters of true bone.

Mr. OBRE, *4th of March*, 1856.

* "Transactions of the Pathological Society," vol. v.

---

3. *Melanotic Carcinomatous Deposit connected with the Dura Mater, the Lining of the Ventricles, and the Seventh and Ninth Pairs of Cranial Nerves.*

The under surface of the dura mater, at about the middle of the skull, and very near to the superior longitudinal sinus, showed a greyish-brown deposit of about the size of a shilling, and about a quarter of an inch in thickness, intimately connected with it. This was the means of union between the dura mater and the convolutions of the brain, (which were, however, not affected themselves,) and was itself very vascular. A similar deposit, of the size of two peas, was situated in the right lateral ventricle, and intimately connected with the lining of the cavity, covering the lower part of the septum of the ventricles. Moreover, a quantity of black deposit was found amidst the nervous fibres composing the seventh and ninth pairs of cranial nerves on each side, passing with them into their respective auditory and jugular openings, but only to a slight extent. Much of this deposit, in connexion with the nerves, was capable of being entirely removed by maceration in water for a few hours, and was obviously only connected with the delicate connective tissue uniting the various nerve filaments. Deposits of various sizes, up to that of a filbert, and of various colours, from a lightish yellow to brown, and so on to absolute black, were found in the heart, the kidneys, the spleen, suprarenal capsules, omentum, pancreas, lining of the stomach and ileum, within the cavity of the orbit, occupying also most of the lymphatic glands of the body, and, in many places, under the superficial integuments of the chest and abdomen, appearing, in the latter places, as slight elevations of the skin. The lungs were free from the deposits, and the lymphatic glands of the axilla seemed to be the seat of the primary affection.

These various growths were of uniform consistence; but some, in particular places, as in the stomach and at the base of the heart, were flattened at their summits, and a little depressed, as if from pressure or friction. As regards the heart, both the pericardium and endocardium, and the substance of the walls, were the seat of deposit, though it was rare in

the latter part. Externally, it seemed chiefly to follow the course of the large blood-vessels and lymphatics.

Microscopical appearances.—The deposits, wherever examined, presented the same elements, excepting where, as in the enlarged lymphatic glands, original structural elements were superadded. On squeezing out the juice it was found to contain vast numbers of rounded oval cells, with one or two nuclei and granular matter within, of about twice the size of pus globules for the most part. In very few cases indeed were fusiform, or elongated, or caudate cells visible. The colouring of the deposit was evidently owing to numbers of the same cells as those above described, which also contained pigmentary matter; and the number of these was proportionate to the dark colour of the whole deposit. The tougher parts of the deposit contained much fibrous stroma, but no particular relation betwixt the cells and the stroma existed.

History.—The preparation was removed from the body of a man, æt. 28, who was brought into St. George's Hospital in February, with great protrusion of the eyeballs, especially of the left one, of which he was quite blind. At that time a distinct hardness was to be felt over this eyeball, and to the outside, connected with the roof of the orbit, apparently. He was always considered to have had a "full eye." The tumor in the region of the scapula, before spoken of, existed, and also the small hard moveable tumors beneath the skin, which he said he had had as long as he could remember. He complained greatly of pain in the head, to which he had been subject for three months, for which period also the eyeballs had been protruding, as the patient thought. The patient got gradually weaker, and became subject to epileptic fits. He died about ten weeks after admission.

Dr. J. W. Ogle, *20th of May*, 1856.

---

4. *Encysted Coagulum in the Arachnoid Cavity.*

The specimen was taken from a woman æt. 66; whose history, being a Dissecting-room subject, is unknown. On the cerebral surface of the dura mater is a thin layer of extrava-

sated blood, of a pale reddish, or fawn colour, not more than one-eighth of an inch thick at the middle, and becoming thinner at the edges; it is five inches long, and three broad, and corresponds to the upper and outer portion of the left cerebral hemisphere. The free, or cerebral surface of the clot, is paler in colour, and firmer than the rest, being easily separable as a fine delicate membrane, beneath which is a reddish jelly-like substance, but slightly adherent to the serous surface of the dura mater, and which consists, microscopically, of very fine fibrillæ and bodies, which are apparently altered and shrivelled blood corpuscles. The vessels of the pia mater were much congested; the cranium was healthy, and there was no appearance externally of previous violence. Mr. Flower remarked that this is a good example of an early stage of the formation of a cyst round blood extravasated into the arachnoid, the nature of which process has been fully elucidated by Mr. Prescott Hewitt (Med. Chir. Trans. vol. xxviii.), and appears to be a change in the blood itself, and not dependent on inflammatory action around it.*

Mr. Flower, 15*th of January*, 1856.

---

5. *Large Circumscribed Tumor from the Brain.*

This specimen was of much interest in connexion with one shown by Dr. Hillier at a recent meeting, which, in some particulars, it closely resembled. It had been obtained in the Dissecting-room of St. Bartholomew's from the brain of a well-nourished young woman, the cause of whose death was unknown. Mr. Hutchinson stated that he was indebted to the courtesy of his friend, Mr. Savory, for the opportunity of presenting it to the Society. It was about the size of a child's fist, and of rounded, smooth exterior, being enveloped in all parts by a thin cellular membrane. Before removal it lay embedded in a depression on the external surface of the right middle cerebral lobe. On lifting the brain it rolled out by its own weight, having attachments only to the dura mater. It appeared to be covered by pia mater, and, at first sight, much

* See also "Pathological Transactions," vol. vi. p. 8.

resembled an additional cerebral lobe. By its side was a similar mass, of about one-sixth its size, but resembling it closely. The section presented an opaque, dead-white surface, with here and there an appearance as of fibres. It was not so glistening, nor yet so homogeneous, as brain structure, nor did it, although easily broken down by pressure, yield any true juice. Under the microscope, it consisted mainly of elongated mononucleated cells (Plate I. Fig. 6.), cellular tissue, free nuclei, and, in very small numbers, cells containing more than one nucleus being also seen. The cells were much smaller in size than those found in Dr. Hillier's specimen, and their nuclei also were much less. The polynucleated cells were very few, and larger than those of the myeloid. These characters are better shown by the drawing (Plate I. Fig. 6.) than they could be by any more detailed description.

Mr. HUTCHINSON, *4th of March*, 1856.

---

6. *Large Cyst in the Left Corpus Striatum, in connexion with Atrophy and partial Paralysis of the Right Arm. Also partial Paralysis, without Atrophy, of the Right Leg.*

The specimen consisted of the base of the brain, showing the lateral ventricles laid freely open, which contained much clear fluid. The right lateral ventricle was in all respects natural; but the left one presented the following peculiarities :—

The outer, as well as the posterior part of the left corpus striatum was so destroyed that only about half of this ganglion remained, and that was much altered in form, being lobulated on its surface. A small portion of the outer wall of the ventricle was also involved; and to a very slight degree, likewise, a superficial portion of the contiguous optic thalamus. The parts destroyed were replaced by a deep cavity, of which the margins were, for the most part, gradually bevilled off from the surrounding surfaces; but in places very abrupt and rugged. The lining membrane of the ventricles, which was universally thickened, though in some parts more so than in others, and corrugated, was preserved over the cavity, but of course on a lower level than in surrounding parts, and assisted in smooth-

ing its margins. The cavity was traversed by delicate fibrous processes in one or two places, and contained a clearish pale fluid. Moreover, where the outer portion of the corpus striatum was wanting, the white nervous fibres which pass outwards and forwards beneath the ganglion (the so-called peduncular fibres of the brain), were plainly displayed, as if by artificial dissection, the only covering they possessed being the translucent thickened lining of the ventricles. The substance of the brain in other respects was natural. The dura mater was in many places very adherent to the calvarium, and the arachnoid covering the convolutions thickened. At the summits of the middle lobes of the cerebral hemispheres, the arachnoid membrane covering the convolutions was adherent to the dura mater. Moreover, lining the dura mater to some extent over the lateral hemispheres, existed a thin layer of false membrane, here and there blood-stained, but otherwise almost discoloured. The scalp and cranial bones were natural; and so were the thoracic organs. The urinary bladder was very thickened and inflamed, the prostate gland being greatly enlarged; and there was a false passage at the posterior part of the cavernous portion of the urethra, leading into a sloughing canal and abscess between the bladder and the rectum. The kidneys were granular.

Microscopical examination.—The fluid contained within the cyst, as examined by the microscope, was seen to contain a certain amount of granular albuminous material; and along with this a number of amyloid bodies, but nothing more. The false membrane in the arachnoid cavity, as described above, showed vast numbers of delicate *fibres*, with large distinct oat-shaped nuclei, after the addition of acetic acid; occasional very large round and oval bodies, with dark refracting contents; much granular matter; red blood corpuscles mixed with large numbers of white ones; and distinct *capillary vessels*, with regular nuclei in their walls. The muscular structure of the affected arm, to be hereafter described, was found to be natural as regards the biceps, but much altered as regards the muscles connected with the wrist. The transverse striæ existed in some places, but in others the fibres were granular, confused, and devoid of their striæ.

History and condition of patient.—The preparation was removed from the body of a man, æt. 62, who was said to have been partly paralysed on his right side ever since he was two years of age. He was not known ever to have had any convulsions or fits, but was, to a certain extent, affected in his mind; having the impression, owing to his having been joked, that he was himself in the family way, and that he was frequently having letters from friends containing valuable gifts. Nevertheless, he performed occasional offices of a household nature quite well; and was never known to be ill until he became affected by retention of urine. For this he had been treated, and was admitted into St. George's Hospital; it was found that he slightly dragged the right leg, and had lost some power of moving the right arm, and all power of moving the right wrist or fingers. The right leg, of which the movement was not quite perfect, was of natural form and shape; but the arm had the following appearance:—The fingers, which were long and thin, were flexed on to the palm of the hand, and the wrist on to the fore-arm, so as to give the hand very much the appearance of a bird's claw. The fore-arm was generally flexed upon the arm, but could be straightened, though all movement was somewhat impaired; that of the fingers and wrist being quite gone. There was no want of common sensation in the integuments of the arm. On measuring the arms at various points the following measurements were ascertained:—The circumference of the thickest part of the arm affected, above the elbow, was eight inches; whilst that of the healthy and unaffected arm was nine inches and a half. The length of the affected arm from the acromion to the elbow was twelve inches and a half; whilst in the opposite healthy arm it was fourteen inches. The length of the fore-arm on the affected side was seven inches and three quarters; whilst on the opposite side it was eight inches and five-eighths. For the retention of urine and enlarged prostate, the catheter was duly passed, and for some time the patient went on well; but after a while spasmodic stricture came on, and the urine became ammoniacal. In about three weeks after admission into the Hospital, the patient sank and died. After death the right fore-arm became rigidly flexed

on the arm, at an angle of about rather less than a right angle.

Remarks.—This cyst was, most probably, the result of the extravasation of blood, which had become resolved, although there was not the direct evidence of the fact in any discoloured yellow matter, such as very often is to be found in such cases. It shows well, if this be the case, how completely time will obliterate the effects of such a phenomenon. It seems very difficult on some accounts to connect the presence of the cyst with that of the partial paralysis of the limbs; but as no other cause could have existed, we are left in wonder how far the history of the case given by the friends is correct as regards the length of time in which the patient had suffered from paralysis; for it is a very rare circumstance for any extravasation of blood to occur at so young an age as that at which paralysis was said to have commenced: and, again, if the cyst was owing to a cause so distant, we might naturally expect greater contraction or cicatrization. At any rate the case indicates well to what an extent nutrition and growth may be obstructed by want of nervous power, whether this effect be, as most probably it mainly is, from primary paralysis of the muscles, and thus remote, or whether it be from the direct effects of the want of nervous action on the nutritive processes through the capillaries. In this case, as the bony tissues were so stunted (see the measurements of the arm), the effect may have been of a twofold nature, primary by action on the capillaries, &c. and remote by acting on them through the muscles; or it may have been entirely direct, the nervous stimulus, both to the action of the voluntary muscles, and to the capillaries being simultaneously interfered with. The deficiency of nervous influence was not complete, as is shown by the incomplete arrest of growth of the limb, and the incomplete loss of power of voluntary movement. Of course the false membrane, as its microscopical character indicates, was not of the same date as the cyst. Other facts of interest about the case are the affection mainly of the upper extremity coinciding with the injury to the corpus striatum, whilst the leg was less affected,

the optic thalamus being only slightly interfered with; also the contraction which the affected arm assumed after death, and the rigidity of its muscles. It is worthy of remark, that no history of any general spasm or rigidity of muscle during the patient's life was recorded, though the difficulty in straightening the arm then may be put down to partial rigidity of the muscles. It seems doubtful how far we are to connect the peculiar state of the patient's mind with the cyst —possibly no connexion whatever existed, for there was no history of any such mental condition as could be associated with interference with the corpora striata as portions of any centre of voluntary actions connected by radiating fibres with the surface of the brain.

Dr. J. W. Ogle, 1*st of April*, 1856.

---

7. *Fibro-cellular Deposit occupying the Left Optic Thalamus.*

The specimen showed the optic thalamus to be about three times its ordinary size, and encroaching greatly upon the right lateral ventricle (Plate II. Fig. 1.), the septum of the ventricles being pushed forwards by it. The mass was of a lightish yellow colour and very soft, giving to the mind the idea that a cyst was contained by it. Both lateral ventricles were much distended by rather turbid fluid, and their walls rather softened. The superficial cerebral convolutions were deep and flattened. The membranes of the brain and cranial bones were all natural. On cutting into the enlarged optic thalamus no fluid was found to be contained, and no cyst to exist; but the whole texture was of a uniform character, being of the consistence of thick putty and of a light fawn colour. The right optic thalamus was throughout softer than natural, but nothing more. The other parts of the body were quite free from any similar affection; nor was anything unnatural found in connexion with the various viscera, &c. excepting congestion of the lungs and an increased enlargement of the Peyer's glands of the intestines. It may be worthy of remark, that over almost the whole of one side of the abdomen and chest, numbers of brown stainings or spots existed, of various sizes, but chiefly of a circular form.

DESCRIPTION OF PLATE II.

The figures illustrate Dr. Ogle's case of enlargement of the Left Optic Thalamus, p. 12.

Fig. 1. Shows a section of the brain, laying open the lateral ventricles and displaying the left optic thalamus greatly enlarged and encroaching upon the right ventricle, and somewhat displacing and compressing the right optic thalamus.

a. The left optic thalamus, the surface being of a yellowish-grey tint.

b. The right optic thalamus.

Fig. 2, shows the microscopical elements of the divided optic thalamus.

a. Fibre cells of two chief kinds, simple and compound; the former being most abundant.

b b. Nuclei of the above fibres, of different forms.

c. Free cells.

Fig. 3, shows, by way of comparison, the elements of part of a healthy optic thalamus.

Fig. 2.

Fig. 1

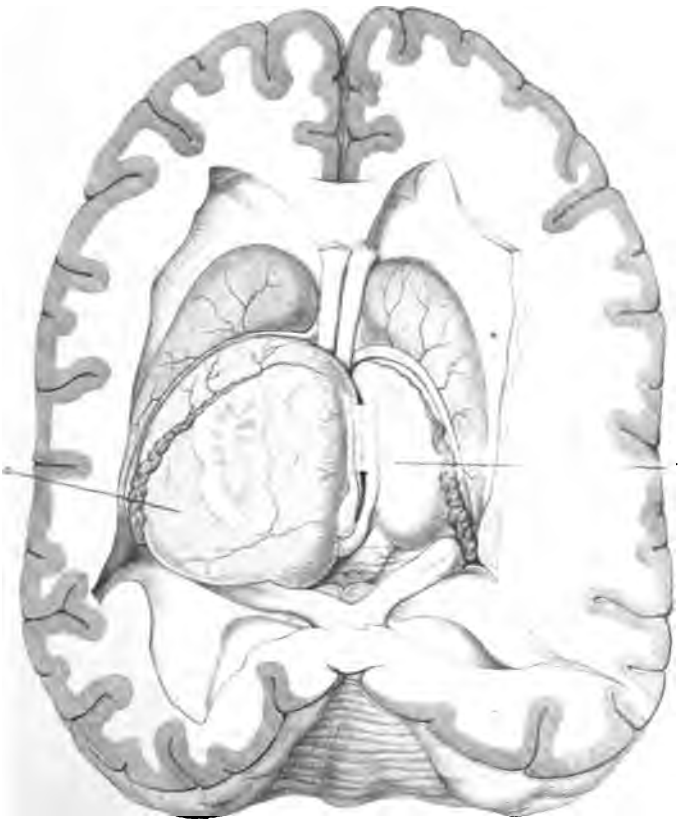

H V Carter del. Tuffen West sc.

W West lith.

With reference to this, the suprarenal capsules were examined and found to be healthy.

Microscopical appearances.—The enlarged optic thalamus was found to present vast numbers of fibres of the most delicate and fine fibrous tissue which it is possible to conceive (Plate II. Fig. 2*a.*), most of which had delicate granular nuclei (Fig. 2*b.*), chiefly oval, within them; and, though in scanty numbers, rounded and oval cells, with one, two, three, or four nuclei were also seen (Plate II. Fig. 2*c.*). Very little granular matter and no particular stroma existed; but the fibres and cells were connected indiscriminately. This character was maintained throughout the whole of the optic thalamus. On examining the other optic thalamus (Fig. 3), which was slightly softened, along with the normal elements much granular matter was visible in every direction; but none of the peculiar fibres spoken of as existing in the corresponding ganglion were seen.

History.—The specimen was removed from the body of a servant girl, æt. 19, who, having complained, for three or four days only, of sickness and headache, was received into St. George's Hospital, with a furred tongue, the papillæ at the edges being very prominent; a pulse of ninety-eight and small, and great thirst. Salines and cold lotion to the head were used, and the case was thought to be one of simple fever. Pain in the right iliac region was subsequently complained of, and about one week after her admission a peculiar manner was observed, which had somewhat the character of hysteria, and the patient at that time passed much pale urine. A few days after this she vomited much greenish fluid, which was checked by a dose of calomel, and she seemed to gain relief from slight mineral tonics and bitters. The vomiting and headache returned, and a blister was applied to the neck. Three weeks after her admission into the Hospital, the headache existing, drowsiness came on, but without any delirium or paralysis of any of the muscles, or alteration in the state of the pupils, &c.

Purgatives and calomel with salines, in frequent doses, were given, and the patient became more comfortable. Gradually,

however, she became more stupid, and eventually died comatose, just one month after the date of admission.

Remarks.—The chief points of interest in the above case are its similarity at the onset with simple fever, all special symptoms referable to brain disorganization being suppressed; also the peculiar symptoms called hysterical, attended by increased flow of limpid urine; even towards the close of the patient's life immunity from any leading symptoms referable to the brain, except vomiting. The enlargement of the optic thalamus must be attributed to the infiltration throughout its substance of a plasma from the blood which proceeded to the formation of cells and fibres. This infiltration had also begun in the other optic thalamus, as the microscopical appearances showed. As to the exact character of the growth, we must not hold it to be malignant, merely because longish cells, with one or more large nuclei, exist within it: the history and course of the case do not at all support such a view. It may be that more or less nucleated cells, with a highly prolific appearance, may arise in any exudation or plasma from the blood, dependant rather upon the anatomical and general character of the tissue in which the exudation has occurred, than upon any inherent and specific characteristic or property. That same exudation which in one part of the body advances to a condition having what are thought to be malignant elements, may, in some other part, have quite a different constitution.

Dr. J. W. Ogle, *6th of May*, 1856.

---

8. *Yellow Softening and Abscesses within the substance of the Middle Lobe of the Brain, coincident with disease of the Tympanic Cavity of the Temporal Bone.*

The specimen showed a large part of the under surface of the right middle cerebral lobe much softened, and of a pale lemon colour, both the cortical and the medullary portions being affected, and in the midst of this softened part was a collection of yellow pus, probably half an ounce, contained in a dense capsule of about one-twentieth of an inch in thickness, and of a dense leathery consistency, and very vascular. The only

indication of this condition of the brain, shown at its surface, was a slightly yellow tinge of the corresponding convolutions; the membranes covering the entire brain, as well as the various veins, &c. being quite natural. The ventricles of the brain were full of limpid fluid, and their walls were softened. Nothing more was observable about the brain. The cranial bones, including both temporal bones, were quite natural, saving great vascularity of the vaults of the skull, whose inner plate was very thin, allowing the vessels of the diploe to be well seen. The lungs were congested, and in one or two places patches of slight lobular pneumonia existed. The heart was slightly softened, and the blood contained was fluid, having but little clot. The kidneys were granular with numbers of cysts within them. Although it is said above that the temporal and other cranial bones were healthy, yet it was found that in the tympanic cavity of the right temporal bone a large fleshy growth existed, occupying much space in the cavity, and having exactly the appearance of the so-called "polypi" of various mucous surfaces. This growth was intimately connected with a very thickened condition of the lining of the tympanic cavity, but there was nothing more than a thinnish fluid in the cavity —nothing like pus, &c. The membrana tympani was natural; but the external surface of this membrane, and also the external auditory passage, were lined by a thickish film of false membrane, which was easily removeable. The left ear was natural.

Microscopical appearances. — The pus within the capsule, limiting the abscess in the brain, was of quite a healthy character as regards its microscopical appearances, and the capsule was seen to consist of well-marked fibrous structure, having numbers of elongated nucleated cells interspersed among the fibres. The softened brain around the abscess showed large quantities of granular and fatty matter mixed up with broken-down brain structure, and in some cases small irregular pus-globules; but healthy well-formed pus-globules were but rarely seen. The polypus-like growth in the tympanic cavity showed a very delicate fibrous structure, with numbers of longish, round, and oval cells having bright nuclei, combined; the cells were very much alike, and rather larger than pus-corpuscles.

History.—The preparation was removed from the body of a man, æt. 44, who was brought into St. George's Hospital with rheumatic enlargement of the joints, and albuminous urine. He had been in the Hospital for the same affection only a short time before. He recovered much under the use of colchicum and Dover's powder, and afterwards of the iodide of potassium; but when he had been in the Hospital for about ten days, he experienced great pain in the right ear, the rheumatic symptoms being aggravated. Much pain was also felt in the head some days afterwards; and on the fifth day following, a watery discharge from the right ear was observed, which in a few days became purulent. At the same time the pupils were noticed as having become contracted, and vomiting took place. Purgatives and cupping to the neck were used, and an improvement in the symptoms took place, but an increase of pain and vomiting again followed, and one month after admission, the left side became paralytic as to motion, coma set in, and the patient died three days after the paralysis came on.

Remarks.—The chief points of interest in this case, are the co-existence of the disease of the tympanic cavity and that of the middle cerebral lobe. How far they were connected it is impossible to say, seeing that neither bony tissue, nor membrane, nor blood-vessels intervening between them, presented any appearance of disease. Nor is it easy to presume, supposing their connexion, what relationship they had towards each other as cause and effect—for all ear symptoms were of a period later than that at which the actual condition of the brain showed that the cerebral disease must have begun, and yet the brain symptoms were never complained of until but a very short time before death; not, in fact, before the ear symptoms set in. This is one of the many cases which have been met with, showing how, under some circumstances, extensive disease, advancing even to circumscribed abscess, may exist for a length of time, and but little mental aberration result.

Dr. J. W. Ogle, *6th of May*, 1856.

---

9. *Gangrenous Abscess of the Brain, induced by Disease of the Internal Ear.*

On Saturday morning, the 17th of May, at one o'clock, Dr. Theophilus Thompson was requested by Dr. Sawyer, of Guilford Street, to see with him and Mr. Sellwood, a gentleman of nervous constitution, but placid disposition, and very temperate habits, æt. 30, who had been attacked about an hour previously with delirium. This delirium was subsiding, but the patient was speaking rather rapidly and incoherently, and did not recognise his wife, or seem to take any interest in his child, but he relished some orange which was put into his mouth, and taking out the pips placed them accurately on a candlestick which happened to be near him. His pulse was one hundred and forty, and very weak, and his general condition was one of prostration. He had been considered in average health till about eleven o'clock on the previous evening, when he had an attack of vomiting. A week before, he had thrown up his dinner, and, subsequently, for a few days was affected with symptoms such as are usually referred to influenza, but which entirely subsided, and he had continued free from any serious symptoms until the evening of the attack. There was no palsy or convulsion, and no tremulousness of the tongue, and his sleep on the preceding night had been good, although somewhat disturbed for a few nights previously. In the absence of any obvious cause for gastric disturbance, the symptoms, more especially the vomiting and delirium, were considered by Mr. Sellwood, Dr. Sawyer, and Dr. Thompson, to indicate brain affection. The patient was affected with deafness and discharge from the right ear, which had existed for more than twenty years, as a result of scarlet fever. The prognosis given was unfavourable, under the impression that, after a few hours, he would become comatose and sink; for it seemed probable that disease of the ear had extended to the brain, occasioning suppuration under the dura mater, and, perhaps, also in the substance of the brain. The unfavourable progress of the case proved even more rapid than was anticipated. The patient soon lost the power of speaking, and

although he recovered for a time so much intelligence as to recognise his wife and child, and evince affectionate emotion, his breathing became gradually slow and almost stertorous, and the countenance having been for some time livid, after a few imperfect pulsations of the heart, he died at half-past five.

Post-mortem inspection, fifty-six hours after death.—The dura mater was found detached; apparently in consequence of the intrusion of air over a small portion of the upper part of the petrous bone. At this point was an ulcerated opening in the membrane, rather less than a threepenny-piece in circumference. There was a corresponding opening in the substance of the brain leading into a cavity, or rather channel, which passed into the lateral ventricle, and contained dark green sanies. The sides of this channel were disorganized, of dark grey colour, and offensive in smell. The adjoining tissue was softened, and surrounded with red points here and there, blending into clouds and patches. The part of the dura mater near the internal auditory foramen, was thickened, uneven, and covered with pus. The petrous bone was slightly roughened on its upper surface, and a portion of the interior being separated, was found to be softened, crumbling, and infiltrated with pus.

This case is remarkable for the long continuance of the disease of the ear before it extended to the brain, for the insidiousness with which serious disease of this organ involved the brain, and for the suddenness of the fatal issue after the first occurrence of alarming symptoms. The gangrenous character of the cerebral mischief is also worthy of observation, being possibly due to the continued access of air in aggravating inflammatory action.

Dr. THEOPHILUS THOMPSON, *20th of May*, 1856.

---

10. *Tumor from the Brain.*

The specimen was removed from a man, æt. 36, whose history is imperfect. He died in St. Pancras Infirmary, to which he had been admitted about three weeks before his death. When admitted he complained of headache and a cold, for which he was ordered Dover's powder. Nothing indicative of paralysis

was noted at this time. A few hours after taking the powder he suffered from symptoms like those of opium poisoning; and means were employed to keep him awake. There is no reason to believe that more than ten grains of the powder had been administered. On recovery from this state it was found that he possessed a little more power on the left side of his body than on the right. He stated that he had not been subject to headaches; his intellect was dull, and he was constantly in a drowsy condition; his sight was not materially affected; his appetite was usually moderate. Whilst in the Infirmary he had many comatose attacks, which lasted several hours, unattended with convulsions. At these times he could not be roused. During his stay he gradually lost power over his bladder and sphincter ani; and sensation in the lower extremities became defective, but mobility was not much affected. He died in a state of coma.

On *post-mortem* examination it was found, after removing the skull cap, that the membranes were very vascular. On the left side of the upper surface of the cerebrum, near the junction of the middle and anterior lobes, was a prominence of the dura mater, in size and shape resembling a thrush's egg. The pia mater over this part was much injected. On making the first slice into the left hemisphere, it was found that the brain substance in front presented a peculiar yellowish aspect; it was of about the same consistence as normal brain substance; if anything, rather softer. This altered portion, which was spheroidal, was separated from the rest of the brain by a tolerably firm capsule. The lower two-thirds of the mass was turned out, without tearing the surrounding brain substance.

The mass, on section, presented an appearance resembling yellow tubercle at some parts; whilst at others, near the centre, it resembled, in naked eye characters, encephaloid cancer.

Under the microscope there were seen, at some points, a large number of so-called exudation corpuscles, with brain fibres and cells; at other portions large cells were seen of ill-defined outline, each containing a nucleus, with well-defined linear outline, and a very clear sharply defined nucleolus, or nucleoli.

Some of the cells appeared to be undergoing fatty degeneration.

Dr. HILLIER, *5th of February*, 1856.

Report on this specimen.—The tumor, which appeared to have been already a good deal changed by the solution in which it had been kept, was about the size of a child's fist. Its structure was softish, and very readily broke down under pressure into a curdy pulp. Externally, it appeared to be surrounded by a thin membranous envelope. Its section presented a peculiar blotched appearance, varying in colour from a dark maroon-brown, to greenish and greyish yellow. Embedded in its lower part was a nodular mass about the size of a walnut, much harder than the one from which it was circumscribed by a thin cellular envelope. This mass cut rather crisply, and did not break down without hard pressure; it exuded juice, however, plentifully, and in its microscopic elements did not materially differ from the softer parts of the tumor. The juice taken from different parts showed characters which, on the whole, well corresponded with each other, and are accurately represented at Plate III. Fig. 1. The most abundant cells were elongated ones, containing each a single large nucleus, generally situated at about the middle of the cell, and greatly bulging its walls. The nuclei were oval, of distinct outline, had granular contents, and mostly from one to three, more or less distinct nucleoli. In a few rare instances, these elongated cells had two nuclei, as shown in a cell to the left hand of the sketch. Very sparingly indeed, and only found after long search, were large rounded bodies containing numerous very large and distinct nuclei. With regard to some of these, it was doubtful whether they were not mere aggregations of free nuclei; but others, as was the case with the one sketched, had a distinct envelope. In addition to these varieties of cells, the field showed much free granular and oily matter.

The question as to classification of the tumor, seemed to be between myeloid and cancer. Its defined outline, and freedom from adhesions to the adjacent cerebral lobes, were features of dissimilarity from the more usual forms of cancer. The

circumstance that the vast majority of cells were mononucleated only, and bore a very marked resemblance one to another, also pointed in the same direction. On the other hand, its abundance of cell forms and of nuclei, was suggestive of rapid growth and malignant nature. Those of the cells most resembling myeloid bodies, had yet some features of difference, inasmuch as they were three times the ordinary size of such, and their contained nuclei were also very much larger. The tumor ought, probably, to be regarded as an example of a form of cancer peculiar to the brain, and differing in several points from those met with in other localities.

Mr. HUTCHINSON, *4th of March*, 1856.

---

11. *Tumor of the Brain.*

The person from whom this specimen was taken, was a robust, florid, healthy looking man, with good muscular development, very active, and who had always enjoyed good health. His occupation was preparing gentlemen for the army examinations; he was in affluent circumstances, and rather a free liver.

While on a tour in Switzerland, he accidentally fell from a diligence upon his head. He was stunned and insensible for a few minutes; but on recovering did not complain of any pain in the head; nor did he do so on his return home.

In September, 1852, just about two years afterwards, however, while I was professionally attending his wife, he jocularly asked me what sort of physic *he* wanted? at the same time protruding his tongue, which I observed was turned to the left side, but was perfectly clean. As he was not suffering from any pain in the head, but merely slight constipation, and was not otherwise ill, I ordered him some aperients, and advised his taking a shower bath every morning.

By the use of these means for a short time, the lateral protrusion of the tongue was entirely removed, and he appeared well for twelve months, when he was attacked with scarlet fever, from which he quickly recovered without any untoward occurrence. After this he remained well until February last

year, when he complained of headache, which was quickly relieved by a few doses of aperient pills. On its recurrence a week or ten days afterwards, he consulted Dr. Jenner, who prescribed aperients, with slight tonics, from which he appeared to derive benefit. As he seemed tolerably well, I did not see him, after the first of April, until the middle of June, when he again began to complain of headache with considerable gastric derangement.

He described the pain in the head as of a bumping character, usually attacking him in the night, and obliging him to jump out of bed and walk about his room, or bathe his head with cold water, from which he obtained relief. He was very drowsy after dinner, usually slept two or three hours in his chair, and manifested great irritability if disturbed, or his wishes were interfered with. His manner became changed to those constantly about him, but he was always animated when in my presence. It was remarked that he had more difficulty than usual in expressing his thoughts, and generally stammered when spoken to; but as he had always done so more or less, little notice was taken of it. He still went a good deal into company, and generally suffered from headache after any indiscretion in diet.

At the period now alluded to I prescribed aperient salines with Digitalis, and a blister to the nape of the neck, which once more rid him of pain: and I recommended him, in order to rest his brain, to leave his professional labours for a month, and go into some quiet country place, where he could amuse himself with fishing. Instead of doing this, however, when he arrived in the country he appeared restless; went about from place to place visiting his friends, and going into company; and returned home at the end of a fortnight worse.

On his return, in the beginning of September, the performance of his duties began to appear irksome to him, and his attention to them was much less than was his custom. It became apparent that he had recently neglected his accounts, which had become disordered. He constantly placed away money he had received, and forgot where he had put it. His memory was becoming daily more impaired; and an imbecility was now very obvious in his manner. He would laugh at

trifles; he became unable at this time to write correctly; he could not sustain his efforts long enough to write a cheque; and was obliged to get his wife to dictate his letters. When visited by gentlemen on matters of business, he was frequently quite unable to speak to them. He could not walk without great effort, and soon complained of fatigue. He now squinted with both eyes; but this symptom was not quite constant, and only lasted about a week. He appeared frequently to drag his legs, but not one more than the other; and he could sometimes walk very nimbly. There was no difference in power between the two hands, which possessed great strength. It was desired that, in order to get exercise, he should ride on horseback; but this he positively refused, from the fear he had of falling off. He was now very lethargic, quite unable to give his ordinary lessons, and not seeming to care whether they were given or not. He appeared automatically to walk into his study, and almost always came out in a few minutes, without having given any lessons; and when questioned on the subject, he usually replied "Well, never mind;" whereas, before his late excursion, he stated his inability to go, because he could not spare the time, and would be losing money.

For some weeks he had ceased to take any interest in pursuits and amusements which were wont to engage his attention. His garden, of which he had been very fond, was now neglected, and he appeared indifferent to all the usual sources of interest, and desirous only to lie down and sleep, for which he constantly used to solicit, even in the middle of the forenoon.

In the beginning of September he consulted Dr. Mayo, who formed a very grave opinion of his case. He was cupped, and some simple aperient ordered; on the 15th we met in consultation, and bichloride of mercury was prescribed in doses of one-twelfth of a grain twice a day. The bichloride of mercury (which was never carried to ptyalism), appeared to produce a mitigation of some of the symptoms; and, after trying it a month, he was again recommended absence from business pursuits, and quiet. From this journey he returned worse than before.

His friends now sought the assistance of Drs. Todd and

Winslow, who met in consultation, and recommended a trial of mineral acids, with occasional warm purgatives. After a short use of these remedies, which was not attended with any benefit, he was sent into the country by the advice of Dr. Winslow, to be under the eye of a medical man. In this place he remained three months. At first he appeared to be improving; but at the end of two months he fell while walking in the garden, but did not appear to have had any fit. He shortly after became comatose, but was relieved by blisters to the nape of the neck. Soon after this a large carbuncle made its appearance: this again relieved his head, and a seton was subsequently applied. As he became very unhappy at being absent from home, it was thought desirable he should return. On his arrival there, about three weeks before his death, Mr. J. F. Clarke was recommended by Dr. F. Winslow to watch the case; and, consequently, I did not see him again during his life. He is stated at this time to have walked with greater difficulty; to have been unable to get up from his chair without assistance; to have become gradually weaker in power and intellect; and to have suffered from pain in the head.

Two days before his death he appeared much better; walked across the room by himself; paid more attention than usual to what was passing around him; but at night complained of headache. In the night he ground his teeth very much, and started in his sleep; and on the following day was very drowsy, but when spoken to he opened his eyes and squeezed the hands of those who spoke to him. In the course of the day he was seized with vomiting, which continued some hours; after which he gradually sank, and died comatose on the night of the 29th of March.

Post-mortem examination sixty-four hours after death.—The body was plump and well nourished, but not fat, and was not more decomposed than natural. In removing the skull nearly two ounces of blood escaped; and the dura mater was found covered with effused blood, which was probably the immediate cause of his death. The brain appeared somewhat shrunk, especially on the left side; and the dura mater was closely adherent to it about the junction of the anterior and middle

lobes of that hemisphere. This adhesion was about two inches in diameter, and the section gave the idea of a hard cartilaginous mass being cut through. On further examination this hard substance was found passing inwards towards the centre of the brain, extending to within half an inch of the median line. The tumor, when removed, was a hard mass about the size of a small orange; its surfaces were smooth, except where it had adhered to the dura mater. Immediately surrounding its attachment to the dura mater, the convolutions appeared pushed outwards in the form of auricles. The substance of the brain, for more than half an inch was softened to the consistence of cream; and the whole of the left hemisphere was rather softer than natural. The right side was quite healthy. A section of the tumor, which is hard, had a reddish cartilaginous look.

On reflection it appears very natural to suppose, from its strong attachment to the dura mater, that the tumor had its origin in connection with that membrane, probably from escape of blood: that, most likely, the period at which it commenced was when the patient had the fall before referred to; and that it gradually pushed its way inwards towards the median line, destroying by its pressure the healthy organization of the brain. Mr. PART, 1*st of April*, 1856.

Report on this Specimen.—The tumor was of a rounded form with a rather irregular surface, and equal in size to a small orange. It was partly covered by brain structure, but not entirely; and of the nervous structure in close contact with it, part was of the white and part was of the grey variety. It was abundantly surrounded by blood-vessels, but had no distinct capsular investment. On section it proved to be vascular and of a lightish pink-white colour, not unlike the grey matter of the brain, but very firm. In one or two places it was much firmer than in other parts, and paler. Microscopical examination showed the following elements.

1. Fibrous tissue, abounding in most parts, in various stages of development, many parts having gone on to the formation of firm, broad, and parallel bands; but in no case was any interlacement, or any attempt at areolar arrangement to be seen.

Occasional granular and fatty particles.

3. Cells of various forms and sizes; one kind, consisting of a simple membrane, was small and rounded, or oval, a few being very elongated, but all containing longish nuclei. Another variety was very large, oval, or round, containing, some, merely large nuclei, as many as seven or eight in number, and others very large nucleated nuclei, and many of these had their terminations prolonged into fibrous tissue, containing, in some cases, oval nuclei, in others no nuclei at all. Some of these large nucleated cells were of very odd shape, as if from imperfect division. The cells most worthy of notice were those whose walls were very much thickened at one side, having a nucleus generally containing granular matter within their texture; and these, in many cases, gave the appearance of the cell having been originally formed by elongated, curled, or semi-annular cellules, whose arcs had, as it were, been filled up by blastematous material, and the curved wall of the original cellule so continued as to form a wall round the entire mass, within which, probably, new corpuscular elements had arisen.

4. Blood-vessels in considerable numbers.

Dr. J. W. Ogle, 1*st of April*, 1856.

---

12. *Tumor on the Pons Varolii.*

A little girl, æt. 10, was a patient of Dr. Ince's, at the Surrey Dispensary. Her health had been good until about eight months before her death, when she began to complain of headache, and at the same time her appetite became variable and she had frequent vomiting. These symptoms continued about a month, when her mother began to notice a twitching of the muscles and a little convergent strabismus. During the first three months of her illness she was up; but after that time she mostly kept her bed, on account of the severe headache to which she was now more than ever subject. She then was under the care of a medical practitioner, and treated by mercury for active disease of the brain. When she first became a Dispensary patient, three months before her death, her only complaint was pain in the head, which came on more violently

at night, and was situate over the forehead. In other respects there was not much to notice; there was now no vomiting or strabismus; the appetite was good and bowels regular. She was again treated by various remedies, and in six weeks' time was a little better, so that she was able to leave her bed for a few hours daily. After this time she grew worse; the pains in the head increased, and occurred in more frequent and violent paroxysms: so bad at times were they that she appeared like one raving mad, and yet in the intervals she was so quiet that it seemed as if little was the matter with her. During the last three weeks she frequently complained of numbness in the right arm. She was never delirious, and her mind was always clear. The paroxysms of pain grew worse and worse, until one morning she called her mother when the attack was coming on, and died in her arms.

After death the head only was examined. Growing from the pons Varolii was a large irregular-shaped mass of disease, not appearing at first strictly defined, but so interwoven with the brain structure, and so resembling the general configuration of the natural organ, that it seemed like the pons swollen to about double its natural size. Upon closer examination, however, its flattened, smooth appearance, was seen to be due to the pressure it had undergone against the floor of the skull, for, after it had been in fluid the tumor presented a remarkable lobulated growth, and divided into two lateral halves by the basilar artery, which ran in a deep sulcus between them. Each half consisted of three or four lobes, which grew directly outwards; but which had been made to meet together in the mesian line by the pressure they had undergone. These growths could not be distinguished either in colour or consistence from the ordinary cerebral structure, nor was there much difference apparent when a vertical section was made through one of the lateral divisions. After being placed in spirit, however, the true brain tissue became more opaque and hard, and then the adventitious growth made itself more manifest. In the section this appeared not as one strictly defined mass, but as having three or four distinct centres with the cerebral structure passing between, or it put on this form from pushing its way

between the fibres of the pons. The cut surface thus presented rounded growths, semi-transparent, and slightly protruding; and these, to the finger, felt soft, but, at the same time, tough and elastic; the opaque white fibres of the medulla clearly defining them. The whole of the lobulated structure which appeared on the surface was composed of this new growth.

Upon microscopic examination this growth was found composed of a tissue very loosely held together, and consisting, for the most part, of large nuclei and delicate fibres. The fibres, which interlaced in all directions, were of great length and extreme tenuity; the nuclei dispersed amongst them were very large and very numerous; many had a distinct cell-wall, which closely enclosed the nucleus itself, and from each extremity of which proceeded long fibrous prolongations, exactly corresponding to the fibres before mentioned. Running through the whole of the tumor was another structure, which appeared as a stroma or skeleton to support the other elements. This was composed of soft, branching filaments, which, in their general appearance, were not much unlike the capillary vessels of the brain. They contained numerous oval nuclei in their walls, were slightly granular, and terminated, in many places, by a fibrous prolongation of one of the nuclei.

In the present uncertain definitions of cancer there may be a doubt as to what class of tumor this should be assigned; but from the peculiar formation of its groundwork and nucleated cells I think it must be styled carcinomatous. This leads me to express an opinion, that not only should there be an endeavour to classify the morbid growths which occur in the human body, according to their structure, but that greater study should be given to investigate the diseases of particular organs, which are, probably, to a great extent, peculiar to each. Dr. WILKS, *6th of November*, 1855.

---

13. *Tumor of the Cerebellum.*

Autopsy.—Body a little emaciated. Calvaria rather thick, but otherwise healthy. Dura mater healthy. There was a fair quantity of subarachnoid fluid. The surface of the cere-

brum, and that of the greater part of the cerebellum, were healthy. None of the blood-vessels contained an abnormal quantity of blood. On examining the under parts of the cerebellum, pons Varolii, and medulla oblongata, a tumor was observed on the right side in the interval between these bodies. It was irregularly quadrilateral, occupied about a square inch in area, and projected on the average about half an inch. Its surface was somewhat rounded and nodulated, and had a good deal of resemblance to that of the brain-structure around; that is to say, it presented much the same colour (though it was somewhat darker), and the arrangement of vessels upon it gave it a convoluted, and, in some parts, a foliated character. A further examination showed that the tumor sprung from the right half of the pons Varolii, and from the corresponding crus cerebelli; and that it extended partially into the medulla oblongata, the right anterior pyramid and olivary body of which were enlarged, and of a darker colour than those of the left side. The fifth nerve arose immediately to the outer side of the tumor, and the sixth and seventh nerves immediately behind it; but beyond being slightly displaced, they did not appear to be affected by it.

On making sections of the brain, the white substance was found to be decidedly more congested than usual, but not at all softened. The lateral ventricles were dilated, and contained a very large quantity of serum. A vertical incision was made through the middle of the tumor, from the left anterior angle of the pons Varolii, to the right posterior angle of the cerebellum; and from this it was seen that the tumor, in its deeper portions, presented no definite limit, but that it passed insensibly at its edges into the surrounding brain-substance. The substance of the tumor had a greyish, slightly translucent aspect, and was considerably congested, the congestion being somewhat patchy; and it was rather firmer and more elastic than the healthy brain-substance. The colour, the congestion, and the consistence, diminished gradually at its edges, until they were lost in the healthy white substance around it. The tumor appeared altogether to be somewhat more than a cubic inch in bulk. A section through it into the medulla oblongata

showed that it extended for some little distance into the right olivary body and anterior pyramid, and that it presented here a more defined border than it did in the cerebellum.

The spinal cord was perfectly healthy.

Except for the presence of slight bronchitis, the thoracic and abdominal viscera were all healthy.

Under the microscope, the tumor appeared to consist wholly of cells, fibres, and blood-vessels.

The blood-vessels differed in no degree from those that exist normally in the brain. The fibres (*see* Fig. 1.) were very numerous, more or less curvilinear, interlaced, and without apparent definite arrangement. They varied considerably in thickness, ranging from $\frac{1}{3000}$th or $\frac{1}{4000}$th of an inch downwards; and this variety in size was observed not only in different fibres, as compared with one another, but also in different parts of

Fig. 1.

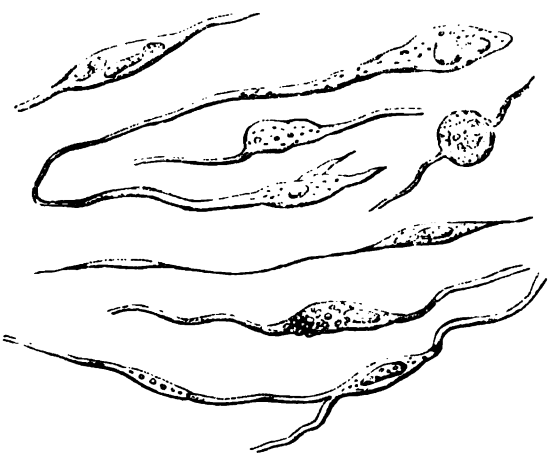

Fibres, dilated at intervals into cells,—some of which contain nuclei, whilst others are empty.

individual fibres. They were perfectly homogeneous and transparent, and presented sharp definite outlines. Their form was,

for the most part, cylindrical, and, judging from peculiarities in their refractive properties, I feel no doubt that the majority of the dilated portions were hollow, and, indeed, that the fibres themselves, in many instances at least, formed hollow cylinders—that is to say, that they consisted of homogeneous transparent walls, enclosing homogeneous and probably fluid contents. The dilatations I have alluded to, were generally fusiform, and either of small extent, or occupying a considerable portion of the length of a fibre; often, however, they were more or less irregular in shape. The smaller ones were frequently as structureless as the undilated fibres; sometimes, however, they presented strings of bright refractive globules. The larger ones, for the most part, contained globules of a similar character, sometimes few in number, but frequently exceedingly numerous, and densely aggregated. The cells varied considerably in size and shape. They were sometimes globular or ovoid, but usually fusiform, and more or less tuberculated. They contained from one to four or five nuclei, mixed sometimes with a quantity of minutely granular matter, and sometimes with a greater or less number of refractive globules. I have called the bodies I am describing, cells, partly from their form, but chiefly because they contained nuclei; I believe, however, that their nature was essentially the same as that of the non-nucleated bulgings that have been described as existing in the course of the fibres. Few, if any, of the cells were isolated. I believe that all were continuous with fibres, and occasionally one could very distinctly recognise two cells in the course of a single fibre. In most cases, both extremities of a cell were attenuated and prolonged into fibres; occasionally, however, only one end was thus circumstanced, and in not rare instances three or four fibres were given off from different portions of the surface of an irregularly-shaped cell. The same peculiarity was observed also in some of the non-nucleated enlargements. The nuclei were globular or ovoid, most of them being ovoid. They varied a good deal in size, but usually ranged between the $\frac{1}{4000}$th and $\frac{1}{2000}$th of an inch in length. They contained, occasionally, minute granules, and sometimes from one to three distinct nucleoli.

The cells and fibres formed evidently the essence of the tumor; and, from the description, I think it may be concluded that these two elements were essentially one. It seems to me, indeed, clear that the growth consisted of a series of fibres which had a tendency to become hollow, and to dilate at intervals, and in the dilatations thus formed to produce nuclei. It seems clear, too, that the fibres had a tendency to branch, and that this tendency was most marked in the situation of the dilatations. Hence, I think, it may be assumed that the growth of the tumor was effected by the formation of dilatations and cells in the course of the fibres, and by the development from these, and not improbably from other parts also of the fibres, of prolongations capable of undergoing a similar series of changes. Nothing that I observed led me to believe that nuclei, while *in situ*, took any active share in the growth of the tumor; and I cannot help surmising that any part they may have been destined to play, must have been contingent on their escape from the cavities in which they were produced. The mode of growth in the cells above described, seems to me to be exactly similar to the mode of growth in myeloid cells. The chief distinctions between the two kinds of tumor being, that in the myeloid the cells are more conspicuous, the nuclei in larger groups, and the fibres less abundant and less developed, than they were in that which is the subject of the present communication.

The above tumor was, I believe, identical in character with one reported on by Mr. Toynbee, at page 18 of vol. iv. of the "Pathological Transactions," which I examined, and of which I have drawings. In that case, a good deal of the tissue was degenerated, and the degeneration appeared to be due to an excessive deposit of oil in the fibres and in the cell-like enlargements. The first stage of this change was evident in the present tumor; but still actual degeneration can scarcely be said to have occurred in it. With regard to the nature of the growth, I may observe, that it does not seem to me to have had the characters of any tumour that we know positively to be cancer; and as, according to my opinion, it had the same mode of growth that myeloid tumors have (which tumors we have at present very

strong reasons to regard as innocent), I conclude that this was likewise non-malignant.

The specimen above described, was taken from a man æt. 33, of whose history, I regret to say, I know very little. He had certainly been ill for some months, during which time he had many epileptic fits. Latterly he sank into a semi-comatose condition, became paralysed, and passed his motions and water unconsciously. Dr. J. S. Bristowe, *4th of March*, 1856.

---

14. *Large Cyst containing six ounces of fluid, pressing on the under surface of the Cerebellum, and occupying the Fourth Ventricle.*

The specimen showed a cavity whose walls were formed by the under surface of the cerebellum above, and the upper or posterior surface of the medulla oblongata and pons Varolii below. The cerebellar boundary was lined by a somewhat shreddy layer of toughish membrane, which was obviously the thickened arachnoid and subarachnoid tissues; whilst the opposite or medullary boundary was only lined by the proper delicate membrane of the part. The fluid was of a light straw colour; and quite clear and limpid; and by it the cerebellum was much expanded and hollowed out. The whole cavity was, in fact, a very large fourth ventricle, whose proper boundaries, the valve of Vieussens, &c. were quite lost in the general extension. The lining membrane, where reflected upwards to the under surface of the cerebellum, had been torn through in the removal of the brain. The lateral ventricles of the brain were very large, and full of clear fluid to the amount of not less than a pint; but their walls were firm and unaltered in look. The surfaces of the cerebral convolutions were flattened, and the subarachnoidean space was free from fluid. In other respects the brain and its membranes presented nothing unusual; and the calvaria, except being of increased size and thickened chiefly at the posterior part, was also natural. The lungs, liver, and kidneys were congested, but nothing more. The heart was natural.

Microscopical appearances.—The membrane lining the cyst consisted of very delicate clearly-outlined connective tissue,

crossing in various directions, having here and there granular matter, and a few small indistinct corpuscular elements.

History.—The specimen was removed from a boy, æt. 8, who was of a pallid, sickly look, with a rather large head, and slightly, but not much, emaciated. It seemed that, three years previously, he had had an attack of acute hydrocephalus, after exposure to a blazing sun for some time. Convulsions came on, followed by delirium; and strabismus and total blindness, with stupor, supervened in the course of a week, and lasted nine months. He had, at times, screamed much, and been troubled by sickness. The stupor continued, and for two weeks before the patient came into St. George's Hospital, he had been unable to support the body, from weakness in the lower limbs. When admitted, the above-mentioned symptoms existed; the sight was tolerably good with the right eye; but still the eyelids did not close when any object was suddenly brought to the eye. The tongue was furred, and the pulse quickened; but no sickness existed, and there was no affection of the thoracic viscera. By the use of leeches and purgatives he amended much; the tongue becoming cleaner, and the pulse quick, although uneven. After a time he relapsed, and sickness came on, and he screamed much at night, and became more stupid. He was again relieved by active treatment, but again relapsed. Partial convulsions came on, in which the head was dragged to one side, and the arms jerked unsteadily, but not violently. Pain in the head was also occasionally complained of. The tongue became foul, the appetite capricious, the pulse quick and irregular, and he gradually lost the use of all his limbs and power over the sphincters, the evacuations being very offensive. He was subsequently attacked by violent vomiting, and on the following day died in a state of general convulsions.

Remarks.—The cyst was manifestly not formed by the softening and liquefaction of solid material, such as fibrin, carcinomatous or scrofulous deposit; nor was it owing to the presence of hydatid parasitic formation. The case is interesting as showing how the accumulation of simple fluid, being the result of inflammatory action, may act injuriously in being limited by

false membrane, or thickened and adherent neighbouring tissues. No doubt the fourth ventricle, like the two lateral ones, had been distended by the effusion of fluid; and this, increasing in quantity, whilst the thickening of inflamed arachnoid and subarachnoid tissue prevented its escape or absorption, produced a decided cyst or cavity, which, had it been in most other parts, would have been of but little moment. The thickening of the posterior part of the skull, in connexion with disease of the membranes about the cerebellum, is worthy of note. Dr. Ogle had, on previous occasions, suggested the idea of the formation of cysts about the brain by the thickening and adhesion of opposed membranes; and had illustrated this view as regards the surface of the brain and cerebellum, by preparations shown to the Society, and described in the "Transactions," 1853–4, p. 1; and 1854–5, p. 20. He had never before seen, or heard described, any similarly formed cyst owing to the enlargement of a natural ventricle.

Dr. J. W. Ogle, *15th of April*, 1855.

---

15. *Chronic Inflammation and Ossification of the Membranes of the Spinal Cord.*

N. F. æt. 46, was admitted into Guy's Hospital, under Dr. Gull's care, 22nd of June, 1855. By occupation a dancing-master; his previous health was good, with the exception of two attacks of gout many years before. A year before admission he noticed that he could not give the step to his pupils so adroitly as he had been accustomed, but took no further notice of the circumstance until six months afterwards, when these symptoms became rather suddenly aggravated. He found that, after sitting, he could not stand steadily for some minutes; he also had pains in the arms; and the sphincters were becoming weak. He since had only just been able to hobble about, and had been troubled with very severe spasmodic twitchings in the leg.

On admission into the Hospital, he was placed in bed, and it was then found that he could move the leg up and down, but had no power to stand. The sensibility was diminished below the distribution of the seventh dorsal nerves; and he had a

sense of constriction around the lower ribs. The excito-motor actions were produced by the slightest movement of the bed; and when left quite quiet he was greatly troubled by what appeared spontaneous startings of the legs, but which seemed due to the dribbling of the urine at intervals through the urethra. The legs were more or less permanently flexed: the spine was in no way distorted, and there was no tenderness or pain in the part. He said his spine felt as strong as ever it did, and that the severest blow there would not hurt him. The sphincters were paralysed, and he had profuse sweats.

Becoming gradually worse during the month he was in the Hospital, his friends removed him. The rigidity and flexion of the legs had increased; and his rest was prevented by the continued spasms of the muscles. One night these were so violent as to jerk him off the bed on to the floor.

During the three months from his leaving the Hospital until his death on the 21st of October, he was visited by Dr. Gull. The legs became gradually drawn up, the heels to the nates, and the knees to the abdomen; and any attempt to move him gave him great pain. Subsequently large bed sores formed; the feet became œdematous; the mouth aphthous; and there was frequent vomiting. The intellect throughout was unimpaired. Although sensation was diminished in the lower extremities, he had the power of telling which toe was touched. The slightest touch of the foot or concussion of the bed set the whole of the muscles into increased contraction, and gave him great suffering. It was easy to see how a further destruction of the cord would have greatly mitigated his miserable symptoms.

After death the spinal cord only was examined. The bony canal was healthy. All the spinal membranes from the lower part of the cervical region, throughout the dorsal, and, to a less degree, in the lumbar region, were much thickened, and adherent to each other. The dura mater and arachnoid could, however, be separated without much trouble until reaching the upper dorsal and cervical region, where the membranes became firmly adherent to the cord and to one another. They here, too, became considerably thicker, and the dura mater quite rigid and bony. This was especially the case on the

posterior layer. These bony plates, when examined microscopically, presented the characteristic osseous lacunæ and canaliculi, differing from the normal bone of the skeleton only in the larger and more variable size of the lacunæ, and the less numerous and delicate channelings of the canaliculi. The lacunæ had a disposition to arrange themselves in concentric rings, being separated into distinct parcels by columns of fibrous tissue passing between them. Beneath the ossified dura mater, the arachnoid and pia mater formed another very thick and tough fibrous layer, closely adherent to the cord. A transverse section showed the medulla firmly enclosed in two thick coverings, the outer being bony. The body of the cord throughout the whole of the dorsal region was wasted and soft; the surface immediately beneath the thickened pia mater was slightly translucent. This appeared due to an inflammatory change which had occurred in its substance, granular exudation and granule cells being abundant. The continuity of the columns was not otherwise interrupted. All the above-named lesions seemed due to a chronic inflammation of the dura mater, and a more recent sub-acute inflammation of the other membranes, extending slightly to the body of the cord. The bony plates were situated in the substance of the thickened dura mater, and probably arose from the degeneration of new fibrous tissue.

Remarks.—The absence of pain or inconvenience in the course of the spine is remarkable, when the membranes were so extensively affected. In this alone did the symptoms of the case differ from that of the tumor of the cord recorded below, the other symptoms being remarkably alike;—such as the gradually increasing paralysis, with the more marked spasmodic contractions and pains of the legs.

Dr. Wilks, *6th of November*, 1855.

---

16. *Tumor of the Spinal Cord.*

S. A. æt. 43, admitted into Guy's Hospital, under Dr. Hughes' care, on the 25th of July, 1855.

She was single, and a cook; had always enjoyed good health

until the commencement of the present illness. She stated that six months before, after taking cold, she first experienced pain between the shoulders and in her chest, and in a few days pains in the legs; she was obliged to leave her situation, and became a patient at the City Dispensary, where she was blistered between the shoulders without relief. She then went into the country, but grew still worse, her legs becoming so weak that she could with difficulty walk. Thinking rest would be serviceable, she took to her bed, when, at the expiration of a fortnight, she found she was quite unable to rise again; at the same time, she could not perfectly extend her legs, as they had a constant disposition to draw themselves up towards the abdomen. Since this time she kept her bed, the pains in the legs continuing, and with the addition of, what she called, spasms in the stomach.

On admission into the Hospital, she was very thin, and lay just in the position in which she was placed, having very little power to move herself. Her position was on her side, with her legs drawn up towards the body. If these were forcibly extended, they would gradually again flex themselves; she was able to move them slightly, but quite unable to stretch them out; she had lost partial control over the bladder and rectum; sensation remained perfect. Her principal symptoms were the violent pains and convulsive twitchings in the limbs, associated often with severe spasms in the abdomen. These cramps and spasms, as she called them, were her constant torment, and came on, at times, in most violent paroxysms. She continued much in the same state during the three months before her death, gradually wasting, and with extensive bed sores, in spite of all preventive measures; the paralysis increased, though it was never perfect, and sensation remained unaffected. The pains in the legs and abdomen, however, never left her, and she continued thus lingering on in great suffering until the 15th of October, when she died.

Post-mortem examination.—Body extremely wasted. Thighs and legs flexed, as during life. Upon opening the spinal canal, the sheath of the cord was seen, as usual, distended with fluid, except at the upper dorsal region, where the cord itself was seen

forcibly pressed backwards by the growth of some substance beneath it. When the dura mater was slit up, a tumor was found, opposite to the third dorsal vertebra, growing from the inner surface of the membrane, and compressing the medulla against the posterior part of the spinal canal, by which it was seen flattened, and somewhat softened. The tumor was the size of a large bean, and was adherent by its anterior surface to the arachnoid of the dura mater; the adhesions were, however, but slight, and easily broken down, except at the point of its original growth, where the attachment was strong, although formed only at one small spot. The remaining part of the cord was healthy, with the exception of a few of the white cartilaginous-like plates on the arachnoid, which are not uncommon.* The flattened cord, which was compressed, contained a number of fatty granules, and granule masses; and was in no wise connected with the tumor. The tumor was of an oval shape, the size of a bean, and grew from the arachnoid surface of the dura mater. When a section was made through it, it was found to be firm, hard, of a grey colour, of a close uniform texture, and exuded little or no fluid. Some open mouths of blood-vessels were seen on the cut surface. The microscope showed it to be composed of a number of small nuclei; small, imperfectly formed nucleated fibres; and a number of simple fibre filaments. The latter appeared to run throughout its structure, and form the skeleton of the tumor. They were composed of long white bands, as seen in simple fibrous growths. The nuclei scattered between these were oval, long, and many of a not very definite shape. In no place could they be seen developing into true fibre; although imperfectly formed fibres, closely connected together, and having similar nuclei, composed a great part of the tissue. The structure was seen then to be too cellular, or nucleated, for a simple fibrous growth, while the cells were not sufficiently well formed into fibres to make it resemble a fibro-plastic, or recurrent fibroid tumor. It might, perhaps, with more propriety, be called fibro-nucleated.

The only other disease in the body was a slight inflammation of the bladder and pyelitis of the kidney, a fatty liver,

* See vol. ii. pp. 18 and 25.

and some very small commencing fibrous growths in the walls of the fundus of the uterus.

A case similar to this has not occurred in Guy's Hospital for the last six years. In the year 1849, a man died with a very similar tumor, of the exact form and size, and growing from the like part of the spinal cord.

Dr. Wilks, *6th of November*, 1855.

---

17. *Carcinomatous Growth pressing upon the Cervical part of the Spinal Cord, and producing Paraplegia.*

The preparation showed a tumor of the size of a bantam's egg, situated to the right of the cord, and external to the dura mater, which could, in most places, be detached from it; it had produced considerable absorption of the pedicle, lamina, and transverse process, on the right side of the sixth cervical vertebra. By means of its pressure, the cord was much compressed and twisted, so that the right lateral surface had almost a completely posterior aspect. The cord itself was atrophied, but not otherwise affected. The growth had produced complete obliteration of the right vertebral artery at the point of pressure. It was invested by a tolerably thick and dense fibrous covering, and was of a lightish yellow colour, and somewhat friable character.

Microscopical examination.—The minute structure of the growth was almost entirely cellular. Vast numbers of rounded, smallish, but very decidedly nucleated cells were everywhere visible, mixed with granular matter; and in many places several very large oval nucleated cells of double the size of pus corpuscles were to be seen. Here and there a complete matrix of delicate areolar tissue was apparent.

The specimen was removed from the body of a young woman, who for many months had had incomplete loss of power of motion and sensation in all the limbs, but especially those on the left side of the body; and when first treated there was also found a decided tumor at the bottom of the right side of the neck, whose nature was not made out. It seemed to become rather smaller, and less firm, under the use of counter-irritation and the

internal use of mercury, iodide of potassium, and cantharides. The mind was unaffected, as also the special senses; and the various animal functions appeared to be performed in their usual way. The deficient power of motion, and the incomplete sensation remained much the same; but extensive bed sores came on, and the patient died from the exhaustion and discharge consequent on the sores.

No other parts of the body were affected by growths similar to the one found in the spine, and no other viscus showed any decided marks of disease.

Remarks.—The points of interest in this case are,—

1. The presence of the growth on the right side of the spinal cord, whilst the limbs on the left side of the body were the most decidedly affected.

2. The carcinomatous growth being restricted to one part of the body for so long a time.

3. The presumption that the original seat of the growth, was either the bone of the spinal column, or the tissues between it and the dura mater, which could be separated from the growth wherever examined.

4. The appearances of the growth in a person so young.

Dr. J. W. Ogle, 16*th of January*, 1856.

---

18. *Tumor connected with the Spinal Cord.*

S. K. æt. 40, widow, was admitted into Elizabeth Ward, St. Thomas's Hospital, under the care of Dr. Bennett, on the 13th of August, 1855. Two years before she had been in the same ward, under Dr. B.'s care, suffering from imperfect paraplegia, which came on after her confinement, and was attended by severe pain of the back, along the course of the spine. She had previously enjoyed good health. For this attack she was under treatment three months, during which time she had always more or less pain in the back and lower limbs, with impaired motion, and but little diminution of sensation. She went out, however, at her own request, able to walk, and considering herself well, though still having some pain of the

back. She was able to attend to her domestic duties till the winter of 1854–5, when she had several attacks of uterine hæmorrhage, followed by great debility, increased pain of back, and such loss of power of the legs as to compel her to seek admission again. She then had complete paralysis of motion of the lower extremities, loss of power of the sphincters, some diminution of power of the upper extremities, and a certain degree only of loss of sensation in both upper and lower extremities. The latter, however, was variable, and sometimes scarcely appreciable. Her aspect was somewhat anæmic, but healthy, and the digestive functions were but little impaired, the appetite being good. The pulse was a little quickened, the urine, loaded with mucus, was alkaline. She complained much of pain in the back, increased by percussion of the dorsal region, and by every motion of the body. She was subsequently obliged to lie constantly on the right side, the thighs and legs permanently flexed by spasmodic action, and the excito-motory actions were sometimes very severe and distressing. She complained also throughout of a sense of constriction across the waist, and of pain under the left mamma. The urine became loaded with pus, was frequently passed, or constantly dribbled away. The bowels were never much constipated. Extensive sloughs formed on the back and right hip. The lungs became loaded with muco-puriform secretion, occasioning much troublesome cough; but the breathing was never very laboured, and frequently, even towards the end, natural. Eventually, the digestive powers, which, for a long time, were remarkably well maintained, gave way. She had severe rigors, colliquative sweats and purging, with irritability of stomach. Her sufferings became very great, and the sloughs fearfully extensive and deep; neither the water bed, nor double inclined plane, nor any other device, enabling her to rest in any other than the one position on the right side, with the thighs flexed on the trunk; but there was never the least impairment of the intellectual functions.

Post-mortem examination. — Considerable amount of fat beneath the integuments throughout. A large bed sore over the right hip and buttock, by which the gluteus maximus was,

in great measure, destroyed; and the origins of the triceps, and semi-tendinosus, and membranosus, were bared, as though they had been dissected. The great trochanter, and a portion of the os sacrum, and tuberosity of the ischium, were exposed. Smaller bed sores existed on the sides of the knees and ankles. The lungs and cavity of the chest were healthy, except that the bronchial tubes were everywhere loaded with muco-puriform matter, and that a portion of the middle lobe of the right lung was collapsed and airless; and the smaller bronchial tubes being loaded with puriform matter, when cut across presented the appearance of tubercular deposits. The bronchial tubes leading to this portion of the lung were especially loaded. *The abdominal contents* were perfectly healthy, with the exception of the bladder, the mucous membrane of which was highly congested, and roughened, here and there, from the deposit of lymph. It contained a moderate quantity of thick puriform secretions. *The brain* and its membranes were perfectly healthy. On examining the *spinal cord*, a tumor was found at the commencement of the dorsal region, between the cord and its theca. It measured about an inch in length, and one-third of an inch in thickness. It was situated to the right side, and partially surrounded the cord, extending from the left of the median fissure in front, nearly as far as the median fissure behind. It seemed to have originated between the origins of the anterior and posterior nerves, as these were stretched over its surface, and displaced by it. It was slightly adherent to the theca vertebralis, but a very little dissection served to detach it. The visceral arachnoid could be traced into its surface all round, but was not separable from it. The tumor was adherent to the cord by its deep surface, and evidently compressed it, but it appeared to have originated in the sub-arachnoid tissue. It was irregularly round, and somewhat tuberculated, here and there, on its surface. It had, for the most part, a whitish glistening aspect, but, in some parts, was darker coloured. Distinct fluctuation was to be detected in certain places. On section, the tumor was found to be a cyst, with walls of various thickness, and the cavity constituted about one half of the tumor. The parietes,

about a line and a half in thickness, were whitish, soft, and elastic; and although, at first sight, homogeneous, on a minute examination presented indistinct traces of a lobulated arrangement. The outer surface was formed by a thin, but firm fibrous membrane, which was inseparable from the tissue beneath. The internal surface of the parietes was irregular and tuberculated, with nodules projecting into the cavity of the cyst. It was lined by soft, somewhat translucent layers, admitting of being readily pulled off. The cavity of the cyst was crossed by numerous bands, and groups of soft, translucent, but elastic membranes, which were continuous with the soft layer lining the cyst; most were colourless, some much injected, and others blackened. The fluid in the cyst was limpid and nearly transparent, but of a greenish brown hue, and this being visible through the thinner parietes, appeared to have given the dark hue to certain portions of the outer surface of the tumor.

Microscopical examination of tumor of spinal cord. — The external investing membrane of the tumor presented numerous elastic fibres, mixed with interlacing trabeculæ of white fibrous tissue. The substance of the walls presented an indistinct fibrous structure, thickly studded with large oval nuclei, the fibres and the nuclei taking the same direction. The arrangement of these structures was definite and parallel, and, for the most part, concentric; so that the substance of the walls appeared to consist of a number of lobules of various sizes, united to one another by curved and branching bundles of fibres of similar character. The nuclei were generally most abundant in the centre of those lobules, and occasionally in the bundles of fibres that separated contiguous ones, and which looked as though they were compressed, the nuclei were sometimes indistinct or absent. Numerous blood-vessels were detected, the parietes of some of which were studded with orange-coloured concretions. The soft lining membrane of the cavity, and the bands and septa crossing it, presented an indistinct fibrillated arrangement, with indistinct traces of nuclei; but they contained a large number of blood-vessels, with distinct walls, which were generally studded with orange-

or ruby-coloured concretions, single and clustered, and of considerable size, but no blood-crystals. In many situations, these were deposited in abundance, irregularly, and apparently in the substance of the tissues—not simply along the course of the vessels. The fluid contained in the cyst, presented numerous blood corpuscles, the majority of which had a very peculiar appearance. The size and colour were those of healthy corpuscles, but they were very irregularly shaped,—most of them had the shape of a starfish, sending off radii from three or four, to five, or six, or seven, of considerable length. Crystals of triple phosphate were detected in the lining membrane of the cyst in some quantity.

Dr. Risdon Bennett, *5th of February*, 1856.

II.—DISEASES, ETC. OF THE ORGANS OF RESPIRATION.

1. *Cancerous Ulceration of the Mamma, which perforated the walls of the Chest, so as to form a free opening into the Cavity of the Pleura.*

F. T. æt. 53, was admitted, 10th of July, 1855, into one of the Cancer Wards of the Middlesex Hospital, with carcinomatous ulceration of the right mamma. The disease began in a scirrhous tumor six years ago. In three years the skin had ulcerated and the glands in the axilla become indurated. Subsequently, the skin, for some distance around the mamma, became condensed, adherent to the parts beneath, studded with cancerous nodules, and the fat of the breast was removed by absorption. More recently the disease extended to the left side, that mamma becoming flattened, hard tumors forming within it, with nodules in the adjacent skin, and induration of the glands in the axilla.

The ulceration on the right side, attended with occasional superficial sloughing, advanced with various degrees of rapidity till the whole sore attained a large size; reaching, in a longitudinal direction, from over the clavicle, where a tumor

threatened to cause compression of the trachea, to near the lower margin of the ribs; and in a transverse direction, from the line of the sternal cartilages to beyond the posterior border of the axilla. Four months before her death, when the ulcer had reached to nearly its largest extent, she had an attack of erysipelas; it was observed that when she recovered from that, the ulceration ceased, and cicatrization went steadily on during two months, so that the greatest part of the surface was covered over with a thin film of skin. After that period the disease resumed its activity; and six weeks before her death a thick slough had formed at the lower part of the sore, over the fourth and fifth ribs, near their junction with the cartilages. Upon that slough being detached, a direct opening was formed, by the destruction of the parts, into the cavity of the pleura; the size of the orifice being about four inches transversely, and two inches and a half longitudinally. A portion of the fifth rib, not less than two inches and a half in length, had been removed; but its presence was not detected in the slough, either by the patient or attendants; and its mode of removal is therefore uncertain. The lower edge of the fourth rib had been partially ulcerated. On looking into the opening in the thorax an extensive cavern was seen, of which the lateral boundaries did not come into view; but at the bottom of the cavity, which was from three to four inches from the level of the orifice, the partially collapsed lung was visible, having its pleura thickened and a small cancerous nodule projecting from one spot. It was observed that, in the motions of respiration, the part of the lung within view was depressed, so as to be almost hid, during inspiration, and was elevated during expiration: appearances to be accounted for by supposing that the lung was connected to the diaphragm by adhesion, and that it was dragged downwards during the descent of that muscle in inspiration, and was pushed up again when the muscle rose in expiration. An offensively fœtid matter like pus continued to be discharged in considerable quantity from the cavity until the time of her death. Her breathing, which, owing to the extensive destruction of the structures in front of the chest, had been difficult previous to the perforation, was not made perceptibly worse

after that occurred, and she lingered on for a month, her death taking place on the 26th of February, 1856.

Post-mortem examination.—Neither in the right lung nor pleura were there any cancerous deposits. Adhesion between the pleura costalis and pleura pulmonalis had taken place at a short distance from the lower margin of the opening in the parietes; but in other directions there was a considerable space, varying from two to five inches from the margins when these membranes did not adhere; and it was estimated that the circumscribed cavity in the pleural sac, with which the external opening communicated, might have held, if filled with fluid, nearly two pints. There were also other adhesions between this lung and the parietes. In the left lung there were extensive emphysema, and adhesions at the apex. The pleura pulmonalis was of a grey colour and marked by numerous small white nodules or patches, like split peas, of a firm consistence, confined to the membrane. There were no other traces of cancer in any of the organs of the body.

Mr. SHAW, *4th of March*, 1856.

---

2. *Malignant Disease in the Anterior Mediastinum and in other organs.*

A. B. æt. 16, an engineer, had had good health until one month before his admission into St. Thomas's Hospital, on the 27th of November, 1855.

He described symptoms at the commencement of his illness, about a month before admission, which led to a suspicion that he had then had an attack of pleurisy, since which time he had had gradually increasing dyspnœa. When first seen he had all the symptoms which might be expected in very extensive effusion into the right pleura, the only peculiarity being that the dulness on percussion extended completely to the left of the sternum. He obtained some relief from counter-irritation and the use of diuretics; but on the morning of the 3rd of December he was found comatose, and died an hour afterwards.

Post-mortem.—The sternum was firmly attached to a growth occupying the anterior mediastinum. Superficially this growth

was irregular and lobulated; it extended, in the mesial line, from the upper part of the sternum to about an inch below the xiphoid cartilage; and, in the greater part of its length it extended laterally from the junction of the ribs and cartilages on the left side, to beyond the same points on the right. It was somewhat unequally divided into two portions; the upper, which extended as far as the fifth rib, was irregularly globular, forming a solid tumor, and extending as far back as the spine. The lower portion, which was separated from this by an imperfect constriction, had considerably less depth, but of much greater lateral extent, and reached rather more to the left than to the right side, being attached to the whole anterior surface of the pericardium.

The right pleura contained two pints and a half of reddish, very turbid fluid. The left was healthy.

The pericardium contained two or three ounces of fluid. The surface of each layer was thickened, roughened, and of a more or less opaque white appearance.

The surface of the right pleura was thick and opaque, like that of the pericardium.

The right lung was small, collapsed, wrinkled on its surface, and enveloped in opaque membrane, which was thickly studded with little nodulated white masses. On section, the lung tissue was found collapsed and airless.

The liver was attached to the diaphragm by adhesions. It was healthy; but was pressed downwards almost as low as the umbilicus.

The kidneys were very large, measuring six inches and a half in their long diameter, and their other dimensions were proportionate. One weighed twenty-one ounces and a half, the other twenty-three ounces.

On section, the whole cortical substance appeared to be infiltrated with a soft, white, brain-like material. In some parts this had entirely replaced the cortical substance, and appeared to form distinct growths, which, however, were blended with the neighbouring disease. Throughout the greater part of the organ the remains of the cortical substance were apparent, though marked and infiltrated by malignant growth. The medullary substance was, for the most part, healthy, and so

also was the lining membrane. The capsule very much thickened, was but very slightly adherent to the surface. A great number of the mesenteric glands were enlarged, varying from the size of a filbert downwards. They were pale, solid, and formed of a whitish, creamy, juice yielding material.

Dr. BARKER, *4th of December*, 1855.

---

3. *Intra-thoracic Cancer.*

E. R. æt. 40, married, a small spare woman of healthy aspect, was admitted into St. Thomas's Hospital, under the care of Dr. Bennett, on the 25th of March, 1856. She stated that she had always enjoyed good health till the beginning of the present illness; and particularly that she had never suffered from rheumatism in any form. About three months ago she first experienced difficulty of breathing, which had gradually increased, attended by a sense of constriction across the upper part of the sternum; and of some obstructing cause situated behind the trachea, interfering greatly with her swallowing. There was neither lividity nor swelling of the features, nor anything indicative of much pulmonary obstruction, although the coloration was rather deeper than usual. The breathing, however, was forced and heaving, and accompanied by loud and prolonged stridor. The voice was unaltered, and she spoke without any difficulty. She appeared to suffer much from the pain and constriction referred to the upper part of the sternum, although the face was not expressive of great anxiety. The dysphagia was such that she would not attempt to take anything but liquids, which she swallowed with difficulty. There was nothing abnormal observed in the external conformation of the thorax; nor any particular nervous turgescence. There was complete dulness, on percussion, over the whole left antero-superior region of the chest, extending across to the right of the sternum. Posteriorly the dulness, though not so great, extended to below the angle of the scapula. The tracheal stridor interfered greatly with any examination of the respiratory sounds; but, from time to time, during the temporary subsidence of the stridor, the respiratory murmur, although feeble,

could be heard over the whole right side, mixed, posteriorly, with mucous crepitation, especially towards the base of the lung. Over the whole of the right side, except towards the base of the lung, there was fair natural resonance on percussion; but scarcely any respiratory sounds could be heard on the left side; and what was heard was faint, distant, and bronchial. Pain and tenderness were complained of, on percussion, over the upper part of the sternum. There was a certain amount of cough, attended by grey frothy mucous expectoration. The action of the heart was irregular and occasionally intermitting, but free from bruit; its impulse was great. The sphere of cardiac dulness was apparently much enlarged; but, as the pulmonary dulness extended to the cardiac region, it was difficult to say whether it was referable to the heart or the lungs. The right radial pulse was stronger and fuller than the left; and both were irregular. The temperature was natural, and there was not the least indication of febrile disturbance, nor of disease elsewhere than in the chest.

Such was the condition on her entrance into the Hospital. Subsequently the dulness of the left posterior region of the thorax increased, with entire absence of all respiratory sounds, and of all vocal thrill. The dyspnœa increased with paroxismal exacerbations of great distress. She lay frequently on the face, which posture appeared to give some relief, both to the dyspnœa and to the pain referred to the top of the sternum. The action of the heart continued forcible, and the dysphagia became extreme. The pulse, especially on the left side, was exceedingly feeble, and little or no pulsation could be detected in the large vessels of the neck. Slight temporary relief was afforded by a small cupping, by anti-spasmodics, and by morphia. She died on the 2nd of April, after prolonged and extreme agony and struggling for breath.

Post-mortem examination.—The left pleura contained a quart of clear serum. The left lung was very much reduced in size; the upper lobe being pale and œdematous to an extraordinary degree, but crepitant throughout. Its bronchial tubes were pale, and filled with casts of transparent, colourless, jelly-like mucus. The lower lobe was crepitant throughout its greater

part, but much less œdematous than the upper. The tissue retained its natural tenacity, and, on squeezing it, a considerable quantity of frothy, but morbid, puriform fluid escaped. The contents of the bronchial tubes were semi-fluid, opaque, and puriform. The lung, towards its root, was adherent to a malignant tumor situated in the mediastinum; and the whole of the inner surface of the lower lobe was similarly attached. A layer of dense fibroid tissue was prolonged from the tumor a little way over the surface of the lung. The right lung and right pleura were perfectly healthy. Pericardium healthy. The heart appeared rather larger than natural; but the ventricles were distended with partially coagulated blood, and the walls were thin. The valves were healthy. In the upper part of the anterior mediastinum, and corresponding to the position of the manubrium of the sternum, a somewhat lobulated growth was detected, which proved to be a portion of a malignant tumor, nearly as large as an ostrich's egg, seated chiefly in the posterior mediastinum, in the position of the root of the lungs. The mass was somewhat irregular in shape, and lobulated on the surface. It extended from the origin of the great arteries of the neck above, to the diaphragm below; and, laterally, from one lung to the other: the root of the left being much more involved than that of the right. The greater bulk of the growth was situated in the upper half of the mediastinum, behind the ascending arch. It completely surrounded the transverse arch, and the origins of the left common carotid and subclavian arteries, without, however, causing their obstruction. The right branch of the pulmonary artery was free; but the left was completely surrounded by the tumor, and its calibre greatly reduced. The trachea was pushed to the right side, and its lower part surrounded by the growth, excepting on the right side. The right bronchus was free; the left enveloped by the tumor, and its sides so compressed together as to be virtually obliterated. The descending arch and the thoracic aorta, in its whole length, were completely invested by the tumor. The right pneumogastric nerve and its recurrent branch, were not interfered with; but it was evident that the left was involved, and probably destroyed, though it was not traced through the

tumor. The diseased mass was moulded on the anterior and left two-thirds of the thoracic vertebræ. On section the tumor was found to consist, for the most part, of a whitish, slightly translucent, and glistening material, yielding, on pressure, a creamy juice. It was abundantly studded, here and there, with a net work of opaque buff-coloured streaks and spots; and presented, at some points, extravasations of blood, and in others, blackish masses, apparently indicating its origin in the bronchial glands. The mass was prolonged, in an irregular lobulated form, for some distance into the substance of the left lung.

The liver, spleen, intestines, pancreas, kidneys, and peritoneum were all healthy, In the left ovary was a malignant tumor about the size of a marble; and in the right a cyst as large as a hen's egg filled with transparent fluid; and its lining membrane studded with small warty growths.

Dr. J. Risdon Bennett, *15th of April*, 1856.

---

4. *Malformed Trachea and Œsophagus: Congenital Communication between them.**

The specimen showed complete obliteration of a portion of the œsophagus, at about one inch from its pharyngeal opening, the upper part being very dilated. Below the obliterated part there was an opening at the anterior surface of the œsophagus, which directly communicated with the larynx, at a point about a quarter of an inch above the bifurcation of the latter into the bronchi, and hence the stomach and œsophagus were only continuous with the mouth by means of the glottis. This opening was valvular in form, the posterior part of the trachea above the opening being continuous with the posterior part of the œsophagus, which was patent below the communication; whilst the anterior part of the œsophagus was continuous with the lower, or crescentic lip of the opening. No other malformation was noticed.

The preparation was removed from the body of an infant, who only lived to the fourth day. The child was of healthy appearance when born, and sucked at the breast

* For the report of a like case, see vol. iii. p. 91.

vigorously; but it seemed that most, if not all the milk, returned through the nares. It became convulsed before death, and appeared to die without suffering pain.

It is probable that some slight amount of milk found its way by the trachea, and thence into the œsophagus, as the child lived so long, but this was evidently only in spite of the laryngismus, which its passage through the glottis caused, and was totally insufficient to support life.

Dr. J. W. Ogle, 16*th of January*, 1856.

---

5. *Ulceration of the Larynx in reference to Local Applications.*

The specimen presented had been taken from a female who died in the Brompton Hospital of phthisis, presenting the usual symptoms of tuberculous laryngitis. The parts were only interesting as showing that very extensive and severe disease need not necessarily extend beyond the reach of local applications. The ulceration, it could be seen, had partially destroyed the epiglottis, was very distinct around the glottis, and, entering the larynx, had almost destroyed one of the cordæ vocales, and injured the other. Yet lower than these last named points there was not a trace of mischief. Dr. Quain said that, in such a case, if nitrate of silver or any other local application were capable of being useful, there could be no doubt whatever but that they might be directly applied in the form suggested by Dr. Horace Green,—that is by a properly made sponge probang. It was not, however, in such advanced cases that benefit resulted from either local or any other treatment. It was a delusion to suppose that lost textures could be restored. Still in simple chronic laryngitis, in the earlier stages of the tuberculous form, in a congested, villous, or so called relaxed state, and in certain irritable conditions of these parts, such as in the sore throats of clergymen, he believed local applications to be invaluable. It needed, however, great care and some discrimination in practice. In reference to passing the sponge within the trachea, Dr. Quain doubted the possibility of doing so in a vast number of cases: still he did believe that, in some few cases in which the glottis was large and not so sensitive as in other cases, and

the sponge small, it can and does pass beyond the cordæ vocales. This conclusion he had come to from several observations on the living, and experiments on the dead body.

Dr. QUAIN, 15*th of January*, 1856.

---

6. *Fibrinous Cast expectorated in a case of Hæmoptysis.*

This specimen of fibrinous cast was expectorated by a middle aged gentleman, a patient of Dr. Peacock's, who had long suffered from attacks of spasmodic asthma, and had recently had symptoms threatening the occurrence of phthisis. The expulsion of the clot was preceded and followed by the escape of a small quantity of blood; and the mass, when first expectorated, had a deep red colour. The portion of the lung, in the bronchial tubes of which it had probably been moulded, was the left apex, that situation being indicated as the seat of the disease by a slight degree of dulness on percussion, both anteriorly and posteriorly, and some rhonchus heard on forced inspiration. The cast was altogether about three inches in length. (Fig. 2.) At one extremity it consisted of several loose membra-

FIG. 2.

Cast of Bronchial Tubes.

nous fragments, while towards the other end it gradually diminished in size, and terminated in three small branches. It

has two or three small projections from the sides: where thickest it was about two lines in width. When exhibited to the Society the outer surface had been blanched by maceration in water; but the interior was still of a deep red colour, and one of the branches cut across was found to be a hollow cylinder containing blood. From the peculiar knotted or jointed appearance of parts of the mass, it probably was hollow in places, with the cavities similarly occupied by blood. A portion of the specimen was examined by Dr. Bristowe, and found to consist of an irregular network of delicate interlacing fibres; of blood corpuscles in great abundance; of corpuscles, as represented in the accompanying drawing (Fig. 3.), which,

Fig. 3.



Corpuscles from the Cast. Magnified 420 diameters.

when acted upon by acetic acid, had "the cell wall rendered very transparent, while the nuclei were unaffected. They appeared to be neither the white corpuscles of blood nor pus." Dr. Bristowe inferred that the mass consisted of blood and an inflammatory fibrinous exudation; and suggested that it "might probably be the result of inflammation of the lung, in the way which he described in the last volume of the 'Transactions.'"

In vol. v. of the "Transactions" (1853–4, page 43), Dr. Peacock reported on a case of fibrinous sputum, or so-called *bronchial polypus*, exhibited to the Society by Dr. Fuller. In this report he entered into an analysis of a large number of published cases of the kind; and was led to agree with Dr. Watson in the opinion that the masses of solid fibrine expectorated,

whether coloured or not, and whether their expulsion was attended with hæmoptysis or otherwise, were probably all the result of some degree of inflammatory action. This view was in opposition to that of Michaelis, adopted by Dr. Cheyne, that the masses were of two distinct descriptions; one a fibrinous inflammatory cast, the other a moulded blood coagulum. Dr. Peacock supposed that the escape of blood, when it occurred in cases of this kind, was due either to the intensity of the inflammatory action in the part, by which not only the plasma, but also the blood-globules were effused; or to the rupture of blood vessels in the separation of the cast from the mucous membrane of the moulding bronchial tubes; or to congestion of the lung tissue in the seat of the disease.

The specimen exhibited Dr. Peacock regarded as confirming the views of Dr. Watson. From the appearance of the mass when first expectorated, and from the attendant hæmoptysis, the case was precisely one of those which would ordinarily be regarded as affording an example of a moulded coagulum; but careful examination by the naked eye, confirmed by Dr. Bristowe's investigation, showed that it was, in part, the result of an exudation from an inflamed surface. Whether this surface was that of the mucous membrane of the tube in which the cast was moulded, or, as suggested by Dr. Bristowe, of the lung tissue itself, it was impossible to decide.

The expulsation of the fibrinous mass exhibited to the Society by Dr. Fuller was unattended by hæmoptysis; and this also did not occur in the case under the care of Dr. Peacock, from which various specimens of casts expectorated were shown during last session. A fuller report of the last case was given by Dr. Peacock in a paper on plastic bronchitis, in the "Medical Times and Gazette," 1854; p. 658.

Dr. Peacock, *15th of January*, 1856.

---

7. *Fibrinous Casts of the Bronchial Tubes.**

I was consulted, 1st of September, 1831, by Mrs. C. æt. 33,

* *See* Dr. Peacock's Memoir on Bronchial Polypi, in vol. v. of the "Pathological Transactions," p. 63, where this case is referred to.

residing at Walworth, married, and without children. "She states that she has been in ill health for six or seven years. Four years since she had chancre, followed by nodes, sore throat, pains in the bones, &c. and at the time of examination she had rupia on the scalp. Had had inflammation of the chest four or five times, for which she was frequently bled from the arm. Had consulted a great many medical men, and was some weeks in Guy's Hospital. Complains now of great difficulty of breathing, amounting, at times, almost to suffocation; lips and cheeks of a livid appearance; pain in the epigastrium increased on pressure. About ten days since she expectorated a white stringy substance, which she supposed was a worm: when it passed the glottis she was nearly suffocated, and believes she would have died if she had not pulled it out of the throat with her finger and thumb. Since this period she has expectorated many fibrinous casts of a white nerve-like appearance; they are of the form of the bronchial tubes; the main trunks vary in diameter from one line to half a line, and the lateral branches, in number, from ten to eighteen; some of these are very minute, as in the preparation exhibited." Respiration is puerile in the upper part of the left lung, and indistinct in the inferior portion. Sonorous râle over nearly every part of the right lung. I considered the case as hopeless, and adopted a soothing treatment; opium, ipecacuanha and ether, affording the most relief. She died on the 9th of November following, and on examination of the body, the day after, about four ounces of serum were found in the pericardium; the right lung was studded with miliary tubercles, and three soft tubercles of the size of a horse-bean were also present. The inferior portion of the left lung was hepatized, and many of the bronchi were lined with false membrane, resembling that which had been expectorated during life. The liver was rather large; the other viscera apparently normal. Dr. Crisp, *15th of April*, 1856.

---

8. *The Lungs of Four Children who died from Hooping-cough.*

The specimens consisted of the lungs of four children, and were illustrative of the lesions which the author believed to

exist in almost all cases of this disease. They all exhibit one peculiar lesion to a greater or less degree: that is, the lungs will be found to present, in certain portions of them, that condition formerly known as *lobular pneumonia;* but which is now known to be collapse of the lung substance, without, necessarily, inflammation of the lung itself. In the nineteen cases to which an essay* published by the author relates, collapse of the lung was, in very nearly all the cases, found, together with other lesions more or less intimately related to it.

Much interest attaches to the fact that these observations demonstrate the almost universal occurrence of one particular lesion in all fatal cases, *viz.*:—collapse of the lungs, identical with "lobular pneumonia," "atelectasis," "fœtal condition," "apneumatosis," &c. of former writers, and is a condition coincident with, and, in all probability, produced by, capillary or catarrhal bronchitis in children, and perhaps in adults. Hooping-cough is usually attended with bronchitis of this character; and when the disease is fatal, pulmonary collapse will almost always be found. The author does not enter on the question of how far pulmonary collapse is peculiar to hooping-cough as compared with what is found to be the case in other diseases also attended with bronchitis in children. The lungs have presented the same condition in other diseases of the respiratory organs, such as measles, &c.: and, indeed, those who first demonstrated that lobular pneumonia so called, is not pneumonia at all (M.M. Legendre and Bailly), demonstrated it in reference to capillary bronchitis generally. It will be thus seen that, though pulmonary collapse is a lesion not peculiar to hooping-cough, still its almost universal occurrence must be an important element in the disease. It will also be perceived that the existence of pulmonary collapse in pure simple cases of hooping-cough is not necessarily implied: what the author contends for is this, that the patients die by, and through, the existence of it. Few opportunities of further prosecuting researches on this interesting subject since the spring of last year have presented themselves; but recently the disease has become more prevalent,

* "On the Pathology of Hooping-cough," by Graily Hewitt, M.D. London: Churchill, 1855.

and the lungs exhibited have been removed from children who have died of hooping-cough within the last few days. An examination of them has confirmed the author's views; and the following are a few particulars of these cases :—

Case 1. — *Hooping-cough, Collapse of Lungs, Sub-pleural Ecchymosis, Catarrhal or Vesicular Pneumonia.**—J. D. æt. sixteen months; has been in the nursery of St. Marylebone Workhouse for six months. Suckled by mother. The child has, until lately, been of a lively, active, disposition, and healthy, though never fat. For the last three weeks before death had a cough, which, at first slight, became soon paroxysmal in its character. For fourteen days before death, the cough became more frequent, and the condition of the child rapidly altered for the worse. During the night the cough was very troublesome, and the patient was very hot and feverish. The last two days the cough almost ceased, and during the last twenty-four hours the child was in convulsions. It died on the 28th of February, 1856. Although this patient had never hooped, yet the nature of the cough, and the existence of hooping-cough in the nursery, left no room for doubt that that disease existed in this case.

Post-mortem examination.—Thorax apparently the usual size. The line of junction between the costal cartilages and the ribs, is, to the eye, well marked, and the cartilages are slightly bent inwards, especially those of the third, fourth, and fifth ribs on each side. The lungs were about half an inch apart at the upper part of the anterior mediastinum.

Right lung. Upper lobe very emphysematous at the anterior border, and of a pale rose colour. Some of the air cells as large as a pin's head. Middle lobe collapsed, of a rather deep red colour, flaccid, and thin. Scattered over the surface of this lobe, are minute, elevated patches, of a yellow colour; these are dilated extremities of bronchi containing muco-pus (bronchial abscesses). One portion of this lobe, about an inch

* By this is meant inflammation occupying the extremities of the air tubes and the air vesicles themselves. *See* Legendre and Bailly, in "Archiv. Medic."

square of its margin, is excessively thin, and reduced to almost the thinness of a membrane.

The posterior surface of the upper and lower lobes, is of a deep violet colour, with small spots of sub-pleural ecchymosis: these violet coloured portions are apparently composed of collapsed lung congested with blood; for the lung substance beneath does not crepitate on pressure. These lungs have not, however, been meddled with at all since their removal from the body, in order to preserve the characteristic appearances.

Left lung. Anterior border of upper lobe and tongue-like prolongations collapsed, as are also, in a partial degree, portions of the remainder of the lobe, as seen by its pitted appearance. The posterior surface of the upper lobe, as well as that of the lower, is identical in character with the corresponding portions of the upper and lower lobes of the right lung. The emphysema of the upper lobe is especially marked, together with the line of demarcation between the aerated and non-aerated portions of the lobe.

The larynx was perfectly healthy.

Bronchial glands rather large and congested.

The pericardium contained three drachms of serosity. The heart was rather large; its right cavities only contained blood.

The liver presented nothing abnormal. The gall-bladder was peculiar, in the fact that it contained bile almost transparent, and but slightly tinged with biliary colouring matter.

The sigmoid flexure distended to a great size with gas. Intestines otherwise healthy externally.

Brain. No fluid in ventricles or arachnoid. Slight engorgement of the veins of the choroid plexus. Brain substance soft, but not perhaps more than is usually the case in young children.

Case 2.—*Hooping-cough, Collapse of Lungs, Catarrhal Pneumonia, slight Tubercular Deposition.*—W. S. æt. twelve months. This child was attacked in the nursery of the St. Marylebone Workhouse with hooping-cough one month before its death. The last two weeks of its life had been passed in the infirmary of

the Workhouse. It was not suckled by the mother. The cough was unaccompanied by a hoop, but came on in violent paroxysms, and great heat of skin was noticed generally in the evening. When removed to the infirmary the child was very ill. The cough was not followed by sickness. The last three days diarrhœa was noticed, and three hours before death convulsions came on.

Death took place on the 29th of February, 1856.

Post-mortem examination.—Body emaciated, no flattening of costal cartilages noticeable.

Left lung not adherent to ribs; swims in water, the lower portions of it being below the surface, and the upper portion of the upper lobe being evidently the part which prevents it from sinking. A large portion of the lung is collapsed.

The upper lobe is composed, for more than half its bulk, of lung tissue, in an excessively emphysematous condition; that is to say, over the whole of this portion the air cells on the surface are much enlarged, and very visible to the naked eye. With a common lens the enlargement of the air cells is still more apparent, and it is then further seen that their size varies considerably. The anterior tongue-like prolongation of this lobe is entirely collapsed, as is also a small width of the anterior margin higher up. Along the margin, the differences in the physical characters of the emphysematous and collapsed portions is most marked; the collapsed portions being flaccid, thin, of a dark colour, depressed, and evidently almost entirely destitute of air; whereas the emphysematous portion with which it is immediately in contact, and from which it is separated by a very abrupt line, is elevated, puffed out, of a very light rose colour, and quite full of air. The emphysematous portion is crossed by a sinuous depressed line, marking the situation of a portion of lung not participating in the emphysematous state, but, on the contrary, collapsed.

This lobe was not inflated by the blow pipe, in order to preserve the morbid state intact.

With respect to the collapsed portion of the upper lobe, there is something further to add. Towards the termination

of the anterior tongue-like process, the collapsed lung presents at intervals small yellowish elevated spots. These are scattered irregularly over the surface, and are, as a rule, about the size of a lentil seed. When a sharp knife is drawn across the surface of the lung corresponding to these little eminences, a little puriform fluid exudes, and the eminence disappears. They are, therefore, cavities of minute capacity, in all probability, indeed almost certainly, the dilated extremities of bronchi. Section of these collapsed portions reveals the existence of seed-like bodies in the tissue of the lung. These have a pseudo-granular feel, and seem to be composed of inspissated muco-pus, judging from the appearance of their contents under the microscope. The presence of a few exudation corpuscles(?) would seem to show that something more than mere bronchitis existed here, and I should infer that their presence is due to the existence of that inflammatory softening by which the minute bronchial abscesses, also called vacuoles, are produced.

The lower lobe was, when removed from the body, in great part collapsed, but it has been partially inflated artificially. The collapsed portions presented, on section, the pseudo-granular appearances observed in the upper lobe: the microscopical characters were also similar.

The bronchial tubes in this lung were not injected, nor was there anything remarkable in the appearance of the longitudinal fibres. The muco-pus contained in them, seemed to be more abundant in the tertiary and quaternary divisions, than in the main bronchus or the primary and secondary divisions.

Right lung. The upper lobe presents a beautiful example of emphysema, over nearly the whole of the external surface. A small portion of its anterior border is at two round, well defined spots, collapsed. The middle lobe was quite collapsed when removed from the body, flaccid, and thin. It was inflated, and now resembles the healthy condition of the lung in its physical and other characters. With respect to the lower lobe, it is partially covered with a fibrinous deposit of rather recent date. A strip of the lobe is of a deep violet

colour, and, on section, this portion is hard, indurated in places, and contains a deposit. This deposit appears to consist of a semi-transparent tubercle, both to the naked eye and to the eye assisted by the microscope. This deposit exists in the form of small masses, in the centre of some of which, softening has begun. At the posterior part of the surface of this lobe is a small cavity of about the size of a pea, containing a yellow creamy substance, which, under the microscope, is seen to be composed of a finely granular matter, with a few small cells of irregular form. It would appear as if a portion of the lobe had been first collapsed, and that, secondarily, tuberculous matter had been deposited at that locality. It must be distinctly understood that the microscopical characters of the contents of the tuberculous cavity in the lower right lobe and the contents of the cavities in the collapsed portions of the upper left lobe, differed *in toto*,—the one was finely granular, the other consisted of nearly uniformly shaped cells, of a tolerably large size.

The portions of the lower right lobe, which were not collapsed, were, especially at that part of the lobe adjacent to the middle one, very emphysematous.

Bronchial glands presented nothing more than simple slight enlargement.

Larynx healthy. There was nothing remarkable in the other organs.

Brain not examined.

Case 3.—*Hooping-cough, Slight Collapse of Lungs, Double Pleurisy and Catarrhal Pneumonia (?), Inflammation and Ulceration of Peyerian and Solitary Glands of Intestine.*—M. M. æt. eleven months, was taken ill in the nursery of the Workhouse. The symptoms consisted of violent fits of coughing, generally followed by sickness; feverishness during the evening, and rapid wasting of flesh. Died in the Infirmary, the 2nd of March, 1856, after an illness of fourteen days. No hoop was observed, although the disease was undoubtedly hooping-cough. The child had always been suckled by the mother. The last twenty-four hours convulsions were noticed.

Post-mortem examination.—Body not much emaciated; rose coloured spots in the folds of skin. Percussion of the right side of chest in front much too dull.

Bronchial glands large, congested; one about as large as a nut pressing on left recurrent nerve beneath the bend of the aorta.

Right lung firmly adherent to ribs by thick false membrane. Upper lobe slight partial emphysema. Lower margin and anterior part in a carnified state; section, however, of these parts smooth, and pus exudes on rather strong pressure, apparently coming from bronchi. The lower lobe presented a similar condition at its lower margin for the depth of an inch. These carnified* portions contained also much blood. They were not inflated by blow-pipe, and the tubes contained much muco-pus. The middle lobe was simply collapsed, being inflatable.

The left lung, slight collapse of anterior margin of upper lobe as also of its tongue; this lobe is partially emphysematous. The lower lobe of this lung is covered by false membrane at the posterior aspect. Its lower margin is carnified, sinking in water, firm, not inflatable; section smooth; much muco-pus in bronchi. At one spot the surface of this lobe is white, a condition found to be due to the existence of a mass of whitish firm consistence the size of a pea, situated immediately beneath the pleura. It is apparently tubercle.

Larynx healthy.

Pericardium contains half an ounce of fluid. Right side of heart contains a large fibrinous colourless clot.

Liver situated very low down; three inches below false ribs. Right lobe reaches to iliac fossa: size of liver large. Gall-bladder contains small quantity of bile.

Small intestines. Slight spots of redness noticed outside. On cutting into the ileum the Peyerian patches are found to be very much congested and distinct. A softening process is pre-

* The term carnified is here used to express an intensely marked condition of congestion, with collapse of the lung substance. It differed, however, from true hepatisation. There was, probably, in addition, inflammation of the air cells (vesicular pneumonia).

sent in some of them, and minute ulcers are visible with a lens. The solitary glands are likewise affected.

Mesenteric glands contain no tubercle.

Case 4. *Hooping-cough, Collapse of Lungs, Peculiar Perforation of the Œsophagus by Gastric Fluid, and subsequent Erosion of Left Lung.*—E. C. æt. fourteen months. Has been ill six weeks altogether. The last month the child and its mother have been inmates of the Workhouse nursery. The child was, before its illness, fat and healthy. The child has had hooping-cough, the symptoms of which have been pretty nearly identical with those observed in the other three cases. The skin was very cold the last three or four days of life, during which diarrhœa took place. Convulsions set in twenty-four hours before death.

Post-mortem examination, 4th of March, 1856.—Body much emaciated, of a rather dusky colour, slight depression of the cartilages.

Right lung. Slight emphysema of upper lobe; patches of the lobe in collapsed condition. Middle lobe adherent to upper, collapsed in great part, and its external surface studded with little yellow elevations, the dilated terminations of bronchial tubes. Lower margin of lower lobe collapsed.

Left lung. At the back part of the upper lobe and the adjacent surface of the lower lobe, there is a space of three inches, in vertical diameter, by three-quarters of an inch transversely; of a dirty brown colour, giving, at first sight, almost the appearance of gangrene of the lung. The surface is sharply defined, slightly depressed; when scraped, minute air bubbles are removed, and, when squeezed, blood exudes from the free surface. On examination, it was found that there was an oval opening an inch in length at the left side of the œsophagus, through which that canal communicated with the pleural cavity. The edges of this opening, were soft, pale, and grey in colour. It was evident that the appearance of the lung was due to the effect of a post-mortem change, the gastric fluid having first eroded the walls of the œsophagus, and then the substance of the lung. The child had been laid on the

back, and the part of the lung thus changed lay in the depending situation.

The anterior margin and tongue of the upper lobe, and the lower margin of the lower lobe, were collapsed, the lung in these situations being pale, flaccid, and non-aerated.

Bronchial glands were a little enlarged.

Larynx was healthy.

The stomach contained a small quantity of greyish mucus. A slight stream of water removed the mucous membrane from the cardiac extremity in considerable quantity. The opening in the œsophagus was about an inch from the cardiac orifice.

Pericardium contained a few drachms of serosity.

Remarks.—The points of interest in these cases may be briefly recapitulated. The subjects were all infants of tender age, from ten to sixteen months old. The collapse of the lungs was found, to a greater or less degree, in all the cases. It presented, for the most part, the usual characters; and with it was associated emphysema of the neighbouring lobes or lobules. This is an important fact, as related to the physical examination of the chest during life. In three of the cases there was something more than collapse of the long tissue. Bronchial abscesses were present, and the condition of the collapsed portions varied, there being, in some of the cases, congestion, and, most probably an inflammatory state of the minute bronchial tubes of the corresponding portions. The history of these cases during life illustrates one or two points important to bear in mind with reference to hooping-cough in very young children. Only one of them was observed to hoop. So far as I have observed, the intensity and frequency of the hoop is a circumstance of good augury rather than the reverse. The treatment adopted in these cases by my friend Mr. Filliter was of a stimulating character, mild expectorants and ammonia, together with a little wine and counter-irritation, by means of mustard cataplasms or liniments. The unfavourable hygienic conditions in which the children were placed, however, coupled with their age, precluded a favourable result.

Death took place on an average about three weeks after the commencement of disease.

Dr. Graily Hewitt, *4th of March*, 1856.

---

9. *Lobar Pneumonia of the whole of the Left Lung, and Disseminated Carnification, with Emphysema, of the Right Lung, in an Infant.*

These specimens were taken from a female child, æt. eight months, delicate from birth, who had an attack of capillary bronchitis ten weeks before death, which lapsed into pneumonia of the entire left lung, resisted treatment, and proved fatal. She was under my care about six weeks: the physical signs throughout were well marked; the cough, in the first instance, was loud, not paroxysmal, and more or less constant; subsequently it became replaced by a continued hacking. The child could scarcely cry the last few weeks of life, and became extremely emaciated, notwithstanding her appetite was tolerably good with such an amount of disease present. There were no symptoms of pertussis, nor was the child in contact in any way with other children affected with that disease: special attention was paid to this point in the case. Death occurred on the 8th of May.

Autopsy twenty-one hours after death.—Emaciation was general over the entire body. The abdomen was somewhat enlarged; the left side of the chest was very prominent and elevated, whilst the right seemed depressed: the latter appearance, however, was not real.

The left lung was found completely solidified, in a state of true hepatization, with the exception of a small portion of the upper and inner angle of the lower lobe, the size of a marble, which was emphysematous. The right lung was slightly adherent to the pleura; it was affected with interlobular emphysema in various parts; its middle lobe was completely carnified (not hepatized). This condition was also present in the middle of the upper lobe, at its apex, and at its anterior part;—in three distinct situations. Between these portions of carnified lung the emphysema was well marked; it was less so in the lower

lobe. This lung appeared to have pushed the heart towards the left side, and the prominence there depended upon this cause. The actual space occupied by the left lung was, however, less than that of the right. Inflation produced no effect whatever on the left lung, with the exception of the small emphysematous portion of the bulk of a marble; the right was more sensibly affected, the carnified portions remaining impermeable to the admission of air. The longitudinal and circular muscular fibres of the trachea and bronchial tubes, so far as they could be traced, were normal. The heart contained a few small patches, on its anterior surface, of a scarlet redness; these were also continuous along its left border. They appeared to run along the course of the anterior and posterior coronary arteries, and were due to the rupture of their minute capillaries. The left side of the heart was filled with coagulated black blood, which extended into the larger vessels, none of which were found empty. All the abdominal viscera were healthy; the lower part of the large intestine was filled with fæculent matter.

The interest of the case consists,—

1. In the existence of inflammation of the whole of one lung; a condition by no means uncommon in infants, but which is denied by some writers on diseases of children.

2. The presence of carnification in the opposite lung, associated with emphysema. The coexistence of these two conditions, pneumonia and carnification, although I have found it to occur before in the lungs of children, I am glad to have the opportunity of recording an instance of, more especially as carnification is believed by some very recent writers to be almost exclusively the consequence of hooping-cough, whereas the reverse is the fact. It most certainly is found in a complication of pertussis, the same as pneumonia might be; but its presence is very common in children suffering from chest complaints generally, who have not died from pertussis; an opinion which is supported by the testimony of all eminent writers on diseases of children.

Dr. Gibb, *20th of May*, 1856.

---

10. *Cephaloma of the Lungs.*

V. S. a stout well made man, æt. 36, married, and accustomed to work in a candle manufactory, was admitted into the Brompton Hospital for Consumption, the 5th of January, 1856, in a weak exhausted condition, occasioned by severe hæmoptysis. His habits had not been temperate, but he had always been robust and healthy till about eighteen months since, when he fell down in the warehouse, and hurt his back and side. A month after the accident he had an attack of hæmoptysis, coughing up about a pint of blood daily for three days. More or less hæmoptysis continued, with occasional intervals of a few days. He left off work about six months previously to his admission to the Hospital; and for five months had suffered from cough, the sputa being always coloured with blood. Lately there had been night sweats. His countenance was anæmic, and expressive of anxiety; the tongue slightly furred; bowels rather confined, but appetite not bad although capricious; pulse ninety, of good strength; respirations thirty a minute; rather laboured, especially during paroxysms of cough and hæmoptysis. Auscultation in front of the chest did not afford any indication of disease. At the lower and back part of the right chest, there was evidence of consolidation; but it was not found prudent to attempt much examination, as any movement of the body seemed to renew the discharge of blood. The use of astringents and other appropriate treatment appeared, in some degree, to moderate the bleeding; but the average amount of blood lost was not much less than half a pint daily during the time of his stay in the Hospital; and he died rather suddenly, about nine days after his admission.

Autopsy seventeen hours after death.—Rigor mortis complete. Body not emaciated; brain perfectly healthy. Left lung without adhesions, and apparently free from disease. The right pleura contained in its sac about a pint of serum, and was slightly adherent to the posterior part of the base of the lung. This part of the lung contained a cavity about the size of the fist, enclosing a coagulum of blood, weighing six ounces and a half, which had evidently proceeded from an ulcerated

opening in a considerable arterial branch. The surface of the cavity was irregular, rough, and of a greyish-white colour. Material scraped from the surface, when submitted to the microscrope, exhibited cells of various shapes and sizes,—flattened, angular, fusiform, and oval; many of the larger cells containing nucleolated nuclei. The other organs of the body were perfectly healthy; and, to the unassisted eye, there was no appearance of any deposit in either lung, excepting that about the cavity under consideration. The specimen being carefully examined by Dr. Andrew Clark, it was ascertained that the whole of the air vesicles were lined with cells approximating in character to the cancer cells found in the deposit: that the follicles of the bronchial mucous membrane were all filled with cancerous elements: and that the bronchial mucous membrane contained vegetations of the same character. Cancer elements were further found in all the minute blood-vessels, some of which were filled with cancerous matter. The loose secretion in the bronchial tubes was also intermixed with cancerous material.

The occurrence of cephaloma, even after a blow, in a healthy man without hereditary liability to malignant disease, and the death from hæmoptysis, the result of ulceration of an artery; the seat of the morbid deposit on the free surface of the mucous membrane, and the extensive diffusion of cancer elements not recognized by the naked eye; are amongst the particulars in this case worthy of notice.

Dr. THEOPHILUS THOMPSON, 19*th of February*, 1856.

---

11. *Cancer (?) of the Lungs, with Irreducible Omental Hernia.*

A woman, æt. about 25, who had long suffered from an inguinal hernia, which had lately become irreducible and painful, was admitted into the Royal Free Hospital, under the care of Mr. Wakley, desiring an operation. Prior to performing it, Mr. Wakley asked Dr. Brinton to examine her chest, as she was thin, of cachectic appearance, and had slight cough. The breathing was rather harsh, though slow; and under these sus-

picious circumstances the operation, which was not demanded by any urgent symptoms, was delayed.

In the course of two or three weeks diarrhœa set in; and was followed, in about a fortnight more, by symptoms of slight peritonitis, with constant vomiting. Under the use of opium, and a very sedulous adjustment of her diet, the latter symptom was soon relieved: but a gradual increase of marasmus carried off the patient in about a fortnight from this time. The physical signs of the chest remained little altered to the last.

The impacted hernia consisted of omentum, retaining its fatty structure, but aggregated into a mass about the size of a walnut by thickened fibrous tissue, with which was mingled a small quantity of effused blood. A similar mass lay just within the internal abdominal ring. From the upper end of this latter mass, two thin folds of membrane could be traced; one, of omentum, expanding into the general sheet of this process of peritoneum; another, also serous, retaining its narrow width, was attached to the lower border of the ilium, about six or eight inches from the cæcum. Although it contained no very distinct vessel, or cord-like relics of a vessel, yet its remarkable smoothness, regularity, and organization, suggested its being the analogue of that process which sometimes attaches the diverticulum found in this situation to the anterior wall of the belly.

The abdomen was occupied by a small quantity of a turbid fluid; and the peritoneum covering the large intestine was roughened, and of dull appearance, especially on the left side, where flakes of lymph were found attached to the bowel, corresponding to the situation in which the limited pain and tenderness had been most complained of during life.

Two or three of the upper lumbar glands were enlarged and softened; but their cells offered no differences from the normal growth of these organs that would entitle them to be definitely termed cancerous. Their increased number, their distinct and clear outlines, and the milky juice that appeared to occupy their interstices, pointed, however, to such a conclusion.

The bronchial glands of both sides offered precisely similar appearances: and the lungs were occupied throughout with

masses of a whitish substance, varying in size from a millet seed to a bean. To the naked eye these masses had all the ordinary external character of pulmonary cancer. Under the microscope they could be seen to consist of lung tissue, the vesicles of which were distended, and thus demonstrated by a cell growth. The cells of this mass closely resembled those of the epithelium that normally lines the air cells; but differed from them in their greater distinctness of outline, and in the evident tendency of many to a fusiform shape. Those from the somewhat softened centres of the larger masses contained some fatty looking granules externally to their large nucleus; and their outer cell wall underwent a much more rapid solution in dilute acetic acid than those nearer the periphery.

Dr. Brinton regarded the fusiform shapes of many of these cells as possibly due to the result of their mutual pressure; and though disposed to regard the disease as undoubtedly cancerous, based this diagnosis on the general symptoms and progress of the case, as well as upon the mere histological details just mentioned. Dr. Brinton, *6th of May*, 1856.

III.—DISEASES, ETC. OF THE ORGANS OF CIRCULATION.

1. *Calcified Pericardium in a case of Cerebral Apoplexy, with a multitude of small Gall-stones in the Gall-bladder.*

The specimen of calcified pericardium was about the size of a small adult open hand. It was bent at its middle on itself, and was dense, hard, and bone-like; its thickness being, in some parts, about a fourth of an inch. It had been taken from a pensioner of Greenwich Hospital by Mr. Rae, to whom Dr. Quain was indebted for the opportunity of bringing the specimen before the Society. The man, æt. 91, on the 23rd of October, was seized with apoplexy and paralysis of the left side, which terminated in death on the 25th. There was nothing known of his preceding history.

On the under surface of the anterior lobe of the right

hemisphere of the brain, an apoplectic clot, of the size of a walnut, was found surrounded by softened brain. There was considerable arachnoidean and sub-arachnoidean effusion.

The lungs were much congested.

The pericardium (in the form above described) was found firmly adherent to the heart in front and inferiorly—posteriorly it was free. The heart weighed sixteen ounces and a half. Its structure was somewhat dense, and its colour a dark red. There was slight calcareous deposit in the aortic valves, and at the auricular attachment of the mitral.

The liver was small and congested, the cells healthy. The gall-bladder contained seven hundred and thirty-five calculi, averaging hemp-seeds in size, of a dark green colour, and irregular on the surface.

Kidneys small, contracted, firm, and cystic.

The only remark which could be offered on the specimen was, that it afforded a very excellent example of calcareous deposit in, probably, some old adhesions of the pericardium.

Dr. Quain, *6th of November*, 1855.

Report on the structure of this specimen.—The portions of calcified pericardium, submitted to us for examination, consisted of plates of a substance of bone-like hardness, interposed between a layer of fibrous tissue on either surface. The thickness of the calcified membrane varied in different parts, from one to three or more lines. The fibrous covering on either side was thin, and easily peeled off, leaving the calcified layer nodulated, irregular, and of a yellowish tawny, or mottled aspect. In the intervals of the irregular surface, portions of fibrous tissue adhered with much firmness, and in places seemed to pass in between interspaces in the bony plates. On endeavouring to grind portions of the calcified mass for microscopical examination, the substance rapidly wore away under the action of the stone —more so than any of the normal calcified structures. Upon grinding a smooth surface, the substance exhibited a peculiar appearance, reminding one of the markings of a cut and polished surface of stalagmite,—alternate light and darker buff lines, having a relation to the surface, and succeeding

one another alternately with a wavy parallelism. When the sections were approaching a degree of thinness, that might answer for viewing with transmitted light, many of them broke up from extreme brittleness, and all of them showed great unevenness of consistency in different parts. We succeeded, however, in obtaining several sections of sufficient tenuity for microscopical examination. These were mounted in Canada balsam, and exhibited appearances characteristic and intelligible.

Upon viewing these specimens with transmitted light, magnified four hundred diameters, they are seen to exhibit masses and particles homogeneous and transparent, and interspaces of black opacity. The transparent calcified masses may be described as exhibiting two different forms, and the interspaces between them, of course, correspondingly varied. By far the most general form of the calcified particles is that of a sphere, or spheres, more or less fused together, bounding interspaces with concave edges, formed by the convex bulgings of the globules. The forms of the interspaces are very varied—depending on the isolation or fusion of the globules, their size, and their number (Plate III. Fig. 2.). Four globules of equal size, touching at their edges, bound a diamond-shaped interval, with concave sides; linear series of laterally fused globules leave elongated interspaces with serrated margins. Some of the interspaces are mere semilunar lines, while others occupy a tract larger than many globules, but with margins always indicating the globular outline.

When seen in specimens, in which the mounting has been rapid so as to prevent the escape of air, the particles themselves are seen to be clear and transparent, while the interspaces are perfectly opaque. When, on the other hand, the mounting has been slow, and the specimen has been soaked long in the fluid balsam, the resin fills up the interspaces, their opacity is destroyed, the whole structure becomes clear and transparent, and the globular forms of the calcified masses are beautifully sharp and clear (Plate III. Fig. 3.); and then, too, the agglomerated nature of the whole becomes very apparent: instead of the superficial outlines of clear globules and

DESCRIPTION OF PLATE III.

Figure 1 illustrates Mr. Hutchinson's report on the microscopic constituents of Dr. Hillier's case of Tumor of the Brain, p. 20. Magnified 400 diameters.

Figures 2 to 4 illustrate Dr. H. and Mr. J. Salter's report on Dr. Quain's specimen of Calcified Pericardium, p. 73.

Fig. 2. Portion of section, mounted in Canada balsam, displaying *transparent calcification globules* and *opaque interspaces* filled with air.

Fig. 3. Portion of section of calcified pericardium, *the opaque interspaces obliterated by being filled with Canada balsam*, displaying thus the distinct solidity of the calcification globules.

Fig. 4. Portion from which the earthy materials have been removed by hydrochloric acid. The albumenoid basis of the calcification globules alone remains, and from its softness is pressed out into flat disks by the weight of the superimposed glass.

These all magnified 400 diameters.

Fig. 1

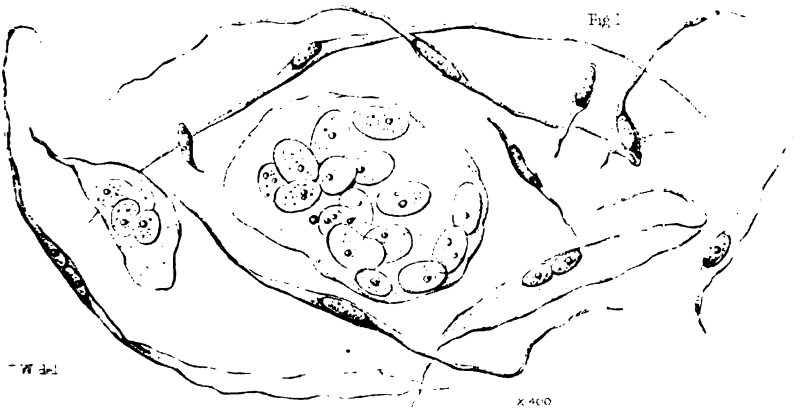

Fig. 2



Fig. 3

Fig. 4

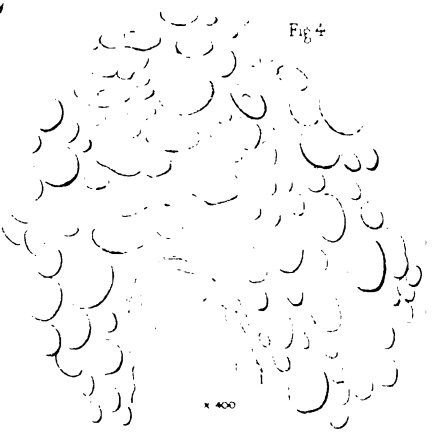

Hyde Salter M.D. del. Tuffen West sc.

W. West lith.

interspaces, with crescentic margins, one can (if the specimen be of some slight thickness) see into its substance—can, by altering the focus, see the agglomeration of spheres adhering together, some deeply looming out of focus, others superficial and sharp, some isolated and round, others so fused together as to present only convex bulgings.

The appearances we have just described, of globular calcified masses, and opaque interspaces, are exactly the same as we have observed in osteoids* from the pleura, and in sections of so-called ossified aorta,† and in the dentine of teeth,‡ in which the calcification process has been arrested at a half stage: we believe they are dependent on the same anatomical conditions, and are susceptible of the same physiological interpretations.

In the other form of calcification, the masses and interspaces, which we have mentioned, differ, not in optical appearances, but in shapes. There is the same clearness of the calcification masses, and the same opacity of the interspaces:§ but the latter are considerably larger, very irregular, are elongated pretty much in one direction, and the indication of globular outline is infrequent, though occasional. The whole structure has more of a directional tendency, and a sort of obscure fibrous aspect.

The appearances of decalcified specimens were very interesting. Several sections were made of various thicknesses, and then steeped in dilute muriatic acid: the earthy matter was dissolved out with brisk effervescence, and an animal basis remained, in each case retaining the form and dimensions of the original. The soft residuum was uneven in its characters;

* Ossific Mass deposited in the Pleura, Dr. Hyde Salter. "Transactions of the Pathological Society," vol. v.

† Ib.

‡ The Calcification of Dentine, S. J. A. Salter. "Journal of Mic. Science," vol. i.

§ We are surprised to find Wedl, in referring to this form, call them 'irregular interspaces, *filled with calcareous salts.*" There is no evidence whatever of their being so filled; and the idea once held that the black opacity of cavities and lacunæ in bony structures, and the tubes in dentine depended upon such contents, has long been exploded.

it tore up readily, in some places, with short and irregular fracture, in others splitting as a fibrous tissue.

Under the microscope, the sections exhibited a very peculiar appearance; they displayed, in some places altogether, in others principally, a countless multitude of pale, clear, distinct circles, each perfectly homogeneous, and in form consisting apparently of flattened disks. They appeared each perfectly distinct in outline, and in thickish sections, by lowering the focus they could be seen deeper and deeper, but the outline still distinct. Though each looked separate, they evidently adhered together: where the section consisted wholly of them, it had a very palpable cohesion among its parts, and under the microscope the circles showed indication of traction; by the pulling of two points of needles the intermediate disks drew out into oval shapes (Plate III. Fig. 4.).

Other portions of the animal basis displayed a distinct fibrous structure, whilst some parts were clear and homogeneous; but by far the greater portions of the masses consisted of the clear, pale disks above described (Fig. 4.). The nature of these circular disks appeared to us sufficiently obvious — that they constitute the animal basis of the calcification globules cannot, we should think, be doubted; and their flattened shape would naturally arise from the weight of the superimposed glass upon their very soft substance; and it seems probable that the fibrous and less intelligible portions had constituted the animal basis of those parts of the calcified mass, where the globular forms were not seen.

Questions naturally suggest themselves as to the nature of this calcification process, and the relation it has to the original textures in which it takes place. Are the calcification globules interstitial deposits among the fibrous tissue of the pericardium? or, are they produced by a calcification of the previous fibrous tissue in globular forms? Is the calcification, where the globules are not seen, of the same nature as that where they are seen? We believe these queries may be solved by considering the circumstances under which the same conditions are produced in the calcification of dentine, a process which is now thoroughly understood.

The calcification of dentine is accomplished, not by the interstitial deposition of phosphatic earth in a web of animal matter, nor by the slow and even impregnation of the whole animal base at once; but thus:—A soft animal substance is developed on the tooth-pulp, having the structure of dentine (tubes, and intertubular substance); in this, calcification takes place at numerous points; from these isolated points calcification goes on evenly in all directions, producing thus globular forms; the calcification of these is absolute, while the intermediate dentine cartilage is as yet unchanged, but by extension the soft substance is slowly invaded as the globules enlarge, and, ultimately, if the calcification be complete, the globules are lost by their fusion together, and become totally invisible. If, however, the process of calcification be arrested by an insufficient supply of earthy matter, or a perverted nutrition, the globules are only partially, or not at all fused together, and the interglobular, soft, animal matter remains unchanged. When such specimens of blighted dentine are suffered to get dry, the soft uncalcified interglobular animal matter shrivels up to a mere film, and thus produces the interglobular spaces, while the globules themselves are sharp, and distinct, and unaltered. Hence the interspaces; hence the globules. There is one more point that is worthy of remark in reference to the calcification of dentine; it is, that the addition of earthy matter does not constitute the whole change; the animal matter becomes much denser at the same time, and the globules, decalcified by acid, leave an animal basis much firmer than the interglobular substance. The calcification of dentine, therefore, involves an animal-base differentiation, as well as the lime-salt impregnation.

Now these changes, supposed to occur in the pericardium (the arteries and pleura in the same way), would, we think, satisfactorily explain the appearances we have described, as far, that is, as refers to the globular portions of the specimens; and we also think, where the globular forms are not produced, the difference is one, not of character, but of shape, and that the calcification, instead of proceeding evenly in all directions, so as, from points, to produce globules, assumes a directional

tendency in accordance with the course of the tissue affected, just as is the case in the calcification of the permanent tooth-pulp, during the development of osteo-dentine.*

We are indebted to our friend Dr. Odling, the accomplished Professor of Practical Chemistry at Guy's Hospital, for an elaborate analysis of this calcified structure.

Dr. Odling tells us—"From my examination of the osteoids received from you, I conclude that the animal basis is of an albuminoid, and not of a gelatinous character.

"It is generally admitted by zoo-chemists that there is an infinite variety of albuminous bodies, of which the distinctive characters pass into one another by insensible gradations.

"Is it not possible that the chain may begin with normal gelatine, and proceed upwards to albumen? Thus the gelatine of the skin is free from sulphur: bone gelatine contains a minute quantity: chondrine rather more; while the osteoid basis appears to contain a quantity, intermediate between that of chondrine and albumen.

"The relative amounts of organic matter, phosphate of lime, and carbonate of lime, correspond entirely with those of genuine bone. The amount of pyro-phosphate of magnesia formed in true bone varies from 0·5 to 2·0, or even 2·5 per cent.

"It exists in larger proportion in the ash of cartilaginous and fibrous tissues than in that of bone. Chloride of sodium was the principal constituent of the alkaline salts."

The pyro-phosphate of magnesia was here in excess.

The following is the table of Dr. Odling's quantitive analysis :—

"Water	7·21
Organic matter	28·29
Pyro-phosphate of magnesia	3.36
Phosphate of lime	52·20
Carbonate of lime	8·48
Salts and loss	·46
	100·00"

Dr. H. Salter, and Mr. J. Salter, *4th of December*, 1855.

* Intrinsic Calcification of Permanent Tooth-pulp, S. J. A. Salter. "Guy's Hospital Reports," vol. i. Third Series.

2. *Extensive Effusion in the Pericardium.*

J. F. a labourer, æt. 26, was admitted to St. Thomas's Hospital on the 5th of November.—Never having been very healthy, he was attacked with pain of the left side of the chest three weeks ago. Says there was rusty tenacious expectoration.

When first seen he lay with the shoulders elevated, and leaning a little towards the left side: respirations forty-five per minute. The anterior part of the left side of the chest was perceptibly larger than the right. There was excessive dulness on percussion over a space bounded above by the lower margin of the left first rib; below by the lower margin of the chest; to the left by a line an inch to the left of the left nipple; and to the right by a line an inch to the right of the sternum. The chest elsewhere was fairly resonant; less so on the left than on the right side. The heart's impulse could not be felt anywhere; and its sounds were feeble and distant. Large crepitation was heard over the left side.

These symptoms did not materially alter; and he died on the 11th of November.

Post-mortem examination.—Not emaciated. The pericardium was enormously distended with fluid: it reached from the upper margin of the sternum to the lower margin of the ribs on the left side, extending considerably beyond a line drawn perpendicularly through the left nipple, and encroached greatly on the right side of the sternum. Its vertical length in the mesian line was eight inches; its breadth, opposite the second rib, was three inches and a half; opposite the fourth, six inches and a quarter; and its greatest width, opposite the fifth rib, was eight inches and three-quarters; and along the base of the thorax, eight inches. Generally it extended from the junction of the ribs and cartilages on the right side, to a sinuous line which corresponded to the junction of the four upper ribs with their cartilages; but which, below that point, extended three or four inches further to the left. The lungs were somewhat compressed, and pushed so much backwards and laterally, that no part of them could be seen on first opening the chest; and scarcely any after separating the pericardium from them. The pericardium contained about two quarts of rather thick and

greenish-yellow puriform fluid. Irregular patches of lymph were deposited on the surface of the sac; and large soft yellowish opaque masses occupied its most dependent part. The parietal membrane was considerably thickened. The heart was extremely flabby, and its surface pale.

At the apex of the left lung were a few old adhesions; the remainder of its surface was united to the parietes by a layer of lymph of varying thickness: in some situations, and especially at the lower part, it was a quarter of an inch thick. The lung was heavy, and much compressed by the distended pericardium, and pushed to the upper and posterior part of the chest. The upper lobe was very sparingly crepitant; and contained a considerable quantity of slightly turbid fluid. The surface was tolerably smooth on section; but the lobules projected from it as though they had been distended and compressed. The tissue of the lung was normally tough, and was rather paler than natural. The lower lobe was redder than the upper, but in other respects presented nearly the same characters. The right pleura presented numerous adhesions, which were most numerous between the surfaces of the lung and the pericardium. The lung was pushed very much on one side by the pericardium; but it was little, if at all, reduced in size. It was crepitant throughout; somewhat congested and œdematous, being more so in the upper lobe than the lower. The bronchial tubes were healthy.

Dr. Barker, 20*th of November*, 1855.

---

3. *Two Cases of Malformation of the Heart.*

1. *Contraction of the Pulmonary Orifice, with Imperfection of the Septum Ventriculorum, and an Osseous State of the Ductus Arterisous.*—R. B. a female, æt. 19, was a patient in St. Thomas's Hospital, in July, 1854, first under Dr. Bennett, and subsequently under Dr. Peacock. She had from birth been of a peculiarly dark colour; and when ten months old began to suffer from violent fits of crying and excitement, in which she became black in the face, and which sometimes terminated in convulsions. These fits continued to recur at intervals of a few hours or days, till she was five years; when they ceased, but she

continued subject to transient attacks of headache. She continued subject to dyspnœa and palpitation, and to frequent catarrhal attacks, in which she occasionally spat blood, till she was eighteen years of age, when the catamenia first appeared, and recurred imperfectly three or four times. While an inpatient at St. Thomas's she was markedly cyanised, and presented the usual symptoms of malformation, with signs of obstruction at the right side of the heart. Her cheeks were livid, and the colour did not quickly return into them when they were blanched by compression. The conjunctivæ were injected, and the lips, gums, and interior of the mouth were of a dark purple hue. The nails were much arched, and of a purple colour; and the extremities of the fingers were somewhat bulbous. The chest was prominent in front, and narrow, but equal on the two sides. There was an obvious carotid pulsation; and the jugulars were distended, but did not pulsate.

The præcordial dulness commenced at the level of the third left cartilage, and extended thence to the edges of the ribs. Laterally it extended from the left side of the sternum to fully an inch beyond the left nipple. On listening over the third cartilage, between the nipple and sternum, a soft blowing murmur was distinctly heard; and it was audible, though less intensely, over the whole præcordia, and in a line towards the middle of the left clavicle; and still less loudly to the right of the upper part of the sternum. A loud ringing second sound was heard about the middle of the sternum, and at the upper part of that bone after the murmur. A very marked thrill was felt on pressing, between the intercostal spaces over the whole præcordia, but especially between the third and fourth cartilages. She had distressing palpitation and dyspnœa; and she was becoming anasarcous. During the month of September, while cholera was prevailing, she was seized with bilious vomiting, the bowels being then confined: two days after, when she was apparently pretty well, diarrhœa suddenly commenced; and she rapidly sank into fatal collapse.

The brain and lungs were found greatly congested, and the intestines contained the usual gruel-like fluid met with after death in the second stage of cholera. The heart was very

greatly enlarged, weighing seventeen ounces and a half avoirdupois. The right auricle was distended with blood, wholly uncoagulated; its walls very greatly hypertrophied, measuring two to three French lines in thickness. The right ventricle formed nearly the whole of the anterior surface of the organ, and its walls were thick, varying from three to seven lines in width, and very firm. The aorta arose very much to the right of the pulmonary artery, and communicated by a large aperture with the sinus of the right, as well as with the base of the left, ventricle. The pulmonary artery was very small, and communicated with the infundibular portion of the right ventricle by an aperture, provided with only two valves, and so contracted as only to admit the passage of a cylinder eight French lines in circumference. The walls of the left ventricle were much less resistant than those of the right, and from two to six lines thick. The left auricle was small, and its walls one line and a half thick. The foramen ovale was entirely closed. The ascending portion of the aorta was of large size: the ductus arteriosus was sufficiently open to give passage to a crow-quill.

Remarks. The above case affords an example of an open condition of the ductus arteriosus, and a imperfect state of the septum of the ventricles, most probably dependent on the obstruction at the pulmonic orifice. Cases of defective ventricular septum and open foraman ovale, with obstruction at the orifice of the pulmonary artery, are of common occurrence; but the existence of an open ductus arteriosus, in conjunction with imperfection either in the septum of the ventricles or auricles, is of much less frequent occurrence; yet, probably, both conditions may be equally traced to the obstruction at the pulmonic aperture.

If, during the early periods of fœtal life, before the separation of the ventricles is completed, the pulmonic orifice become the seat of obstruction, the development of the septum may be arrested, and a communication will remain between the two ventricles; and the aorta will derive its supply of bood from both cavities. So, also, if, after birth, the outlet afforded by the pulmonary artery from the right ventricle be not sufficiently

free, the foramen ovale may be prevented from closing; and if the amount of blood capable of being transmitted to the lungs through the pulmonary artery, be not adequate, the ductus arteriosus also may continue pervious. From the same cause, also, the foramen ovale and ductus arteriosus may remain open in cases in which the septum of the ventricles is complete; the defect at the pulmonic orifice, having, in such cases, occured at the later periods of fœtal life. Of the former description of malformation the case now related affords an example; and similar instances have been previously related by Drs. Graves and Houston, of Dr. Chevers and others; and also by myself in a former volume of the Society's "Transactions." Of the latter, cases are recorded by Schular, Seiler, &c.

It was supposed by Bertin that the hypertrophy of the right ventricle met with in cases of congenital malformation was due to the entrance of arterial blood into that cavity. The case detailed disproves this theory, and throws light on the true cause of the hypertrophy. From the relative strength of the walls of the right and left ventricles, it is quite evident that the course of the blood could not have been from the left into the right cavity; but that, on the contrary, the blood must have been thrown from the sinus of the right ventricle into the aorta, without any admixture taking place in the right ventricle. It is also clear that the hypertrophy could not depend chiefly on the pulmonic obstruction; for, while the walls of the infundibular portion measured only four lines in width, those of the sinus attained a thickness of seven lines, and were also much firmer and more resistant than the former. The great hypertrophy of the sinus of the right ventricle could, therefore, only be assigned to the important part which it had played in the maintainance of the systemic circulation; and the great additional effort which it, consequently, had to undergo.

2. *Contraction of the Pulmonary Orifice and Artery, with Imperfection of the Septum of the Ventricles, and Absence of the Ductus Arteriosus.*—For the opportunity of exhibiting this specimen to the Society, and for the particulars of the case during life, Dr. Peacock was indebted to Dr. Bentley.

The child from whom the preparation was removed, died when twelve months and three or four days old. When born it was noticed to be very livid; a fluttering was perceived at the heart; the breathing was very imperfectly performed, and these symptoms continued for several days; after which the child became less livid, but never had the natural colour. About seven weeks after birth, it began to have attacks of extreme dyspnœa; during which its breathing was rapid and laborious; it threw its head back and gasped for breath; its complexion became almost black, and it cried incessantly. These fits subsided after loud stridulous breathing, and the child became cheerful; but they were brought on by the slightest excitement, and especially on taking the breast or food. At first the fits only occurred about once a day; but towards the close of the child's life, they were sometimes many in the day; once fully thirty. Till the last month the child was fairly nourished, but it afterwards became extremely emaciated. It had cut one tooth.

The sounds of the heart were not well observed, but there was apparently no murmur; the beats were, however, rapid and violent, and the radial pulse weak. There was very obvious jugular pulsation. The child was born at the full period, and of healthy parents: it was the fifth, and one other was said to have something the matter with its heart.

The membranes and substance of the brain were congested; and at the base there was some recently effused lymph. There was a large effusion of serum in the ventricles, and some beneath the arachnoid. The lungs were much congested, and in places solid, and as if unexpanded.

The heart weighed two ounces and a half avoirdupois. The right ventricle was larger, and its walls thicker and firmer than those of the left. The aorta arose from both ventricles, there being a large deficiency in the interventricular septum. The pulmonic aperture was only eight lines in circumference. The valves were only two in number, and were thick and much indurated. They were protruded forwards into the artery so as to form a funnel shaped aperture from the ventricle, and to leave deep sinuses behind the folds. The pulmonary artery was,

throughout, of very small size; and no traces of the ductus arteriosus could be detected. The foramen ovale was largely open, and the Eustachian valve was very perfect. The ascending aorta was of large size, and suddenly diminished behind the left subclavian artery.

Remarks.—The case detailed affords an example of an interesting form of malformation, in which no ductus arteriosus can be detected; and in which it must, therefore, be inferred, that that canal had become obliterated at so early a period of fœtal life that all traces of its presence had disappeared. It is not clear how the primary deviation from the healthy process of development occurred in this case. It may be supposed that the diseased condition of the pulmonic valves, may have entailed the other defects; but this does not seem probable. Obstruction at the pulmonic orifice, though it accounts for the defective state of the ventricular and auricular septa, does not afford any explanation of the absence of the duct. On the contrary, as shown in the former case, it would rather occasion persistance of that canal. It seems most probable that the primary error consisted in obliteration of the duct at an early period of fœtal life; the pulmonary artery would thus be always of small size, and the valves may in consequence have become defective, or they may have been involved in the original error; and hence the other changes may have been occasioned. There can be little doubt that this is the mode of production of those very rare cases, in which, like one referred to by Dr. Ramsbotham, the ductus arteriosus is not to be found, the pulmonary artery is very small, and there are subsidiary vessels derived from the aorta which furnish the pulmonary supply. Cases closely resembling that just related have been recorded by Aran, Huss, Gintrac, Blackmore, Deguise, Otto, Knox, &c.

Dr. Peacock, 20*th of November*, 1855.

---

4. *Congenital Malformation of the Heart in a Youth.*

There existed in this heart, which weighed six ounces avoirdupois, a free communication between the ventricles. This

consisted of a quadrilateral perforation situated at the base of the septum, in what is known as "the undefended portion." It was sufficiently capacious to admit a florin to pass freely through from one ventricle to the other. The aortic opening was wide, and, being situated immediately over the perforation, seemed virtually to arise from both ventricles. Its valves were healthy. There were a few atheromatous points beneath the membrane lining the arch. The left ventricle was capacious. The mitral valve was healthy. The pulmonary artery was not more than a third of the diameter of the aorta. Its valves were in a like degree small and imperfect. The right ventricle was correspondingly reduced in size; seeming to be little more than an appendix to the left. The ductus arteriosus was closed; the foramen ovale was pervious to the size of a small quill.

The specimen had been taken from a youth, æt. 18, who, at birth, seemed to be a healthy child. When two years old, his mother noticed that his skin became bluish on any excitement or effort. When six years of age he had "inflammation of the chest," and, subsequently, measles. From that time, till his death, he was never well, his breath being always short on exertion. For ten years he had a short dry cough. None of his relatives were consumptive. He was himself intelligent, and possessed of a good memory. He was admitted to the Brompton Hospital, presenting the usual signs of consumptive disease of the lungs. His skin had a bluish tint, and his finger and toe nails were remarkably clubbed. He had hæmoptysis, to the extent of four or six ounces, about six months before his admission into the Hospital. He was emaciated, and the fourth, fifth, sixth, and seventh left ribs were prominent, rendering the chest irregular in form. There was a very loud and prolonged systolic bruit heard over the base of the heart. The difficulty of breathing and weakness increased, and he died in about a month after his admission to the Hospital. Cavities and softening tubercles were the only important changes observed in the organs, save that as above described in the heart.

Dr. Quain referred to the first volume of the Society's Trans-

actions, in which four similar cases were recorded—but in none was the opening so large as in the present instance. In one of these cases, as in the present, the subject had died of phthisis.

Dr. QUAIN for Dr. CURSHAM, 15*th of January*, 1856.

---

5. *Disease of the Aortic Valves and the adjoining Texture of the Heart; Formation of a False Aneurism of the Heart, communicating with the Aorta, giving rise there to Fibrinous-like Vegetations, and probably communicating also with the Right Auricle and with the Surface of the Heart.*

The specimen was removed from a man, æt. 65, of dissipated habits, who had served twenty-four years in the marines. Nothing more was known about him, than that he became a patient of the Infirmary of the Royal Hospital, Greenwich, on the 31st of August, suffering from diarrhœa, and that he gradually sank and died on the 13th of September. He presented no symptoms of heart disease.

After death, the pericardium was found distended with bloody serum. The liver was cirrhosed, and the kidneys granular.

The heart was found to weigh eighteen ounces. On laying open the aorta, a mass resembling vegetations, about as large as half a walnut, was found attached in the situation of one of the aortic valves, which it masked and concealed. One of the adjoining valves was also partially involved. This valve, and the valve free from deposit, were thickened and hard.

On examining this vegetation like substance, it was found to consist of blood-clot covered with a thin lamina of fibrin. On tracing this clot further, it was observed to communicate with some broken down clot contained in the substance of the left ventricle. The size of this clot was about that of a hazelnut. It extended towards the right auricle, the membrane of which it pushed upwards and inwards, and it was thus seen within the cavity of the auricle, as a small dark-coloured prominence. Mr. Rae, who made the *post-mortem* examination, and to whom Dr. Quain was indebted for the specimen, thought

that a perforation had occurred previously to death, for a perforation was found during the examination. The clot likewise extended outwards, and showed itself between the left ventricle and the right auricle. From this, the exudation of bloody serum into the pericardium seemed to have taken place, for the membrane covering this clot was exceedingly thin.

Dr. Quain remarked that there was nothing whatever to throw light on the clinical history of the serious lesion which this heart presented. The morbid appearances showed that there had been chronic disease of the aortic valves—that one of them was more especially diseased, and that close by that valve, in the wall of the heart, the hæmorrhage had occurred. On examining the tissue at this point, there was evidence of chronic inflammatory action—there was a quantity of cellulo-fibrous tissue mixed with broken down muscular fibre, fatty matter, and granules. It was in this situation that the hæmorrhage had occurred. A kind of false aneurism had been formed. The history, then, would thus be written—disease of the aortic valves, and of the adjoining substance of the heart, softening, hæmorrhage, formation of a false aneurism, this, then, communicating with the aorta, a clot arose constituting the vegetation-like substance, and thus further hæmorrhage was checked. It was singular that disease so extensive could have commenced, gone on, and terminated, without marked symptoms.

Dr. QUAIN, 16*th of October*, 1855.

---

6. *Specimens of Diseased Heart.*

1. The first of these specimens exhibited aggravated disease of the aortic valves. It was removed from a man æt. 45, a gardener by occupation, who had been an out-patient of Dr. Peacock's at the Hospital for Diseases of the Chest, Victoria Park.

He had never suffered from rheumatic fever or inflammation of the chest, and had never sustained any severe injury. When first seen, about a month before his death, he stated that he had only been ill two months. He complained of dyspnœa and palpitation, with cough and slight expectoration, but he had

DESCRIPTION OF PLATE IV.

Figures 1 and 2 illustrate Dr. Peacock's case of Union of the Aortic Valves, p. 88.

Fig. 1. The aortic valves and orifice of the aorta cut open.

Fig. 2. The lower portion of the aorta from above, showing the orifice and valves.

a a. Fræna or bands marking the former angles of attachment of the united valves.

b. The curtains of the valves at the ununited angle.

Figure 3 illustrates the destruction of the Chordæ Tendineæ connected with the anterior portion of the Mitral Valve, in Dr. Peacock's case. *See* p. 90.

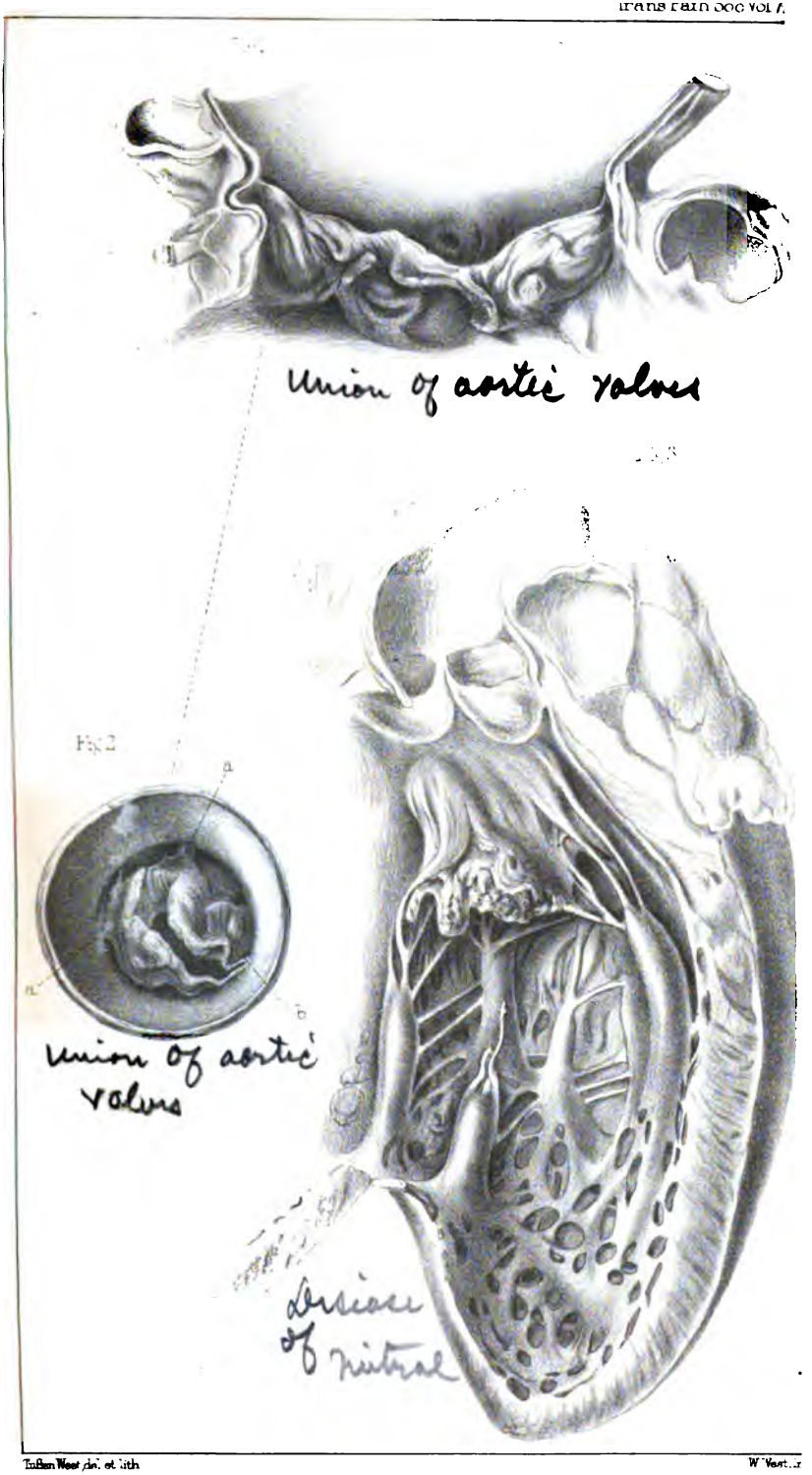

Tuffen West del. et lith

W. West, Sc

never had hæmoptysis or œdema of the ankles, or other dropsical symptoms. The pulse was full and jarring, and disappeared under the finger, displaying somewhat the character of regurgitation. The dull space on percussion, in the region of the heart, was extended beyond its natural limits; and a systolic murmur was heard over the whole præcordia, but most distinctly at the base and in the course of the aorta. The second sound was everywhere imperfect, and a feeble diastolic murmur was audible. He did not improve while under treatment; and was, for the last fortnight of his life, under the care of Mr. Harris, of Hackney, being incapable of attending the Hospital.

The *post-mortem* examination was made by Mr. Woodward, the resident medical officer of the Victoria Park Hospital, and displayed no material disease, except that of the heart. The heart (*see* Plate IV. Fig. 1.) weighed twenty ounces avoirdupois. The aortic orifice admitted only of the passage of a ball measuring twenty-four French lines in circumference, thus indicating a diminution of capacity to the extent of one-third or more. This contraction was caused by extensive disease of the aortic valves, the curtains of which were blended together at two of the angles, so as to form a contracted ring complete all round except on one side. (Plate IV. Fig. 2.) The valves were also much thickened and extensively ossified, presenting hard projecting nodules of bone, not, however, denuded of the endocardium. The fræna or bands marking the former angles of attachment of the united valves, (Fig. 2*a*.) were very distinct. At the ununited angle (Fig. 2*b*.) the curtains of the valves were not in contact, and probably allowed of some regurgitation, but not much.

The left ventricle was of very large size, but the walls were not increased in thickness. The right ventricles and both auricles were also dilated.

The case afforded an example of very aggravated disease, superinduced, upon what Dr. Peacock regarded, as an original malformation of the valves. (Lectures on Malformation of the Heart, in "Path. Trans." vol. iii. p. 291, 1851–52; "Monthly Journal of Med. Science," 1853; and "Med. Times and Gazettee," 1854,) consisting in the union of the contiguous curtains of the three valves at two of the angles of attachment.

It was, however, remarkable in that two of the angles were affected, instead of only one, as is generally the case. The subsequent disease had evidently been of very long duration; a slow transformation, probably at no time connected with any active symptoms. This was the more worthy of notice in that the patient dated the commencement of his illness only to a period of about three months before his death.

Case 2. The second specimen exhibited a complete destruction of the cordæ tendineæ, attached to one of the fleshy columns of the left ventricle.

The heart, (Plate IV. Fig. 3.) was removed from the body of a girl, æt. 16, a bookfolder, who had been under the care of Dr. Bennett, and subsequently of Dr. Peacock at St. Thomas's Hospital. About fifteen months before her death she felt pains in the limbs, and had some swelling of the joints, which were ascribed to cold; and these symptoms were followed by pain and stiffness in the neck, and soon after she began to suffer from palpitation, increased on exertion, and pain in the præcordia. On admission into the Hospital she suffered from febrile symptoms, with pains in the limbs. There was increased dulness on percussion in the region of the heart; and a systolic murmur was there heard, and was followed by a ringing second sound: the murmur was most distinctly heard at the apex. While in the Hospital she had inflammation of the veins of the left leg. She died under Dr. Peacock's care as an out-patient; and the *post-mortem* examination was performed by his clinical clerk, Mr. Cooke. The heart weighed twelve ounces fourteen drachms avoirdupois, showing considerable increase in weight. The left ventricle was large, but its walls were not much increased in thickness; and the muscular substance was soft. The cords attached to the columna carnea in the front of the ventricle, and inserted into the left side of the anterior fold of the mitral valve, were entirely destroyed, so that the fold was allowed freely to fall back toward the left auricle, and must have allowed free regurgitation.

The left auriculo-ventricular orifice had a capacity of fifty-four French lines, showing very considerable dilatation. The aortic

orifice was, on the contrary, small, being only thirty-three lines in circumference, while the pulmonic orifice was thirty-nine. The edges of the mitral valve was studded with small nodular concretions of recent lymph. The veins in the poplitial space were obstructed by firm decolorized coagula adherent to their coats. The specimen afforded a good example of regurgitation through the left auriculo ventricular aperture without contraction. Dr. PEACOCK, 16*th of October*, 1855.

---

7. *Disease of the Mitral and Aortic Valves.*

S. Y. æt. 21, a patient at the Northern Dispensary, under the care of Dr. Semple. About the age of ten or eleven years, she had scarlatina and rheumatic fever at the same time. Five years afterwards she was again attacked with rheumatic fever, and after two years more she had another attack of rheumatic fever, which lasted seven weeks. Since this third attack she was never well, and always complained of her heart.

She applied to the Dispensary in consequence of general weakness and amenorrhœa, for which some ferruginous and alterative medicines were prescribed. On examining her heart, at a subsequent visit, it was found that there existed a murmur accompanying the first sound of the heart over the mitral region, and another murmur over the aortic region, also systolic, and not very loud. The impulse of the heart was not increased, and there was no thrill; the pulse was weak. She was subsequently seen several times, and suffered from faintness, with extreme difficulty of breathing, and urgent feelings of oppression at the præcordial region. For these symptoms, she had stimulants and expectorants, which afforded temporary relief, but she afterwards became worse, dropsy supervened, and she died rather suddenly.

On *post-mortem* examination, the heart was found of moderate size; neither hypertrophied, nor diminished in thickness. The tricuspid and semilunar pulmonary valves were healthy. The mitral valves were thickened and ossified: the mitral aperture admitted barely a single finger, and the circumference was very hard and bony. The aortic orifice did not

close completely, and when fluid was poured in from above, it gradually passed through, showing imperfect closure. The valves themselves appeared healthy at their free margins, but exhibited a rim of incipient ossification at their attached portions. Dr. SEMPLE, *20th of November*, 1855.

---

8. *Diseased Aortic Valves.*

This specimen was forwarded to Dr. Peacock by Dr. Thurnam, of the Wilts County Asylum, and the following particulars of the case during life, were furnished by that gentleman.

S. B. a carpenter, æt. 64, was admitted into the Asylum on the 24th of August, 1855, having, for some weeks, laboured under melancholia, with suicidal propensity, which first showed itself after his marriage in the previous year, with his third wife. He was reported to have suffered for years from symptoms of disease of the heart, dyspnœa, lividity of the face, &c.

At first the mental symptoms improved, and, in September, he was well enough to be employed a little on the farm. In October he gradually became worse, refusing food; his nights were disturbed and restless, and there was much exhaustion. Early in November, symptoms of pneumonia appeared; but moderately active treatment only could be borne, and, on the 20th of November, he died.

On *post-mortem* examination, extensive consolidation was found in both lungs, especially the right. In the lower portion of that lung there was a cavity the size of a walnut, containing a dirty, greenish-black, purulent fluid, and the circumjacent lung was in a state approaching to gangrene.

The heart was greatly enlarged, weighing fifteen ounces and a half; and there was extensive disease of the aortic valves, which must have occasioned great obstruction. The valves were only two in number, and the aortic orifice, after the heart had been some months preserved in Goodby's solution, measured only thirty lines in circumference. The deficiency of the number of the valves was most probably due to the congenital fusion of the right and posterior segments into one. There was, how-

ever, such extensive chronic disease, thickening and ossification, of both the existing valves, that the mode of origin of the malformation was less obvious than usual. The usual frenum marking the line of fusion, existed, however, on the upper side of the valve; the origin of the right coronary artery corresponded to the situation which it should have occupied had there been three distinct segments, and there was an indistinct sulcus at the centre of the base of the united segment on the ventricular side. The two existing segments were nearly equal in size; the left measuring twelve lines, the right or double segment, fourteen lines in width. The fibrous zone was extensively ossified, and there were patches of atheroma in the aorta; the sinus of valsalva corresponding to the united segment was considerably dilated. The left ventricle was much enlarged, and the anterior wall measured, at the mid-point, nine and a half French lines in thickness; when recent, Dr. Thurnam stated that the walls were upwards of an inch (English) in thickness. The right ventricle was also of large size, and its walls thick, measuring four French lines in thickness at the mid-point. The auricles were dilated. Dr. PEACOCK, 15*th of April*, 1856.

---

9. *Hypertrophy of the Heart, with Diseased Valves.*

The patient was a boy, æt. 18, who had suffered from rheumatism to a very severe extent upon several occasions; the first attack having occurred about five years ago. He came under Dr. Semple's care, as a patient at the Northern Dispensary, in the month of March of last year. He used to come to the Dispensary himself, and was moderately active, but he was pale and thin. He complained of general illness, inability to do continuous work, of difficulty of breathing, especially when running or exerting himself, and of palpitation of the heart, with occasional cough. On applying the hand over the præcordial region, a distinct thrill was very perceptibly felt, and on the application of the stethoscope, the action of the heart elevated the head of the observer. The impulse of the organ was very strong, and felt over a great space. There was a loud sawing murmur with the first sound, heard over

the apex of the heart, prolonged and obscuring the second sound; there were two murmurs over the region of the base of the heart, one systolic, the other regurgitant. Sawing murmurs were also heard over the right and left carotid arteries. The diagnosis was hypertrophy and dilatation of the heart, with disease of the mitral and aortic valves. He was ordered to have a belladonna plaster over his chest, and to take some medicine, including tincture of Digitalis, in doses of five minims. This boy's symptoms were so well marked, and he was so competent for moderate exertion, that Dr. Semple sent him as a subject of clinical examination at one of the Hospitals, and he was also examined by the candidates for the appointment of assistant surgeon for the East India Company's service; and also by the candidates for degrees at the University of London.

On the approach of the present winter he became much worse, and was unable to go out. The difficulty of breathing increased, and œdema began to develope itself about the ankles and eyes, and he soon became generally anasarcous. The respiration was laborious, varying from thirty-two to forty-eight in the minute, the pulse from one hundred and twelve to one hundred and twenty, with a certain degree of wiriness. The physical phenomena of the heart remained the same. The urine was scanty, and distinctly albuminous, being examined on several occasions. He died on the 17th of December. The *post-mortem* examination showed the heart to be very much enlarged, and the pericardium adherent to its surface throughout. The heart extended below the margin of the sixth rib, but not beyond the right side of the sternum. The kidneys were of a dark colour, distinctly mottled, both externally and internally, not diminished in size, but rather large.

The weight of the heart was twenty ounces. The walls of the right ventricle were thin, and the valves both of that ventricle and the pulmonary artery were healthy. The walls of the left ventricle were thick and distinctly hypertrophied. One of the mitral valves showed a large spongy, fungus-looking vegetation projecting half an inch, and of a pyramidal

form; the other valve also showed a vegetation, but not very prominent. Of the three aortic valves, one showed a prominent spongy vegetation projecting into the cavity of the aorta. The other two did not exhibit any vegetations, but their substance was thickened on each side of the *corpora Arantii*, which were rather small. The warty vegetations alluded to, were peculiar, and the appearance of the valves very different from that usually presented by diseased valves.

Dr. SEMPLE, 15*th of January*, 1856.

---

10. *Specimen of Enlarged Heart, with the Thickening of the Mitral and Tricuspid Valves.*

The patient, a man, æt. 26, died a few hours after admission to the Hospital for Consumption, under the care of Dr. H. Roe; but had been for one month an out-patient under Dr. Pollock. He had rheumatic fever five years previously, and when he presented himself, was suffering from excessive dyspnœa, slight cough, partial aphonia, and considerable anasarca of the lower extremities. The physical signs, noted at the time, were extensive cardiac dulness, a harsh double mitral murmur, and coarse bronchial râles over both lungs. The urine was highly albuminous, and the patient had a very cachectic appearance.

On examination, fourteen hours after death, the lungs were found gorged with blood, and the air tubes and cells filled with thick mucous secretion.

The heart weighed sixteen ounces and a quarter, and was much enlarged. The walls of the left ventricle were five-eighths of an inch in thickness. The mitral valve much thickened, with firm, rough, granular deposit. From the free margin of one division depended a warty excrescence, which hung free into the ventricle, nearly half an inch long. The right ventricle was thin and dilated; passing from the junction of the upper with the middle third of its anterior walls, was a firm round band, from which arose the chordæ tendineæ of the septal division of the tricuspid valve.

The spleen was friable and gorged with blood, much enlarged, and weighed nineteen ounces.

The liver much congested, the cells containing many fat globules, weight two hundred and four ounces. The kidneys greatly enlarged, weight of each twelve ounces and a half. Under the microscope, uriniferous casts of large size were seen, some waxy, but most granular, in which were numerous fat globules and epithelial debris.

Dr. POLLOCK for Dr. HAMILTON ROE, 15*th of January*, 1856.

11.—*Aneurism of the Heart.*

The specimen showed an aneurism of the wall of the left ventricle, which appears as an open sac placed at the junction of the septum with the posterior wall of the left ventricle, and beneath one of the curtains of the mitral valve. The sac is about the size of a walnut; and it communicates through the septum with a sac the size of a nutmeg, situated in the wall of the right ventricle. This sac is situated immediately beneath the floor of the right auricle, and is superficial towards the surface of the right ventricle. On tracing it downwards, the sac is seen to pass towards the apex of the right ventricle, with which it evidently communicated through and among the trabeculæ. The sac is clearly of long standing, for it is lined throughout by a thick smooth membrane, which has, in some parts, an almost ossific hardness. The aneurism had evidently commenced on the left ventricular surface of the septum, and, gradually passing through it, formed in the wall of the right ventricle, where the septum and the posterior wall of the ventricle were in contact. Dr. Quain said he was indebted to Mr. Rae, of Greenwich Hospital, for the opportunity of bringing before the Society the specimen, which was taken from a Greenwich pensioner, æt. 75, who, for some years, had suffered from bronchitis, from gout, and, for a few months before his admission into Hospital, in August last, from œdema of the legs. When admitted he was suffering from cough, difficulty of breathing, irregularity of the heart's action, anasarca, and ascites. The dropsical symptoms had nearly disappeared, when he died suddenly, in an attack of dyspnœa, on the 14th of February. The heart's action was observed to be feeble through-

out his illness; and a loud bruit with the first sound was audible over the whole chest; but especially, and with nearly equal intensity, over the base, and at the apex of the heart.

The body after death was emaciated. The lungs, at both sides, were adherent. They were slightly emphysematous, and much congested at the posterior parts. The bronchial mucous membrane was tumefied and congested. The liver was fatty, and rounded at its edges. The spleen was smaller than usual; the capsule partially covered with a thick layer of hard fibrin. The kidneys were granular; the cortical substance of a light grey colour. The capsule was easily separable. In addition to the state of the heart already described, it was noticed that there were some three or four ounces of serum in the pericardial sac. There were several white patches on the surface of the heart. The whole organ, with the arch of the aorta, weighed thirty-one ounces. The aorta, as far as the termination of the transverse portion of the arch, was much dilated and calcified, so as to constitute a rigid tube. The aortic valves were incompetent; the mitral and tricuspid were tolerably healthy.

Dr. QUAIN for Mr. RAE, 19*th of February*, 1856.

---

12. *Case of Diseased Heart.*

W. H. æt. 58, a baker. A middle sized man, having the upper dorsal vertebræ bent forwards at a considerable angle; was first seen by Dr. Barker on the 5th of February, 1856. He had suffered from some dyspnœa and cough, generally coming on in paroxysms, since October last; but had not considered himself to be seriously ill until six days before Dr. Barker saw him. The dyspnœa then increased greatly, especially in the night. He did not complain much of palpitation, but was greatly annoyed by throbbing in the large arteries of the neck and arm. The impulse of the heart was very great, its sounds could be heard over the greater part of the chest; and the dulness in the cardiac region extended from the lower edge of the third rib to below the seventh, and from the right of the sternum to a line at least an inch beyond the nipple. A faint systolic sound could be heard occasionally over the aortic valves,

but this had been constant a few days previously: at the same place a loud and prolonged diastolic sound was always present. A loud systolic bruit was always heard at the apex of the heart. The pulse was very full and jerking in the arteries of the neck and in the brachial arteries, accompanied by a peculiar vibratory thrill:—it had the same character at the wrist, but was there very feeble.

The symptoms varied a little from day to day. On the 14th he was much worse; and it was then evident that the left pleura contained a considerable quantity of fluid. Previous examinations of the chest had not discovered any marked pulmonary disease.

He died on the 7th of March.

The right pleura contained about three quarts of serum.

The lung was completely compressed, but not otherwise diseased. The left lung was considerably congested.

The heart occupied the whole space marked by want of resonance during life. It weighed thirty-seven ounces, the hypertrophy and dilatation being observed principally in the left ventricle. The mitral valves were healthy, but neither its curtains, chordæ tendineæ, nor columnæ carneæ, were enlarged in proportion to increased size of the ventricle. The aortic valves were thickened, and their free edges much contracted. Two of them had old perforations of the size of a crow's quill. They would allow free regurgitation. The aorta and large vessels of the neck were very slightly diseased: here and there a small patch of atheromatous deposit existed.

Dr. Barker, *2nd of April*, 1856.

---

13. *Aneurismal Dilatations of the Coronary Arteries of the Heart and their Branches.**

The interesting specimen which is described below, was taken from the body of a sailor, æt. 22, who died after a three months residence in St. Thomas's Hospital. He was admitted for what was supposed to be fever; to this succeeded paraplegia; and at

* A case of Aneurism of the Left Coronary Artery is recorded by Dr. Peacock in vol. i. of the "Pathological Transactions," p. 227.

the end of the time mentioned he died, apparently of exhaustion. There was nothing in his symptoms to indicate disease of the heart.

Pericardium healthy. The heart appeared rather enlarged, and weighed eleven ounces and three-quarters; but its shape and the relative dimensions of its parts were perfectly normal. In the course of the vessels that ramified on its surface were observed a number of nodules, isolated and in strings, and individually from the size of a pea downwards, the nature of which, at first sight, was not very apparent. Dissection, however, showed that they were due to aneurismal dilatations occurring in the course of the trunks and branches of the coronary arteries.

Many of these formed isolated, hemispherical, or spherical pouches, from the size of a pea to that of a tare. Such pouches existed usually at the point of origin of branches They communicated by circular orifices with the vessels whence they sprung. Their parietes were denser and thicker than those of the healthy artery. Some of them were empty, others completely filled by adherent, toughish, buff-coloured clot.

Many of the aneurisms existed under the form of a sacculated condition of the arteries, which occupied from two inches to half an inch of their length, and sometimes involved a connected series of branches. The thickness of these sacculated portions of artery varied from a quarter of an inch downwards, the average being two lines, and one and a half. Their channels varied considerably in size, and were very tortuous; their parietes were thick, firm, and consisting, apparently, of a dense fibroid tissue. Many of the more distinct pouches connected with the tortuous and dilated channels were filled, like those of the isolated aneurisms, with decolorised and adherent clot.

All those parts of the walls of the coronary arteries and their branches which were undilated, appeared to be perfectly healthy, and free from atheromatous deposit.

The left coronary artery, from its origin to the anterior sulcus between the ventricles, was healthy. In the latter situation it divided into four or five branches. One of these ran along the sulcus to the apex of the organ; this presented, about

the middle of its course, two or three isolated aneurisms, and two or three more at its termination: and three or four branches which sprung from it were sacculated, or presented single dilatations near their origins. A second branch ran downwards towards the left of the apex of the heart; this presented a single aneurism about its middle, at the origin of a small branch, and about midway between the apex and base of the ventricles it divided into two or three branches, each of which displayed a series of aneurisms from the size of a pea downwards. Two other small branches were prolonged from the same point in the coronary artery into the surface of the left ventricle, and both of them were sacculated to a considerable extent. In its course from the anterior to the posterior ventricular sulcus, the trunk of the artery presented several small aneurisms; and so, also, did two or three small branches, which passed from it on to the surface of the ventricle. The artery running down the posterior sulcus was directly continuous with the left coronary artery: it was dilated at its origin, for the length of half an inch, so as to measure two or three lines in thickness. Several aneurisms exisited in its course, and several in the branches connected with it.

The right coronary artery divided immediately after its origin into four or five branches, each of which, at its commencement, was dilated into a series of sacculated aneurisms, from a quarter of an inch to one line and a half in diameter. One or two of these branches crossed to the left, over the conus arteriosus; and these, for an inch or two of their length, were somewhat dilated, sacculated, and indurated. Another branch crossed over the anterior surface of the right ventricle towards its apex: an inch of the commencement of this was diseased; to this portion succeeded an inch that was healthy; and to this again succeeded two inches in which the artery was thickened, sacculated, and from a quarter of an inch in thickness downwards. From this diseased portion sprang three branches, each of which was diseased in the same way for a length of from half an inch to an inch. The trunk of the right coronary artery presented three or four aneurisms from the size of a pea downwards; and at the right margin of the heart it gave off three

branches on to the surface of the ventricle, which were sacculated for about an inch of their length.

Several branches were traced, both from the left and from the right coronary arteries, on to the surface of the auricles; and were found to be diseased in the same way as those on the surface of the ventricles, but to a less degree.

Under the microscope, the buff-coloured coagulum occupying the aneurismal pouches was found to present the usual structure of the laminated coagula of aneurisms; and the walls of the aneurisms consisted, for the most part, of dense fibroid tissue.

The muscular tissue of the heart appeared to be healthy: the valves were also healthy. There was a little atheroma at the commencement of the ascending arch of the aorta. The aorta was healthy, however, in the greater part of its extent; so, indeed, was the arterial system generally.

There were several largish patches of pulmonary apoplexy in the right lung. The liver and spleen were considerably congested. The kidneys were of natural size, but the cortical substance of each was thickly studded with buff-coloured patches, and with dark red coloured masses, which were shown pretty conclusively, by microscopic examination, to be due to hæmorrhage, occurring at different times in different situations. The brain and spinal cord were healthy.

The above case is interesting, 1.—As affording a specimen of what appears to be of very rare occurrence, *viz.*:—aneurism of the coronary arteries. The aneurisms were small, it is true, but they were numerous, and they were not really small in proportion to the size of the arteries in which they originated. They exhibited, however, on a small scale, all those characters which are observed commonly in aneurismal dilatations connected with large arteries, so that their nature was unquestionable.

It is interesting, 2.—As an example of the existence of partial arterial disease. Here the coronary arteries were extensively diseased, while all the other arteries in the body were healthy. This, however, is a phenomenon which is really of more frequent occurrence than might be supposed: and this fact may be ad-

vantageously borne in mind in the treatment and prognosis of disease of the arteries. Dr. BRISTOWE, 1*st of April*, 1856.

---

14. *Aneurism of the Aorta compressing the Pulmonary Artery and causing Death by Angina Pectoris.*

This specimen, which had been removed from the body of a soldier, was chiefly interesting on account of the mode of death which it had caused. The patient had died in a well marked paroxysm of angina pectoris. At the autopsy the only important disease found was an aneurism of the ascending part of the aorta, which opened by an irregular aperture capable of admitting the top of a finger just above the left curtain of the semilunar valves. The sac of the aneurism was bilocular, and embraced the pulmonary artery just above its origin in such a manner that when distended it must have occasioned compression of the latter. Each part of the sac was capable of containing a small chestnut. In most parts the sac was thickly lined with laminated coagula; but at one spot in the front loculus they were thinned down until little more than the reflected serous membrane appeared to exist. The coats of the aorta above the aneurism were extensively affected by atheromatous deposit. The coronary arteries were, as far as could be made out, healthy.

The specimen had been sent to Mr. Hutchinson from Gibraltar, by his friend Mr. Nesbitt, in whose practice the case had occurred.

Mr. HUTCHINSON, 20*th of November*, 1855.

---

15. *Rupture of an Aneurismal Pouch of the Root of the Aorta. Death by Gradual Hæmorrhage into the Pericardium.*

The specimen consisted of a heart, rather above the ordinary size, having its right cavities and the tricuspid orifice dilated, but without any other noticeable affection of the walls or valves. At the root of the aorta, and to the right of this vessel, projected a dilatation with very thin red walls, equal in size to a small walnut; this was found to be connected with the

arterial tube by means of an opening equal in size to a florin, a little above and behind the opening of the right coronary artery. Although smooth externally, the inner surface of this dilated part was roughened. The innermost coat had given way to a great extent, and the middle coat to a less extent; the latter being thickened, and having the free margins of the outer one adherent to it. The external coat was much thinned; and at one part, where the thinning was the greatest, there existed a small aperture, barely admitting a hog's bristle. This, when recent, had allowed blood to exude so as gradually to fill and distend the pericardial sac, in which it was found clotted when examined shortly after death. The inner surface of the whole of the ascending and transverse aorta was much studded and embossed by opaque yellow deposit; but the aortic valve flaps were unaffected. The right cavities of the heart were full of perfectly fluid blood; the left ventricle was empty, and firmly contracted. A milk-like coloured patch and much fat existed on the heart's surface. The lungs were congested, and there was more than ordinary limpid fluid in the cerebral ventricles, and under the arachnoid; but the vessels at the base of the brain were all natural. The capsules of the kidney, liver, and spleen, were somewhat thickened and opaque; but otherwise the viscera were natural.

The specimen was removed from the body of a man, æt. 46, a waterman, who, whilst performing some slight work, suddenly fell down insensible, and was brought into St. George's Hospital in a quarter of an hour. He died about twenty minutes after being brought in. He appeared to have enjoyed tolerable health previously; but no exact history was ascertainable of what diseases he had been the subject, &c.

Remarks.—Death most probably occurred, not so much from the syncope and loss of blood to the general system, as from the impediment to the due action of the heart, owing to the blood's presence in the pericardial sac. It is not usual to find the root of the aorta so affected without any affection of the aortic valves. Dr. J. W. Ogle, *4th of December*, 1855.

---

16. *Aneurism of the Ascending Aorta, bulging into the Right Ventricle of the Heart, and considerably obstructing the Orifice of the Pulmonary Artery, associated with an Aneurismal Pouch of the Septum of the Ventricle.*

The whole heart was much enlarged, its cavities being all dilated, and the walls of the right ventricle being thickened. The two layers of the pericardium were almost universally adherent. On opening the right ventricle, the endocardium was seen to be very opaque and much thickened; and at the upper and inner portion of the cavity a large aneurismal sac was seen, quite full of firm light coloured clot, which, owing to extensive destruction of the walls of the sac, was freely exposed to the venous blood. This sac so far involved the commencement of the pulmonary artery, that one of the valve flaps and portions of the two others were quite destroyed; and the only passage left for the flow of blood, was an oval kind of chink, capable of being distended so as to admit the tip of the finger. This passage corresponded to the portions of the two valve flaps left uninjured. The tricuspid orifice and valve were healthy. Into the right ventricle also bulged the aneurismal pouch in the septum, situated about half way up the septum. This was about equal in size to a pigeon's egg, and its walls, at its summit, were formed by the mere apposition of the endocardia of the two ventricles, which were very much thickened, but seemed to contain no muscular fibre between them. This pouch contained a very little weak blood-clot. On examining the left side of the heart, the mitral orifice and valve presented nothing unusual. The opening of the pouch in the septum of the ventricles was seen to be of the size of a florin, with smooth edges, but having the thickened endocardium in the neighbourhood much wrinkled. The aortic valve flaps were a little more opaque than usual, but nothing more. In the sinus itself, behind the posterior flap, was the orifice of the large aneurism before described. This orifice was rounded, with even margins, and surrounded by slight atheromatous deposit in the walls of the aorta. It partially involved also the commence-

ment of the left or posterior coronary artery. The contents of the sac almost approached this orifice.

Microscopical examination.—The clot in the aneurism, examined microscopically, showed but few traces of blood globules; it presented mainly a quantity of yellowish amorphous and granular material, with but very little corpuscular arrangement. The muscular tissue of the septum of the ventricles around the aneurismal pouch was considerably altered; the fibres being much converted into fibrous material, and having numbers of granules, and small round and oval corpuscles, about and within them. Otherwise the general muscular structure of the heart was not particularly fatty or altered.

The specimen was taken from a man, æt. 42, in whom also a large granular liver, with firm congested kidneys and congested lungs were found. He had been in St. George's Hospital for some time, suffering from bronchitis, with general anasarca and albuminous urine. He left the Hospital much relieved, but returned after a short time with considerable ascites, as well as the other symptoms. It seemed that he had lived a very intemperate life, and had been the subject of syphilis, for which he had been salivated. When admitted, the dyspnœa was severe, the sputa being thin and scanty. The pulse was ninety-six, and small, but regular. The tongue was flabby and coated. There was a distinct systolic murmur, most audible at the apex of the heart, and a double murmur heard best at the base of the heart, but not traceable along the course of the larger thoracic blood-vessels. The patient obtained relief from the use of elaterium, with other purgatives, the vapour bath, and expectorants; but eventually sank very gradually, and died, the urine having, to a great extent, ceased to be secreted.

The specimen was very like two others shown by Dr. Ogle to the Society, and detailed in vol. iv. of the "Transactions." In one of these, the walls of the aneurism of the aorta were so destroyed that the arterial blood freely mixed with the blood in the right ventricle, the sac being free from coagulum. In the other case the sac was full of coagulum, as in the present, but the walls were maintained entire.

Dr. J. W. Ogle, *4th of March*, 1856.

17. *Case of Dissecting Aneurism of the Aorta.*

The deceased, æt. 51, unmarried, sensitive and reserved, of spare build, and a dingy, unhealthy complexion, was engaged in the duties of an active profession at York. He was very subject to bilious attacks, accompanied with violent headache. He was formerly somewhat addicted to sensual indulgence, but latterly, temperate in all things, save in *despondency*, on account of great reverses suffered during the period of the railway fever. In 1851, he was examined for life insurance, and found healthy.

In March, 1855, Dr. Swaine, who saw him in consultation with Mr. Keyworth, of York, found the area of the heart's dulness increased towards the left and at the base, and the impulse excessive. At the heart's apex a murmur was heard to veil the first sound, whilst at the base, a loud, prolonged whiff overwhelmed the second sound, this latter bruit being heard still more distinctly at mid-sternum, at which point there was neither dulness on percussion, nor thrill perceptible. Dr. Swaine interpreted these physical signs, with which the general symptoms appeared to correspond well, as denoting insufficiency of the mitral valve, some obstruction at the aortic orifice, with great insufficiency of the aortic valves, and consecutive eccentric hypertrophy of the left ventricle of the heart. In the main, this opinion corresponded with that previously arrived at by Mr. Keyworth.

The case was subsequently examined in town by Dr. P. M. Latham, who found reason to believe that, in addition to the manifest disease of the heart and its valves, there existed also disease of the aorta.

On the 21st of September, 1855, at midnight, Mr. Keyworth again requested Dr. Swaine to see the patient. He was then lying on his back in bed, bathed in a clammy perspiration, with an exsanguine countenance, indicative of great anxiety and distress. He complained, in hurried accents, of a dull, heavy pain within the thorax, extending inwardly from nipple to nipple, and, further, of a sense of weight and aching somewhat below and to the left of the umbilicus. He had but

partially rallied from a state of collapse, and Mr. Keyworth drew attention to the remarkable fact that not only had the lower extremities failed to participate in the reaction, but also that neither in the femoral arteries nor in the popliteal, was any pulsation discoverable. Mr. Keyworth had been in attendance since ten P.M.

The patient, whose intellect was clear, related that, during the day, he had ascended a hill on foot, under a burning sun, dined heartily at a friend's house, and afterwards returned to York, partly on horseback and partly by train. Walking home from the York station, he was, in front of his own house, seized with a sudden and violent pain, "as though," to use his own words, "his chest were torn open from side to side by some outward force." It was instantly followed by a second "agonizing" pain, which seemed to dart from mid-sternum down the left of the spinal column, and only to be arrested a few fingers breadth below, and to the left of, the umbilicus, at which point of arrest he (the patient) *thought* he could *hear* a distinct crack. The next, almost a simultaneous, occurrence was loss of power in the left inferior extremity, and very soon after in the right also. Carried into his house, for a brief interval he became bereft of consciousness; but not until after a repetition of the lacerating pain, referred, this time, not to the anterior, but to the posterior part of the thorax, from scapula to scapula. On recovering consciousness, he vomited his still undigested mid-day meal, and felt relieved thereby. Mr. Keyworth now arriving caused him to be undressed and carried to bed, where a judicious use of diffusible stimulants was resorted to with the aforesaid partial success. Meanwhile the kidneys acted copiously, the urine being clear and of a pale amber-colour.

Dr. Swaine, who had not examined the patient again since March, found the cardiac sounds hardly at all changed from what he recollected them to have been at that period. Over the track of the aorta, however, two fingers breadth *above*, but to the left of, the umbilicus, there was an audible bellows murmur (under even a lightly pressing stethoscope) accompanying each systolic action of the heart. Two or three fingers breadth

below this point, all pulsation had ceased, whilst a little lower still, at the part where the aorta should bifurcate into the common iliac arteries, a tumor, the size of a goose's egg, and of doughy hardness, could be distinctly felt.

Taking this extraordinary, and withal very marked train of symptoms, in connexion with the previous and present signs of cardiac disease, Dr. Swaine did not hesitate to express his conviction that a circular or transverse rupture had taken place of the internal and middle coats of the aorta, near its cardiac orifice, and that the blood-stream, partially diverted from its natural channel, had dissected for itself a false passage between the middle coat and the external fibro-cellular sheath of the artery; that, meeting with an impediment to its progress in the diverging iliacs, it had there speedily accumulated and become consolidated, so as to compress and obliterate the true calibre of the aorta itself, and to arrest the circulation at this point; in short, that the case was one of so-called *dissecting aneurism.* This explanation, suggested at once by Dr. Swaine in all its details, was readily adopted by Mr. Keyworth. Under all the circumstances, it was natural to look forward to a fatal termination of the case within a very brief period. Complete rest and abstinence were recommended in the first instance.

On the 22nd of September (the following day), the physical signs all continued unchanged. Considerable general reaction had, however, taken place. The thoracic and abdominal viscera, and even the brain, manifested much congestion. The countenance was flushed, the skin partially hot, the pulse quick and bounding, the carotids labouring; the bowels constipated; the urine copious, but deeply coloured, and intensely acid. The patient complained much of headache; of a dull throbbing pain behind the sternum, beneath the right clavicle, and in both arms; and, lastly, of a sense of weight and oppression over the upper part of the abdomen, and at the seat of the abdominal tumor already adverted to.

Here was a state of congestive reaction, obviously due, in a great measure, to the sudden and excessive limitation of the sphere naturally allotted to the blood-stream. Venesection was

urgently required. It was delayed, however, for another day, in deference to the prejudice of friends, and an abortive attempt made, in the meantime, to relieve the pain by local depletion. On the 23rd of September (the third day), the symptoms continuing unmitigated, about twelve ounces of blood were withdrawn from the left arm, with marked and permanent relief to the sufferer. The blood itself yielded a large proportion of coagulum, and a flabby, dingy, honeycombed crust. No attempt was made to operate upon the bowels until the fifth day, when a full dose of castor-oil produced one very copious and well conditioned motion.

From this time the general symptoms began to mend, the appetite and strength slowly to return, the lower extremities to recover a fair amount of warmth, and also of power. Still, the femoral arteries continued to fail in their office, and they could now be detected and traced, in their natural course, in the shape of hard fibrin-filled cylinders. The bellows sound above and to the left of the umbilicus was less intense; the tumor diminished in size, although still palpable, and still sensitive upon deep pressure. Three weeks later, the patient felt well enough to drive out in an easy carriage. But as the winter approached he again began to droop. He caught cold. Cough, with rust-tinged expectoration, was followed by pleural effusion on the left side, and, eventually, by general anasarca. His sufferings were great and protracted; nor was he released from them until the 21st of December, exactly three months from the period of his violent seizure.

Examination thirteen hours after death.—Both lungs much congested, especially the left, which also presents patches of emphysema.* Heart, very large, firm, and heavy. Ventricles, filled with dark grumous blood. Cavity of the left ventricle not inconsiderably dilated, its walls of enormous thickness, the cut surface being of a dingy russet colour, very compact, and appearing to the naked eye as if bereft of much of the natural fibrous structure. Both the mitral and aortic valves are "insufficient" to prevent the reflux of fluid through them.

* The left pleural sac contains about thirty ounces of pink serum.

The former is essentially thickened at its margin; the latter, not thickened, but, on the contrary, attenuated, and eroded, patchwise, on their arterial surface. Both the semilunar valves and the commencement of the aorta are much distended, and seem to have lost their contractile power. A few lines below the point where the left subclavian artery is given off, (*see* Plate V.) a transverse or circular rupture of the middle and internal coats of the aorta has taken place,* leaving the inferior portion of the artery attached to the upper portion only by about one-sixth of the circle at its posterior part. The edges of the rupture are partly smooth, as if cut with scissors, partly jagged and reflected (*d*, *e*,). From the ruptured part downwards, the fibro-cellular sheath of the artery (*f*, *f*, *f*,) has (with the exception of its posterior part, which is still adherent) widely separated from the middle coat, the interspace presenting, along its entire length, a succession of little flattened blood-clots, some of which cohere, through the medium of lymph-shreds, with the inner surface of this fibro-cellular sheath. At the bifurcation of the oarta into the common iliac arteries is found, impacted between the external and middle coats, a russet-coloured, hardened, fibrinous coagulum, (*k*,) as big as a rook's egg. This coagulum has, on the one side, become partly organized and adherent to the fibro-cellular sheath; whilst, on the other side, it firmly and thoroughly compresses the true canal of the aorta. Below this point of compression, the left common iliac artery presents a firm cord (*m*,) and, on incision, a compact hard cylinder of brown fibrin (*n*,). The right common iliac (*l*,) is pervious, and contains some dark fluid blood. From this artery a common slate pencil could, without much difficulty, be passed into the

* Some doubt having been expressed at the meeting of the Society, by Dr. Peacock, as to whether the effusion of blood had taken place in the substance of the middle coat of the vessel, or, as described by Dr. Swaine, between the outer and middle coats, Dr. Swaine has carefully re-examined the preparation, and finds that, "with the exception of a few small delicate patches of the external layer of the middle coat, torn away by the cellular sheath in its forcible separation," the above description as first given is quite correct. He adds that this morbid condition is in accordance with the experience of Rokitansky, as stated in his late work on "Diseases of the Arterial System."

DESCRIPTION OF PLATE V.

The drawing (reduced one-half the size of the specimen) illustrates Dr. Swaine's and Mr. Keyworth's case of Dissecting Aneurism of the Aorta, p. 106.

A. Portion of the arch of aorta cut open and spread out.

a. Arteria innominata.

b. Left carotid.

c. Left subclavian.

d. Upper edge of the transverse rupture of the aorta.

e. Lower edge of ditto, partly reflected back.

f f f. Fibro-cellular coat of the aorta, longitudinally incised and laid open, displaying many adherent blood-clots, and exposing the tube of the aorta, covered by its elastic coat.

g. Cœliac axis, cut.

h. Superior mesenteric artery.

i i. Renal arteries.

k. Obliterated inferior mesenteric artery.

l. Hard fibrinous clot, partially organized, and compressing the aorta above its bifurcation.

m. Right common iliac. The probe is passed through the communication of this with the canal of the aorta.

n. Left common iliac, partly cut open, showing

o. The hard cylinder of fibrin or thrombus, completely obliterating its canal.

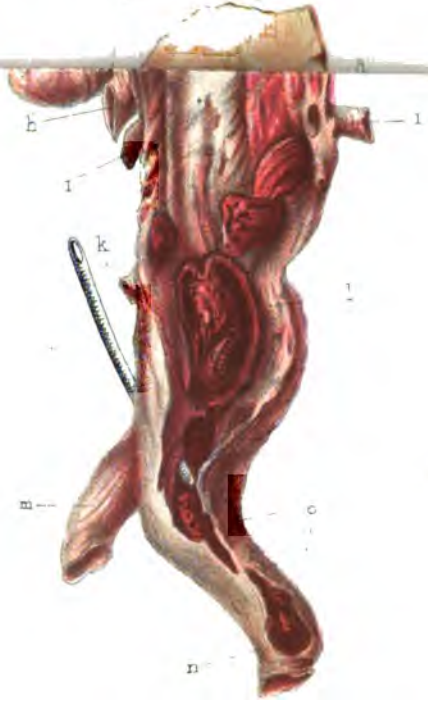

J. W. West Bromsgrove Imp.

W. West lith.

aorta at the point of its compression. (*Latterly*, Mr. Keyworth had again detected slight pulsation in the *right* femoral artery). Several of the intercostal arteries appear injured. The cœliac axis (*h*), the superior mesenteric (*i*), the renal arteries (*g*, *g*,), are severally in good condition; the inferior mesenteric, (*j*,) obliterated. The old canal of the aorta is replete with dark *grumous* blood. Its internal surface, or inner coat, presents numerous patches, smaller and greater, of atheromatous degeneration in its various phases, up to the condition of semi-cartilaginous hardness.

The parietal portion of the peritoneum below the umbilicus has, in a marked degree, the dark slate-like tinge of pigment. The abdominal viscera appear congested, but not otherwise notably diseased. Even the kidneys exhibit no traces of actual degeneration. Unfortunately neither time nor permission could be obtained for attempting to track the collateral circulation set up for the supply of the parts below the range of the aorta itself.

Dr. LATHAM, for Dr. SWAINE, 20*th of May*, 1856.

---

18. *Blocking up of both Internal Carotid Arteries by Coagulum, and consequent Death.*

S. T. æt. 23, was admitted into Elizabeth's Ward, at St. Thomas's Hospital, under the care of Dr. Peacock, on the 15th of December, 1855. She was a single woman, and had come to town from the country in 1849. Soon after this, catamenia became suppressed, and suffered from headache, and had a fit, and she has been repeatedly under treatment for pains in the head since that time. In 1853 she had another fit; both of these attacks seem to have been of an epileptic character, and in neither instance were they followed by any paralytic symptoms. In September, 1854, she had a severe attack of diarrhœa, and in November she came under Dr. Peacock's care as an out-patient for a secondary sore throat, and an eruption on the skin. These continued till the month of April, 1855, after which she had no medical attendance till the following October, when she again applied at the Hospital, suffering under

dyspeptic symptoms, with irregularity of the catamenia, headache, and threatenings of phthisis. She was at the Hospital on the 7th of December, and after returning home, complained of more severe pain in the head, and continued to do so till the 11th; on that morning, as she did not get up at the usual time, her friends went to her room and found her partially insensible, incapable of speaking distinctly, and paralysed on the left side. She was admitted into St. Thomas's Hospital, under Dr. Peacock's care, on the 15th. She was then partially conscious, but was incapable of speaking clearly, or more loudly than whisper. The pulse was ninety-six, and feeble; tongue clean; bowels confined; pupils rather large. She was paralysed on the left side, the mouth deviating to the right, and the left limbs were entirely powerless. She was directed to have a blister applied at the neck, to take a calomel and colocynth pill, and to have a terebinthinate enema.

The following day the bowels had been freely relieved, and she was more intelligent, spoke more distinctly, and in a louder voice. She was, however, very much prostrated; a slough was found to have formed on the nates, and there was a large excoriation, apparently produced by some ammoniacal preparation, on the side of the left thigh. She was directed to have three glasses of wine daily, and to take five grains of the sesquicarbonate of ammonia, with one drachm of the compound tincture of bark, in an ounce of the decoction of bark, every four hours.

On the morning of the 18th, she had another fit, in which she was violently convulsed, and afterwards became comatose. For the remainder of her life she was quite insensible, and had the left limbs rigid and the right relaxed, with occasional slight voluntary motion in the right arm. She died at six A.M. on the 19th.

She had a sister who died in an apoplectic fit.

Post-mortem examination.—Body in tolerably good condition.

The calvaria was healthy, but the subjacent dura mater was a good deal congested. The convolutions of the upper surface of the cerebrum were flattened, the spaces between them obli-

terated, and there was scarcely a trace of the subarachnoid fluid. The larger superficial cerebral veins, especially those in the posterior region, were distended with blood. In addition to a general pink tinge of surface, there was intense congestion of the minuter visible vessels ramifying on the convolutions. These appearances extended over the whole of the upper surface of the hemispheres, but were most marked on that of the right, especially so anteriorly, and along the falx major. On removing the brain, it was observed that the dura mater lining the base of the skull, with the exception of that part occupying the posterior fossa, was more congested than natural, and also that the convolutional congestion and flattening extended over the whole surface of the cerebrum; the congestion, however, being most marked in the anterior half. The surface of the cerebellum was not at all congested, and was apparently perfectly healthy. There was an almost total deficiency of subarachnoid fluid, and no fluid was discovered at the base of the skull. On making sections of the cerebrum, its white substance was found to be very considerably congested throughout. The lateral ventricles were normal; their parietes were neither congested nor softened, and they contained only a small quantity of healthy-looking serum. The anterior lobe of each cerebral hemisphere was decidedly softer than the posterior half; and this softening, which was but slight, extended back in the right hemisphere as far as its centre, being most apparent in its convoluted portion. The right corpus striatum, and the brain substance below, and in front of it, were decidedly softer than the corresponding parts on the left side, and somewhat softer than any other part of the brain; and their sectional surface presented a little patchy redness, which, though not in itself well marked, was very apparent by contrast with the condition of parts on the opposite side. The optic thalami, adn other ganglia, were healthy; as, also, was the cerebellum, and all parts connected with it.

The softening above described was nowhere very great, for the affected portions of the brain were not disturbed by allowing a stream of water to play upon them. The softened and the healthy parts passed insensibly into one another.

There was no tubercle and no deposit of lymph or pus in any situation.

The arteries at the base of the brain were in an unhealthy condition. The vertebrals, the basilar with its branches, including the posterior communicating, were perfectly healthy, pervious, and empty of clot. The right internal carotid, and the right anterior and middle cerebral arteries, were, for some part of their extent, plump and distended, contrasting remarkably with the healthy vessels. This distension occupied the whole of the internal carotid, from the point at which it quitted the cavernous sinus to its division, and extended along the middle cerebral for about a third of an inch to the origin of its first branch, and along the anterior cerebral for a quarter of an inch. On laying these vessels open, their enlargement was found to be due to a softish coagulum of a uniform light pink colour. This completely filled them, was adherent in its whole extent, and presented, at both its proximal and distal extremities, a rounded end. Beyond the coagulum, just described, there was no clot or blood in any form found in these arteries. Their parietes, even those portions to which the coagulum was adherent, appeared to be perfectly healthy.

The left internal carotid artery and its anterior and middle cerebral branches were also diseased, and to the same extent, but their condition was different. The internal carotid, from the cavernous sinus to its division into branches, was contracted, and its channel filled by an opaque white membranous formation, which was so blended with the parietes, that it was difficult, if not impossible, to distinguish them from one another. This adventitious structure was prolonged for about a quarter of an inch along the middle cerebral artery, and at its distal extremity formed a hollow cylinder adherent to the parietes, and with difficulty separable from them. It extended also for about a quarter of an inch along the anterior cerebral. This vessel, at its origin, was much contracted, and again where the diseased condition terminated; and between these points, it formed an opaque, yellowish-white enlargement, about the size of a grain of wheat. On section, this was found to contain a cavity filled with thick pus-like fluid, which was circumscribed

by deposit, adherent to the parietes, and like that in the arteries which communicated with it. There was no blood in these vessels, and their walls beyond the seat of disease were healthy.

Microscopic examination.—The coagulum in the vessels of the right side presented a tolerably uniform structure. It consisted of a delicately fibrillated material, nearly exactly like that constituting ordinary fibrinous coagula, in the meshes of which was an abundance of roundish corpuscles, about the size of pus-cells (Fig. 4 A.). These were thin-walled,

FIG. 4.

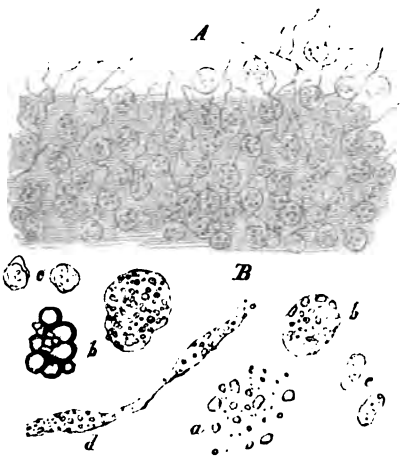

A Fibroid network and cells from the arteries of right side. Magnified 420 diameters.

B Constituents of the fluid in left anterior cerebral artery. Magnified 420 diameters.

a Oil and molecular matter.

b Compound granular cells, &c.

c Cells broken down and collapsed.

d Fragment of fibre studded with oil.

and studded with minute refractive particles, but were unacted on by acetic acid, and hence differed from pus and the

ordinary white corpuscles of the blood. There were also a good many blood corpuscles. There was no difference of character observed between the interior and the surface of the clot. The parietes of the vessels to which the clot was adherent were perfectly healthy in structure, but numerous corpuscles, together with the fibrillated material, adhered to their lining membrane.

The pus-like fluid from the cavity in the left anterior cerebral artery presented numerous refractive globules, varying from mere points up to the size of a blood corpuscle (Fig. 4 B.). In many instances, these were collected into round or ovoid masses from the $\frac{1}{300}$th or $\frac{1}{400}$th of an inch in diameter downwards (Fig. 4 B.). In some cases a distinct membranous wall was detected, partially or wholly investing these masses, but generally none was to be seen, and frequently the masses were defective or broken. Many of the refractive bodies were so large and variously shaped, that they looked like earthy concretions; but as few, if any, were affected by acetic acid, and as the majority were soluble in ether, the chief constituent was evidently oil. Besides the above there were numerous nuclei, having a resemblance, so far as regards size, to those observed in the clot on the right side, but they were irregularly shaped, broken, and contained more and larger refractive granules; but, probably, were similar bodies to those alluded to, broken down and degenerating (Fig. 4. B 2.). There were also numerous fragments of fibroid tissue, more or less studded with oil (Fig. 4. B 3.). The membranous formation that occupied the arteries of the left side presented similar microscopic characters to those of the fluid, but there was a much greater proportionate abundance of degenerating fibroid tissue.

The substance of the brain was examined carefully—portions from corresponding situations on the two sides were examined and compared, and the softened brain structure was compared with that which was apparently healthy; not only was no difference found between them, but no abnormal condition was detected anywhere.

Chest.—Pericardium and heart healthy. There were no vege-

tations on the valves, and no sign of disease in them, or on any part of the endocardium. There were no old clots in the cavities. Aorta healthy. Pleura healthy. Lungs of moderate size, crepitant throughout, and somewhat congested posteriorly. There was a little emphysema along the anterior margins, but no tubercular or other deposit at any part. The bronchial mucous membrane looked healthy. The tubes presented their normal calibre, but contained a large quantity of white, opaque, muco-purulent fluid.

The abdominal viscera were all perfectly healthy.

The above case is of interest, as affording an example of obstruction of one of the internal carotid arteries and its branches by a recent coagulum. And its interest is increased by the fact of the opposite artery and its branches being blocked up by a deposit which, both from its resemblance in structure to some forms of transformed clot, and from the history of the case, had in all probability been originally a similar coagulum, produced by like causes.

With regard to the recent clot, it clearly was not a foreign body from the heart or any other source, neither had any such body acted as its nucleus, for nothing of the sort could be detected. It could scarcely have depended on any unusual condition of the blood, for had that been the case clots ought to have been found in other situations, yet none were met with. It would seem, therefore, that it must have been produced by some local cause, and probably by an inflammatory condition of the artery at the point of coagulation. That such was really the origin is rendered probable by the resemblance of this case to those which occasionally occur, in which, after manifest inflammation in the course of the arteries of one or more of the limbs, with consequent gangrene, the affected portions of the arteries are found after death to be blocked up by adherent coagulum. The characters of the clot itself are somewhat favourable also to this view, for, although the greater part of it consisted simply of coagulated blood, there was mixed with this a large number of corpuscles, which were not a normal constituent of the blood, and though not pus, were probably the result of the inflammatory process.

The softening of the brain was probably due to deficient supply of blood, and was, in fact, most likely the commencement of gangrene.

Dr. PEACOCK and Dr. BRISTOWE, 15*th of January*, 1856.

---

19. *Obstruction of the Middle Cerebral Artery by a Fibrinous Plug, in connection with Vegetations on the Aortic Valves.*

This specimen of obstruction of the middle cerebral artery was taken from a patient, æt. 37, who was admitted into the Middlesex Hospital with cancer of the uterus of six months duration. A week after admission she was seized with a pain in the left temporal region, which lasted half an hour; she then suddenly lost the use of her right side, but retained her consciousness. She was also able to move the mouth, but not to articulate: pulse eighty. During eight days she remained nearly in the same state. She then became free from pain (excepting a slight headache), and was able to answer questions slowly, but did not regain the power over her side. She next gradually passed into a state of complete listlessness; the cancerous disease advanced slowly, and now extended to the lumbar and inguinal glands, which became much enlarged, and produced considerable pressure on the great vessels in the groin. Gangrene of both feet and of the nose took place about a week later; and death put an end to her sufferings twenty-two days after the sudden headache followed by paraplegia (Plate VI. Fig. 1*c*.).

On examination, the left middle cerebral artery was found obstructed at its very origin by a triangular-shaped fibrinous plug (Fig. 1*e*.), which sent one small angular process into the anterior cerebral artery, partly occluding it; another angular process projected into the middle cerebral artery; the greater part of the plug being really seated exactly at the bifurcation of the carotid, into which artery the third largest angular projection was directed. The sketch (Plate VI. Fig. 1.) exhibits the exact size and appearance of these parts.

About one inch from its origin, the middle cerebral artery gave off a large branch; and here there was found another little

plug (Fig. 1*f*.), of smaller dimensions, but in other respects exactly similar to the one just described, the trunk of the artery beyond this point being filled with a slightly coloured fibrinous clot, nearly half an inch long, which was connected with the little plug, but presented a less dense appearance. The space between the two plugs was empty, and there was no adherent lymph about the arteries involved. The substance of the brain felt rather flabby, but was not decidedly softened. The arachnoid was raised up by serous fluid, and about one ounce of serous fluid was found in the base of the skull.

The lungs were much congested posteriorly, and a portion of the lower lobe of the left was solidified, and of a dark reddish-brown colour. The pericardium contained about one ounce of pinkish purulent serum, and a few flakes of recent lymph. The heart was flabby, and slightly enlarged. Warty vegetations, the size of peas, were found on all the aortic valves; they were rough, pointed, and not very adherent. Similar vegetations also existed on the auricular surface of the mitral valve. The internal surface of the left ventricle presented a mottled appearance, produced by yellowish elongated spots or streaks visible through the endocardium, varying in size, sometimes involving one of the columnæ carneæ throughout its entire extent. At the cut edge of the ventricle, these yellowish patches presented a fibroid appearance, and were surrounded by a darkened outline, the adjoining heart substance being softer than natural. The greater part of the papillæ to which the chordæ tendineæ of the mitral valve were attached, was converted into yellowish fibroid tissue. The muscular fibres of the heart did not appear much changed: the transverse striæ were generally visible. Portions taken from the fibroid patches exhibited a molecular deposit occurring between the muscular fibres; and some of the fibres themselves appeared to contain a very fine molecular matter. The spleen presented three or four purulent spots containing small sloughs. The examination of the other viscera, &c. yielded no evidence of disease connected with the phenomenon above described.

Dr. Van der Byl, *4th of December*, 1855.

Report on this specimen.—The specimen consisted of a small portion of the left carotid and posterior communicating arteries, with about one inch of the anterior cerebral artery; and somewhat more than this length of the middle cerebral artery. The specimen had been preserved about a fortnight in spirits of wine. The carotid, middle cerebral, and a small part of the anterior cerebral arteries had been previously opened.

At the termination of the carotid, and just at the junction of the middle and anterior cerebral arteries, there lay a small body of a pale, slightly yellowish-grey tinge. On pressure it was about as firm as old decolorised fibrin, or as moderately firm vegetations sometimes attached to the valves of the heart: it was in no part gritty. In shape it was, as well described by Dr. Van der Byl, somewhat triangular, but the sides of the triangle were not flat: it appeared to be, as it were, composed of three somewhat cylindrical portions united together at a common central point; or, in other words, three nearly cylindrical rami branched from a common centre in three different directions. One of these rami (the thickest of them) was extremely short, and formed little more than a slight projection from the point where the other two rami joined each other: these last named rami were notably larger than the other one. The extreme length of the small body was nearly three-tenths of an inch; and each one of the two longer rami measured fully one-tenth of an inch. When examined, this body was entirely free from any attachment to the walls of the artery; it lay exactly at the point where the carotid divides into the middle and anterior cerebral arteries in such a manner, that its very short, but thick ramus, looked towards, or was seated in, the carotid; while each of the two larger rami projected and fitted closely into the commencement of the middle and anterior cerebral arteries respectively.

But further on, in the middle cerebral artery, there was found another body of a somewhat similar kind. It was, for the most part, a simple solid cylinder, rather more than four-tenths of an inch in length; and about one twelfth or one fifteenth of an inch in diameter. It was, therefore, considerably less in diameter than either of the rami of the other body

already described. Its diameter corresponded with that of the portion of the middle cerebral artery in which it lay: its proximal extremity reached just to the point where the middle cerebral artery gives off its first branch: to a point, therefore, nearly half an inch (four-tenths of an inch exactly) from the extremity of this ramus of the first described body, which projected into this artery. At the very commencement, however, of this second body, its form was not perfectly cylindrical, for there was a small prominence, or minute ramus, which projected exactly in the direction of (and when the preparation was *in situ*, probably just entered) the first branch of the artery. The whole of this second body was one continuous mass, but it was slightly more dense and compact at its proximal, than at its distal extremity: at the former it was, apparently, of the same firmness, and structure, and colour, as the first body; towards its distal extremity it was somewhat less compact, and presented, likewise, a very slight reddish tint. This body was not adherent to the walls of the artery.

The question was, to determine whether or not the small body found in the artery had been originally one of the vegetations (of which there were several) on the valves of the heart, carried to the position in which it was found by the current of the blood.

1. To assist in determining the point, portions of one of the vegetations from the heart were examined microscopically, as was also a portion of the first described body. They were found to present similar appearances, and to consist chiefly of granular fibrin; but a portion of the second (or more distant) body was also examined, and it likewise presented identical appearances, except that towards its extreme or distal end, where it was a little softer than elsewhere, the granular matter appeared to be less firmly aggregated.

2. It would be a remarkable circumstance if the vegetation removed from the heart and carried up to the head should be bifurcated, so as exactly to fit in the commencement of the anterior and middle cerebral arteries, and in the way the first described body did. It is true that a portion of soft or plastic fibrin might, by the force of the current, be moulded into such

a form, but the vegetations found on the valves of the heart were as firm as the body found in the artery. And it is a question whether it is not more probable that the *vis à tergo* would force a mass of vegetation (granting it to be removed from the heart and very soft) into some one artery till it could, owing to its size, proceed no further—rather than that it should mould it so as to fit the point where an artery divides into two branches.

3. The probability that the first or triangular body was thus carried from the heart by the force of the circulation, seems much diminished by the fact that a second body, of a similar kind, was discovered very near the first one, and that the second body presented a small prominence or ramus projecting towards (and probably, originally, into) a branch of the artery in which it was situated: while, on the other hand, no other such like body was found elsewhere in the brain. According to the doctrine of chances, the probability is very small indeed that the two bodies should be found at the same part of one side only of the brain, unless there were some local cause for their being there.

4. The similarity of the microscopical appearances of the cardiac vegetations and the bodies in question is no proof in either direction, as the one and the other would, under any circumstances, probably (as fibrinous deposits from the blood) present similar appearances.

5. The very elongated form of the second body (which was absolutely distinct from the first one, and far separated from it, so that it could not be simply a clot formed in consequence of the plugging up of the artery by the first body) was very unlike any kind of vegetation which would be removed from the heart. Dr. HARE, 18*th of December*, 1855.

---

20. *Case of Aneurism of the Basilar Artery, associated with total Deafness.*

This specimen of aneurism of the basilar artery was taken from a woman who was admitted into the Middlesex Hospital for retention of urine. Her history is briefly as follows :—

A. F. æt. 53, married for twenty years, has had no family, formerly stout, now thin, of irregular habits, but naturally of good constitution; complexion sallow, hair brown, eyes light hazel. About four or five years ago she became suddenly deaf; and since that time there has been a total absence of hearing. She continued in her usual health, and went about until two years ago, when she had an apoplectic seizure, attended with inability to articulate, loss of consciousness and stertor, with loss of power of the left side. Two similar seizures took place in the course of the two following months; but she was able to walk about with some assistance and support shortly after each attack. The power to help herself gradually diminished till six weeks before admission, since which time she has been confined to her bed, and troubled with a gradually increasing dysuria, which at length amounted to retention, for which she was brought to the Hospital. On admission, appetite was bad; tongue, when half protruded, deviated to the left side—when fully protruded was in mesial line; pupils of natural size, and sensible to light. At first she said that her bowels were regular; but a few days after admission she stated that they had not acted for nearly fourteen days. Free action was then obtained by aperients, which were afterwards administered from time to time. She only required the use of the catheter once, and subsequently passed urine in good quantity, and without difficulty or pain. She was cheerful and contented, though so deaf that she could not, with either ear, distinguish a single word, even with the aid of a trumpet.

Her general health having much improved, she was to have been discharged on the fourteenth day after admission; but her friends not having made the requisite arrangements for taking her home, she was not removed on the day ordered. In the evening of that day, (at six, P.M.) after taking a cup of tea, she uttered a sudden scream, and became immediately unconscious. When seen shortly afterwards, her pulse was very slow, respiration almost suspended, the interval between each inspiration being very long, and death seemed impending. Under the use of the electro-galvanic apparatus, however, she slowly rallied;

and at the end of three hours, during which galvanism was assiduously employed, the breathing, though heavy, became natural in frequency, and the heat of surface was restored. The pupils were much contracted, and insensible to light; the arms rigid, and the fingers contracted: there was a slight voluntary motion of the lower extremities. Mustard poultices to the neck and turpentine injections were also employed; but the coma increased, and she died the following day.

Post-mortem examination.—Body well developed and stout. On removing the dura mater, the convolutions were found extremely flattened and pale; on lifting the anterior lobes, a clear serous fluid squirted from the base of the brain, through an opening between the crura cerebri. The upper portion of the hemispheres being removed, the lateral ventricles were found greatly dilated, and must have contained about six ounces of serum, the greater part of which had escaped through the floor of the third ventricle. The brain substance was quite firm; the pons Varolii was covered in different parts by a quantity of black coagula, which even surrounded the upper part of the medulla oblongata. On removing some of the coagula, a small aneurism, about the size of a hazel nut, was discovered on the basilar artery, at about the middle of its course. It was unfortunately cut into by a student in the removal of the brain, but the coagula had evidently been produced by rupture of this aneurism, and hence the sudden death. The heart weighed nine ounces, was rather soft, and contained black coagula. The valves were healthy, excepting a few specks of atheroma on the mitral valve. The examination of the other organs may be omitted here, as not directly connected with this specimen.

We were anxious to know the condition of the internal ear, and to trace the course of the total deafness. I removed both the temporal bones entire; and the organ of hearing was carefully examined by Mr. Toynbee, who informs me that "the only pathological condition found was an atrophy of each auditory nerve." From the position of the aneurism, I am inclined to think that this atrophy was produced by obstruction of one of the small branches of the basilar artery which enters

the meatus internus and supplies the auditory nerve, and not by any pressure on the auditory nerve itself.

Dr. Van der Byl, *7th of February*, 1856.

---

21. *Aneurism of the Middle Cerebral Artery.*

J. L. æt. 57, a shoemaker, was seized with an epileptic convulsion in the latter part of the year 1855; indistinctness of speech and some loss of power on the left side resulting, but recovering both functions some time after. December 24th, 1855, he had a second seizure, and was admitted into the St. Marylebone Infirmary in a state of epileptic coma; pupils dilated; speechless; breathing easy, and pulse natural. Aperient medicine was given and a blister applied to the back of the neck. Speech returned imperfectly on the 26th, and it was then found that he could not move either hand or foot on the left side; sensation was present, though, perhaps, somewhat impaired; he improved gradually, regaining his speech and the perfect use of the left side, when, on the evening of the 5th of January, 1856, he had another convulsive attack, accompanied with a shriek, and died almost immediately.

I am indebted to Mr. Maurice G. Evans, under whose care the patient was while in the Marylebone Infirmary, for the above particulars, and for the opportunity of the *post-mortem* examination.

Autopsy.—Head.—Vessels of the pia mater much congested. Arachnoid very opaque and thick at some points; where transparent, as over the lateral aspect of the hemispheres, yellowish serum is seen beneath.

On removing the brain all the cerebral arteries were found so atheromatous as to form rigid tubes. The atheromatous deposit was thick and resistant, not gritty or earthy, and extended into the smaller divisions of the vessels; but few points could be observed free from it except in the vertebral and basilar arteries. The intra-cranial portion of the internal carotid and the middle cerebral arteries were perhaps most affected.

On the right middle cerebral artery, within the fissure of Silvius, at a point where two branches are given off, is seen a

complete aneurism, the size of a horse bean, measuring half an inch from base to apex, and three-eighths of an inch across (Fig. 5); it was quite entire. On one face the coats seemed

Fig. 5.

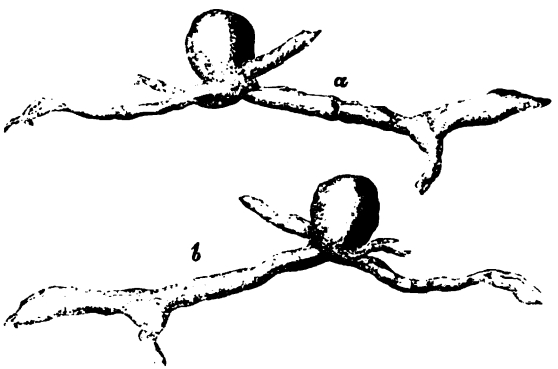

The engraving represents the aneurism of the natural size.
a The superior,
b The inferior aspect.

rather thin, as if the middle atheromatous coat had given way, and on the opposite face there was slight hæmorrhagic staining; it projected more towards the middle than the anterior lobe; there was no abnormal appearance of the meninges or cortical substance in contact with it.

In the substance of the hemisphere anterior to the corpus striatum, and but little above the anterior perforated spot, on the right side, was a cavity lined by a softish layer of a yellowish-brown colour, in which numerous exsudation corpuscles were seen by the microscope. A similar cavity, smaller in size, existed in the corresponding portion of the left hemisphere; its interior was of a brighter colour, nearly pink, and consisted, microscopically, almost exclusively of exsudation corpuscles.

Heart.—Weight, fifteen ounces and a half; hypertrophy with dilatation, the orifices dilated; no deposit in the valves; no

atheroma in the arch of the aorta; none in the external carotid, axillary, or femoral, where examined.

Kidneys.—Left: weight, six ounces and a half, congested, coarse in texture, capsule easily removable. Right: weight, five ounces and three-quarters; part of its outer aspect was in a state of slough; shreddy, softened tissue of a light reddish-brown colour here interrupted the convex outline of the kidney, by forming a depression with a hard base, from which some fibrous looking bands extended inwards towards the pelvis. About one-third of the organ was thus implicated; the remaining portion not abnormal.

Mr. SQUIRE, 21*st of March*, 1856.

---

22. *Aneurism of the Middle Cerebral Artery: Extravasation of Blood from bursting thereof: Death in a few hours.*

The specimen consisted of a brain, with its lateral ventricles, containing several ounces of bloody fluid and coagulum, which had resulted from the breaking down of the outside wall of the left ventricle, and its consequent communication with a large cavity in the substance of the left cerebral hemisphere filled with blood. This cavity was caused by the bursting of an aneurism of the middle cerebral artery, the upper part of which was situated at the lower and outer part of the left corpus striatum, which was greatly broken down by the escape of blood. The nervous structures in the neighbourhood of the aneurism, where broken down, were very shreddy and mixed with blood, but not very softened. The septum of the ventricles was broken down, and their walls generally somewhat softened. On elevating the outer side of the left corpus striatum, the rounded, dark-coloured, and very firm upper surface of the aneurism at the bottom of the shreddy cavity before alluded to, was seen: and at the under surface of the base of the brain, on separating the middle from the anterior cerebral lobe on the left side, the under or lower part of the aneurism, of a peculiar light, almost white, colour, was seen, very firm, and divided into two lobules, a large and a small one, as if by the pressure of one of the branches of the artery.

The entire aneurism was equal in size to a small walnut, and the surface of the cerebral convolutions around it, at the base of the brain, were indented, but not softened by it. The general characters of the brain and skull were not altered in any other way, nor were the arteries at the base atheromatous. Slight pleural adhesions existed, and the lungs were congested. The kidneys were granular on their surfaces. The heart, which was natural in appearance, had both its ventricles quite empty, the left one being firmly contracted. The blood throughout the body was very unusually fluid. All the limbs were rigid when the body was examined, and the pupils were very dilated and equally so. Arcus senilis was very well marked.

Microscopical appearances.—The muscular tissue of the heart was found to be very fatty, though it was firm and consistent, the left ventricular walls being more fatty than the right. The muscles within the orbit were in a highly fatty condition.

The history is very short. The patient, a man of middle age, was brought into St. George's Hospital quite insensible. The pupils were exceedingly contracted, but no stertor, or spasm, or vomiting existed. He had been for some time subject to fits, which generally only lasted a short time, and on the day of his attack he had eaten a comfortable—perhaps too comfortable, a dinner. Shortly after he was attacked by a fit and died a few hours subsequently, remaining until death in the same state as when brought into the Hospital.

Remarks.—The points of interest in this case are:—

1. The permanent contraction of the pupils.
2. The freedom from spasm.
3. The fluid state of the blood connected with the somewhat rapid mode of death, and the emptiness of the heart, with the contraction of the left ventricle.
4. The association of the arcus senilis and the disease of the kidneys and fatty heart, with the absence of any atheroma of the large cerebral arteries.

5. The frequent occurrence of slight fits, and the final attack following close upon a full meal.

Dr. J. W. Ogle, 1*st of April*, 1856.

---

23. *Aneurism of the Posterior Cerebral Artery, forming a Laminated Tumor within the Brain.*

This specimen of aneurism of the posterior cerebral artery, forming a laminated tumor, situated within the substance of the brain, was removed from a man who had fallen down in the streets in a fit, and was brought to the Middlesex Hospital, where he died while in the waiting-room.

Post-mortem examination.—J. E. æt. 56, examined forty-eight hours after death. Body well developed. External surface of the dura mater much congested, the meningeal arteries distended; pia mater much congested; convolutions of the brain flattened; substance pale. On opening the lateral ventricles about one ounce of bloody serum escaped, and black clots were found occupying both cavities, the right ventricle being entirely filled with coagula. The septum lucidum was softened and broken through. On carefully removing the coagula from the right lateral ventricle, an elastic tumor, about the size of a hen's egg, was discovered in the middle, or descending cornu of the lateral ventricle (Plate VI. Fig. 2 *a.*); it seemed attached to the hippocampus major, and growing into the ventricle; the surrounding brain substance was softened and broken up, and presented a yellowish gelatinous appearance, mottled with pink spots. A slight stream of water washed away all the softened brain substance, and left an irregular, rough, villous cavity, in which the tumor remained suspended. On section, this tumor exhibited a laminated aspect, as if composed of concentric fibrinous layers, which differed somewhat in colour, some being dark, others light. On minute examination, the tumor was found attached to an artery (Fig. 2 *b.*) entering the middle cornu of the ventricle, along with the velum interpositum, and on tracing this vessel to the base of the brain, it was found to be the posterior cerebral artery (one of the branches of the basilar), which, after

winding round the root of the cerebrum, entered the brain in the manner just described.

In the preparation I have cut away a portion of the base of the middle and posterior lobes, so that the tumor may be seen from below, and its connexion with the artery be traced. I have also taken a section from the tumor, to show its laminated appearance, which, however, is not so well seen here as in the cut made from above; and from the margin of the section I have carried an incision towards the artery, and lifted up the coat of the aneurism (Fig. 2 *c.*) to trace its continuity with that of the vessel. The opening into the artery (Fig. 2 *d.*) is thus distinctly seen, and there remains no doubt as to the nature of the tumor. In the section a coagulum (Fig. 2 *e.*) is noticed, as it were, applied to the tumor. There must have been a slight rupture and limited extravasation, before the last attack, to account for this.

The extreme rarity of this case induced me to make further inquiries as to the patient's history. I then found that he had been in St. Mary's Hospital three months before death, for an attack of gout. He first attended there as an out-patient for pain in the head, vertigo, and debility, of twelve month's duration, but stated that he never had fits of any kind. Twelve years before this, he first had an attack of gout after exposure to wet and cold during the night when performing duty as a watchman; he was always healthy before that time, but had had constant attacks with small and incomplete intermissions ever since. He has had rheumatic pains in the shoulders and hips; none of his family ever had gout. On admission, his hands were chiefly affected, but he did not complain of head symptoms. He was treated with alkalies and colchicum. In the course of eight days he was again complaining of headache and giddiness, especially when rising from the horizontal posture. These head symptoms increased during the next week, the pain in the vertex became very severe, the face grew sallow, and he complained of pain in the right side of the face, to which he said he had been subject. The gouty pains gradually disappeared under treatment, and on being dismissed from the Hospital, six weeks after admission, he only com-

DESCRIPTION OF PLATE VI.

Figure 1 illustrates Dr. Van der Byl's case of Obstruction of the Middle Cerebral Artery, p. 118.

The parts are represented of their natural size, the arteries being laid open.

a. The small terminal portion of the carotid artery.

b. The posterior communicating.

c. The middle cerebral artery.

d. The anterior cerebral artery.

e. The small fibrinous plug at the junction of the middle and anterior cerebral arteries.

f. A similar body, and a coagulum at the first branch given off by the middle cerebral artery.

Figure 2 illustrates Dr. Van der Byl's case of Aneurism of the Posterior Cerebral Artery, forming a Laminated Tumor within the Brain, p. 129.

The base of the brain is represented, with the right lobe of the cerebellum pushed aside, and a portion of the middle and posterior lobe of the brain cut away. The posterior cerebral artery is seen passing through the great transverse fissure of Bichat; a segment of the tumor is removed to show its laminated structure. The surrounding cerebral substance was in a state of yellow softening.

a. The tumor.

b. The posterior cerebral artery, to which the tumor is seen to be attached.

c. The investing coat of the aneurism.

d. The opening into the artery.

e. Clot attached to the tumor.

f. Right lobe of the cerebellum pushed to one side.

Figure 3 illustrates Mr. Shaw's case of Rupture and Invagination of a portion of the Internal and Middle Coats of the Aorta, p. 131.

a a. Aorta, its coats entire.

b. Line of rupture of the inner and middle coats.

c. External coat, with a thin lamina of the middle coat.

d. Tube formed by the turning down and inversion of the inner coat and some laminæ of the middle coat.

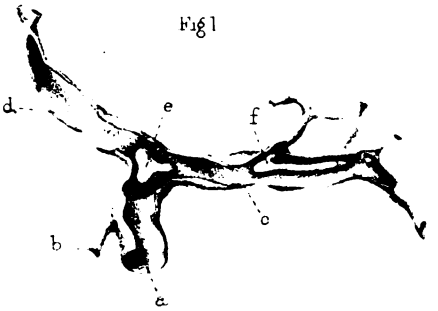

P. J. Vanderbyl, M.D. del.

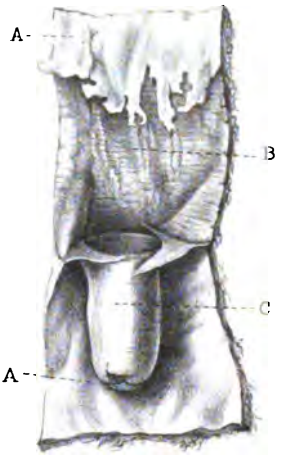

T. W. del.

Fig 2

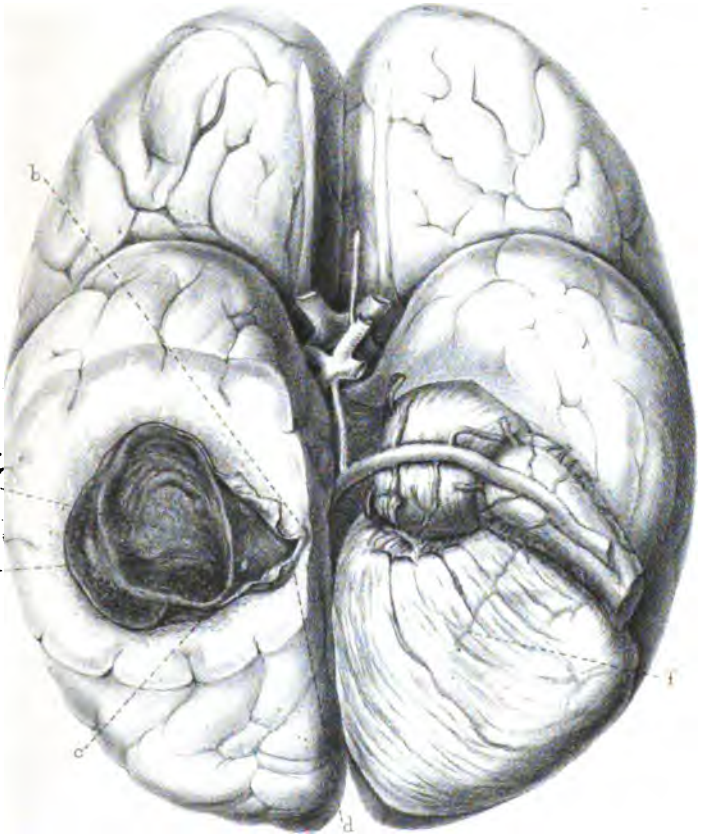

P. J. Vanderbyl, M.D. del. Tuffen West lith.

W. West, Jun.

plained of weakness. About eight weeks after this he was brought to the Middlesex Hospital, in the condition already described.

In the "Transactions of the Anatomical Society of Paris," a few cases of intracranial aneurisms are recorded, but they are few and far between; and I am not aware that any case of aneurism within the brain has ever been recorded. Dr. Brinton has presented this Society with an excellent report of intracranial aneurisms up to 1852. I believe not many cases of these aneurisms have been recorded since. But, from all that has been said on the subject, I do not see that we have arrived at very much to aid our diagnosis. The symptoms produced by intracranial aneurism appear to me to be similar to those produced by any tumor within the cranium. Hemiplegia, indeed, is a very frequent result, and after its sudden occurrence, the slow course of paralysis is very striking. In this respect, then, intracranial aneurism seems to differ from solid tumors within the cranium. Generally, also, this effect is produced by some sudden and great exertion, or a forcible expiration. Dr. VAN DER BYL, 1*st of January*, 1856.

---

24. *Contusion of the Abdomen, causing Laceration of the Vena Cava; with Rupture, Inversion, and Invagination, in a Tubular Form, of portion of the Inner and Middle Coats of the Aorta.*

M. D. æt. 45, a costermonger, was admitted, at half-past ten, A.M. on the 28th of August, into the Middlesex Hospital, with symptoms of internal hæmorrhage from an injury of the abdomen. In pushing his truck before him, a waggon ran against it, and, driving it back upon him, he was stopped by a wall: one handle of the truck caught against the lower part of the right side of his abdomen, and the waggon continuing to push the truck upon him, he received a violent squeeze. When seen by Mr. Shaw, three hours after the accident, he was pale, nearly pulseless, restless, and had excessive thirst. He could not move the right lower extremity. Above the centre of Poupart's ligament on the right side, there was a lacerated wound of the integuments four inches in length, exposing the

aponeurosis of the external oblique muscle: there was also, above that, a protuberance of the abdomen, like an undefined ventral hernia, with a base of five inches in diameter, where the parietes were thin, and the viscera were partially protruded at each exertion of the patient. He lived till half-past two, P.M. being about four hours from the occurrence of the accident.

Examination after death.—At the seat of injury there was extensive ecchymosis; there was no actual breach of continuity in the tendinous expansions of the abdominal muscles, or in the parietal peritoneum, but they had the appearance of having been greatly stretched; and the outer edge of the inferior belly of the rectus muscle was torn. The peritoneal cavity contained a large quantity of coagulated blood. When that was partly removed, a rent was seen in one of the folds of the mesentery, near its root; and there was considerable ecchymosis in the coats of the small intestines adjoining. Upon lifting up the edge of the torn mesentery where it covered the spine, and clearing away some of the coagulum, a longitudinal rent, one inch and a half in length, in the lower part of the vena cava, was brought into view. The psoas muscle was torn across transversely, and when the finger was inserted into the gap between its fibres, the transverse processes of two of the middle lumbar vertebræ were found fractured. Blood had penetrated in considerable quantity behind the peritoneum, principally in front of the sacrum and right posterior synchondrosis. Upon bringing the aorta into view, a slight discolouration and bulging of its coats were observed at one part. When that portion, consisting of three inches of the lower end of the vessel, was cut out and slit open longitudinally, the following appearances were presented (Plate VI. Fig. 3.). At the part where the bulging existed, the inner coat, and the middle coat partially, had been ruptured, with an uneven edge, round the whole extent of the interior of the vessel; and a portion of these coats, measuring about an inch in length, had been, as it were, dissected, and turned down into the vessel beneath. That the separation had taken place by a splitting of the laminæ of the middle coat, was evident from a thin layer of the latter tunic being visible on the inner surface of the external coat. While being thrust

down and invaginated, the detached portion of the coats had preserved its continuity as a tube, and had been inverted. Hence a tube nearly an inch in length, the exterior of which was formed by the inner coat, and the interior by layers of the middle coat, hung down in the aorta; the part of the artery exposed above being the external coat seen in its internal aspect, with a thin lamina of the middle tunic adhering to it. There was no coagulum in the aorta in the neighbourhood of the injury.

Mr. Shaw added that he had witnessed two other cases where, from contusion of the artery, the inner and middle coats had been ruptured and turned down within the cavity of the vessel, while the external coat was entire. In neither, however, did the coats so reflected downwards form a distinct tube, as in the case just related. The first case was that of a patient under the care of the President, the brachial artery being the subject of the injury. The second was under his colleague, Mr. Moore, and the superficial femoral was the artery injured. In both cases total obstruction to the circulation of the limb was produced.* Mr. SHAW, *4th of November*, 1855.

---

25. *Specimen of Calcareous Deposit of unusual size, containing true Bone-structure, in an Iliac Vein.*

The specimen was a part of the common iliac vein, having on the inner surface of its posterior wall, a mass of calcareous matter of about two inches in length; and tapering to its extremities from the middle part, which was between one-quarter and one-half of an inch in thickness. This mass was covered here and there by dried glue-like material, which was the remains of firm fibrin, found, when recent, to be closely investing it. The other portions, not covered by the fibrin, had been freely exposed to the venous current of blood.

* In a paper on "Dissecting Aneurism," communicated to the "Monthly Journal of Medical Science," September, 1849, by Dr. Peacock, numerous proofs are given that, in the separation of the coats of the aorta which characterizes that kind of aneurism, the injected blood does not penetrate, as commonly stated by pathologists, between the middle and external coats; but that it splits up the middle coat, part of the laminæ of which adhere to the inner, and part to the external coats.

The preparation was shown for two reasons:—1. Owing to the very unusual size which it had attained. 2. Owing to its microscopical character, inasmuch as when a section was made and submitted to the microscope, amidst the general calcareous substance of indefinite character, lacunæ and true canaliculi were observable here and there, giving the character of true ossific formation.

It would seem, from this observation, that the word "Phlebolithe," or vein-stone, ordinarily applied to these masses, does not certainly, in all cases at least, convey to the mind the proper idea of their constitution: hence some other appellation is desirable.

In the patient from whom the specimen was removed, nothing presented itself in any other part of the body allied to the specimen. Dr. J. W. Ogle, *4th of March*, 1856.

---

26. *Softening Clots in the Heart, in a case of associated Renal Disease,—Hypertrophy of the Heart,—Pulmonary and Cerebral Apoplexy.*

The following case was brought under the notice of the Society, chiefly because it gave me the opportunity of making some remarks with regard to softening cardiac clots.

Of the history of the case I know nothing beyond the fact that the subject of it died suddenly in a carriage, on his way by railway to London.

J. H. a West India planter, was examined on the 22nd of November, 1855. He was six feet high, and weighed eight stones thirteen pounds. He was not emaciated,—indeed, there was a good deal of fat deposited in different parts of the body. The lower extremities were slightly œdematous.

Head. Calvaria and dura mater healthy. On removing the latter, a layer of recently coagulated blood was found spread over the lateral surface of the right cerebral hemisphere. In superficial extent it was about equal to the palm of the hand; in thickness it varied from the one-sixth of an inch at its centre, to a mere film at its margins. It was situated wholly in the cavity of the arachnoid. No ruptured vessel could be detected either on the surface of the brain, or connected with the dura

mater. There was no trace of blood in the subarachnoid spaces, and they did not appear to contain more fluid than usual, although more than the ordinary amount was detected at the base of the skull. The surface of the brain was not congested. All the vessels at the base, and their branches, were thickly studded with patches of atheromatous deposit. On making sections of the brain, its substance was found to be remarkably wet, but otherwise healthy. There were no extravasations of blood in it, nor any apoplectic cysts. The ventricles were dilated, and contained more fluid than usual.

Chest. Pericardium healthy. The heart was much enlarged and weighed twenty-five ounces and a quarter: the enlargement of both sides was proportionate. The cavity of the left ventricle was dilated; its walls were firm, and three-quarters of an inch thick at the thickest part. The aortic and mitral valves appeared to be competent and healthy, except that the latter presented a few spots of atheroma. The walls and cavity of the right ventricle were enlarged in an equal ratio, the walls being about one-quarter of an inch thick. The right valves were healthy. The cavities contained a little recent coagulum; but, in addition, there were discovered older clots in process of breaking down. In the left ventricle, attached to the fleshy columns of the septum, was an ovoid buff-coloured fibrinous cyst, about one inch and a half long, which was filled with a thick brick-red puriform fluid; and in both auricular appendages, a few smaller but similar formations, were discovered. They were entangled among the inequalities of the surface, and slightly adherent thereto by delicate filaments.

The puriform fluid, under the microscope, was found to present an amorphous granular appearance, with here and there cell-like bodies, which appeared to be decaying blood and white corpuscles. There were also numerous very fine acicular crystals.

The aorta, in its whole length, was thickly studded with atheromatous patches, but was not dilated. These patches were most numerous in the arch.

The pleura were free from old adhesions. The right lung was large and heavy, and, in the greater part of its extent, healthy-looking and crepitant. In the upper lobe were two

patches of recent pulmonary apoplexy; one occupied a space of three or four cubic inches, the other was about the size of a Spanish nut. Nearly one-half of the middle lobe was the seat of apoplectic effusion, which formed several irregular patches. The lower lobe contained several large masses from one to three or four cubic inches in extent. All these had the character of recent apoplexy; that is, they were of a reddish-black colour, yielded blood and a little air on pressure, and were abruptly marginated. The greater part of the surface of the lower lobe was covered by a thin film of recently effused lymph; and a similar film extended over the greater part of the middle lobe, and over the lower part of the upper lobe, being chiefly confined to the surface of the apoplectic clots, and to their immediate vicinity. The left lung was large and somewhat heavy, like the right, and the greater part of its tissue was crepitant; but its upper lobe contained two or three apoplectic clots, from the size of a pigeon's egg, to that of a hazel-nut; and the lower lobe presented several similar masses, one of which occupied several cubic inches. These clots presented the same characters as those before described. The greater part of the lung was enveloped in an exceedingly thin granular layer of lymph, which was deficient at the apex and at those points which were furthest removed from the clots, but was, in every instance, present on and around the clots themselves. The bronchial tubes contained a considerable quantity of somewhat viscid mucus.

Abdomen. Peritoneum healthy. Liver rather large and yellowish, but otherwise healthy. Spleen, pancreas, stomach, and intestines healthy. The left kidney weighed five ounces and a quarter; its surface was very decidedly granular, and somewhat mottled; and it presented several cysts from the size of a filbert downwards. On section the cortical substance appeared a little mottled, but in other respects healthy. Both it and the medulla were somewhat congested. The organ was surrounded by a considerable quantity of fat; and the fat encroached upon the hilum. The right kidney contained, in its upper half, a cyst fully as large as a small orange, and several smaller ones here and there. The walls of the large cyst were very thin, but were studded with opaque patches and thin bony plates; the fluid contained in it was a limpid transparent serum.

This kidney, after the contents of the large cyst had been evacuated, weighed, as nearly as possible, the same as the right, and it presented precisely the same kind and degree of disease.

Under the microscope, many of the Malpighian bodies were found to be healthy, but many also were atrophied, and presented concentrically thickened capsules. Nothing remarkable was detected in the matrix of the organs. Many of the tubes contained normal epithelium; others presented in their interior microscopic cysts of various sizes. Some of these cysts were ovoid, transparent, and, apparently, structureless; others displayed cell-like bodies in their interior; some of them were so thickly studded with granules as to form compound granular cells; and a few were tinged with the colouring matter of the blood. In some instances the contents of the tubes consisted of a series of these bodies; and in other instances the contents were wholly amorphous and granular. The walls of the large cyst were formed of a delicate matrix of fibrous tissue, studded irregularly with minute molecules, which were here and there aggregated so as to assume a densely nebulous appearance. Acetic acid dissolved many of these granules.

There can be little doubt that the person whose *post-mortem* examination has been given above, died from the sudden effusion of blood on the surface of the brain. It is clear, however, that he had been suffering for a long time prior to death from hypertrophy of the heart and disease of the kidneys; and that pulmonary apoplexy must have supervened on these affections not long before his demise. It seems to me most probable that the primary disease was in the kidneys; that the hypertrophy of the heart was secondary to the renal affection; and that the pulmonary apoplexy was the result of embarrassment in the action of the heart.

Report on Softening Clots.—It has appeared to me, for some time past, indeed, nearly ever since I have paid any attention to pathology, that the nature of those softening polypoid concretions, to which have been applied the names of "purulent cysts," "globular vegetations," "organised clots," &c. that are occasionally found within the heart, is very generally misunderstood. I suspect, indeed, that many of those who have been in the habit of practically studying pathology, and whose opportunities for

observing these peculiar formations have been at all extensive, hold very much the same opinions with regard to them as are advocated in this communication. Still, when I find views, which appear to me quite erroneous, are advocated by such recent authorities as Hasse and Stokes, and are adopted by Drs. Jones and Sieveking in their valuable "Manual of Pathology," I think I am justified in laying the results of my experience before the Society, and in pointing out what I believe to be the true pathological signification of those bodies. My observations have been made from time to time with more or less care. I confess, however, that not until the present moment having paid special attention to the subject, I find my cases by no means so complete as I could have wished.

The number of cases of which I have preserved notes, from April 1850, amounts to twenty-three. Though this number is small, and the records imperfect, some important inferences may, I think, be derived from their analysis.

1. *Sex.*—Softening clots were found more frequently in males than in females. The difference, however, is slight, and it is perhaps not unfair to assume that the liability to their occurrence is equal in the two sexes. They were observed thirteen times in males, ten times in females.

2. *Age.*—From an examination of the subjoined table it will be seen that they occurred in patients between the ages of fifteen and seventy; but that in thirteen instances out of the twenty-three they were found in persons between thirty and fifty. Hence it would appear that the middle period of life is that which is most prone to their occurrence. The apparent immunity of children may be partly explained by the fact that a comparatively small number of them, and, indeed, scarcely any very young children, are received into the wards of the Hospital.

15 to 20 years of age	2	40 to 50 years of age	5
20 to 30 „	2	50 to 60 „	3
30 to 40 „	8	60 to 70 „	3

3. *Situation.*—Rokitansky observes, "It is a remarkable circumstance that globular vegetations are almost always limited to the left ventricle." The appended table by no means bears

out this observation: for a reference to it shows that they existed fifteen times in the left ventricle, fourteen times in the right auricle, seven times in the right ventricle, and seven times in the left auricle. Hence, although they appear really to have been rather more common in the left ventricle than in any other single cavity, they were found nearly twice as frequently in the three cavities together, as they were in the left ventricle: and so far from being limited to it, it is worthy of remark that they occupied the left ventricle exclusively in five only out of the fifteen instances in which they were met with in that cavity.

There is nothing in the table to show that the diseases of which the patients died exerted any influence over the position of the coagula. For, to take the cases of phthisis by way of example, it will be seen that in one case they occupied the right auricle and ventricle, in another the left auricle and ventricle, and in the third the left ventricle. And the same uncertainty with regard to the position of the clots, will be found equally to pervade the other classes of diseases which are comprised in the table.

	R.		L.	
	Au	V	Au	V
(1.) Phthisis . . .	1	1	—	—
(2.) Aortic valve dis. hyp. of heart .	—	—	—	1
(3.) Renal disease . .	1	—	—	1
(4.) Fibrous tumors of uterus . . .	1	—	—	—
(5.) Aortic valve dis. hyp. of heart .	1	—	—	—
(6.) Pyæmia	—	—	—	1
(7.) Dilatation of arch of aorta, hyp. of heart	1	—	1	—
(8.) Bronchitis, hyp. of heart	1	—	1	1
(9.) Bronchitis, hyp. of heart	1	—	—	—
(10.) Fever(?) . . .	1	1	1	1
(11.) Dis. of aortic, mitral, and tricus. valves, hyp. of heart	1	—	1	—
(12.) Renal disease . .	1	1	—	1
(13.) Gangrene of toes, pulm. apoplexy	—	—	—	1
(14.) Renal disease . .	1	—	—	1
(15.) Phthisis . . .	—	—	1	1
(16.) Hyp. of heart . .	1	—	1	1
(17.) Bronchitis hyp. of heart	—	—	—	1
(18.) Fibrinous degeneration of heart, hyp.	1	1	—	1
(19.) Disease of aortic valve, hyp. of heart	—	1	—	—
(20.) Renal disease . .	—	1	—	1
(21.) Phthisis . . .	—	—	—	1
(22.) Adhesion of pericardium, hyp. of heart	—	1	—	—
(23.) Renal disease, &c.	1	—	1	1
Total .	14	7	7	15

With regard to the position of these coagula, in relation to the cavities which contain them, I agree fully with Rokitansky that they are found in those parts of the cavities which are most favourable to the stagnation of blood. In the auricles, they chiefly affect the auricular appendages, and in the ventricles they almost always occupy the apices and the interstices between the carneæ columnæ.

4. *Diseases with which they are associated.*—There certainly appears to be a very general impression among authors that the softening clots are connected in some way or other with a pyæmic condition, that they are more common in cases of pyæmia than in any other class of cases. It was to combat this impression that I was in great measure induced to embody the facts at my command in the present paper. By reference to the subjoined table, it will be seen that the occurrence of these clots, in connexion with pyæmia, appears to be the exception, and not the rule, for of the twenty-three cases comprised in the table, one only was an example of pyæmia; and even if we were to include under this denomination two other cases, one of which I have doubtingly called fever, and the other of which is styled gangrene of the toes, the number of cases in which these clots were associated with purulent absorption would be very small compared with the number of instances in which they were connected with other forms of disease. Still futher to show the little connexion there is between pyæmia and the occurrence of these clots, I have collected from the *post-mortem* records of St. Thomas's Hospital twenty-six cases of pyæmia, all cases in which the existence of this disease was certain (for the number might easily have been increased by including doubtful ones), and I find that in one only out of this number—the one included in the table—was there any appearance of softening clots in the heart.

The diseases with which they were most commonly associated, are chronic affections of the heart, chronic affections of the kidney, and chronic affections of the lungs, including phthisis. They co-existed with hypertrophy of the heart (including that form which accompanies bronchitis, and that which is attendant on renal disease,) fourteen times, with

pulmonary apoplexy eight times, and with anasarca in the majority of instances. Hence, I think it may be inferred that they are formed most frequently in those cases in which there is retardation in the current of blood, and in which the struggle between life and death is protracted.

Lung dis.	6	Phthisis	3	Kidney diseases	5
		Ch. bronchitis	3	Fibrous tumors of uterus (hæmorrhage)	1
Heart aff.	8	Aortic valve	4	Gangrene of toes	1
		Disease of arch	1	Fever (?)	1
		Fibroid degen.	1	Pyæmia	1
		Adhesion of peric.	1		
		Simple hypertrophy	1		

5. *Description.*—On laying open a ventricle containing these peculiar formations, we find in addition, it may be, to ordinary coagulum, and perfectly distinct from it, a number of globular or ovoid bodies, from the size of a pin's head, to that of a pigeon's egg, projecting from the spaces between the carneæ columnæ. Their free surfaces are sometimes smooth, but frequently present a peculiar ribbed appearance. Their colour is usually buff or yellowish-white; sometimes, however, it assumes more or less of a brick-red tinge, and occasionally it is variegated with alternate streaks or spots of red and white. At first sight they appear to be strongly adherent to the parietes of the heart. This adhesion, however, is chiefly due to their prolongation beneath and between the carneæ columnæ. Indeed it is certain, that in nearly all cases, these coagula, though at first sight they appear to be isolated, are all connected with one another beneath the fleshy columns,—that they are, in fact, merely the projecting portions of a clot which is entangled among the inequalities of the internal surface of the cavity, and is accurately adapted to them. There exists, nevertheless, frequently actual adhesion between the coagula and the parietes, and delicate filamentous processes are distinctly torn through in separating one from the other. Occasionally I have observed a distinct circumscribed pit left in the endocardium after the removal of a clot, and in one instance I saw a small clot attached by a little pedicle to one of the chordæ tendineæ.

On cutting into these clots they are found to vary consider-

ably in character. Sometimes they are solid throughout. In such cases they may have a uniform buff colour; or they may present alternate streaks of red and white, so as to assume something of the ribbed appearance so commonly observed on the surface; or the red colour and the white may be irregularly intermixed.

Frequently they are softened in their interior into a thick puriform fluid, which varies in colour from a pale buff to a brick-red, or even a chocolate hue. The cysts thus formed present great differences as to size and shape. Sometimes a coagulum is softened in two or three points only, sometimes it contains irregular anfractuous cavities, and not infrequently it is converted into a perfect globular or ovoid cyst. The parietes of the softened clots vary with the form and character of the cavities they contain. If the cavities are small in proportion to the coagulum, or if their form is irregular, or their position eccentric, the parietes necessarily vary considerably in thickness; whereas, if the process of softening has taken place uniformly throughout the mass, and the cavity is comparatively large, the walls present nearly the same degree of thickness throughout, and sometimes are not more than half a line thick. The outer surface of the cysts has been already described. The inner, or that immediately bounding the cavity, is soft and somewhat flocculent or shreddy. The substance of the walls exactly resembles that of the unsoftened clots previously described. In consistence they are somewhat soft and lacerable, yet they retain a certain degree of elasticity and toughness. It is important to bear in mind that, though occasionally softening clots only may be found in one case, and solid clots only in another, the two kinds generally co-exist.

Under the microscope, the solid clots, as well as the parietal portions of the fluid-holding ones, present tolerably uniform characters. They consist of a fibroid network, similar to that of ordinary coagulated fibrin. This, however, is intermixed with a large quantity of granular matter, which renders the fibroid structure more or less indistinct. They contain also oil, compound granular cells, and a few imperfect cells, which appear to be the remains of white corpuscles. In some

cases, there are many altered blood corpuscles, and, now and then, solitary and clustered needle-like crystals.

The puriform contents of the cysts present considerable variety as to their microscopic elements. When white or buff-coloured, they consist almost solely, if not solely, of molecular matter, oil, and broken down corpuscles, with which are frequently mixed compound granular cells and colourless acicular crystals. When presenting a brick-red or chocolate hue, they exhibit, in addition to the elements just mentioned, numerous blood corpuscles, more or less altered, and, consequently, more or less indistinct, and occasionally also ruby-coloured, rhomboidal, hæmatoid crystals.

Now all the elements above described may very fairly be looked upon as the remains of decomposed coagulum. The granular matter, the oil, the compound granular cells, the blood corpuscles, and the crystals, are all appearances which are constantly met with in clots which are undergoing decay in other parts of the body; and the breaking down cells, which have just the size of the white corpuscles of the blood, may very reasonably be regarded as the remnants of those bodies.

Occasionally, however, other elements are detected in the pus-like fluid (as in case 12). In that instance, many of the cysts were loaded with well formed globular cells, about the size of white corpuscles or of pus. Their number was far too great in proportion to the other elements to render the supposition of their being white corpuscles at all admissible; indeed, they were quite as numerous as pus-cells are in healthy pus. Another circumstance, however, clearly showed that they could not be white corpuscles, and, at the same time proved that they were not true pus-cells;—acetic acid exerted no influence over them. The corpuscles were exactly similar to those which were observed in a clot blocking up the internal carotid artery, in a case brought before the Society during the present session by Dr. Peacock and myself, and, though not true pus, I am disposed, for many reasons, to regard them as the result of the inflammatory process.

I have never discovered true pus in these cysts; still, con-

sidering, as I do, that there is a close affinity between pus-cells and those just described, its discovery therein would not much surprise me. It is scarcely necessary for me to add that I have never found anything like tubercle or cancer.

6. *Origin, progress, and termination.*—In the foregoing description it will probably be observed that I have included two forms of clot which are occasionally looked upon as being perfectly distinct, *viz.* :—such as are softened internally, and such as are solid throughout. This I have done because I entertain no doubt whatever, that their nature is essentially one and the same, and that the only real difference between them lies in their relative ages, or in some accidental circumstances. In form, colour, consistence, and microscopic characters, they agree in all respects; moreover, they generally coexist, and it is often easy to trace the successive steps by which the solid mass becomes converted into the fluctuating cyst.

Having thus pointed out the facts which, according to my opinion, establish the identity of these two forms of clot, I will endeavour to trace them back to their origin.

It is well known that the coagula which are found in the heart after death, present certain varieties of character which depend on the time and mode of their formation. Some are formed *after death*, simply by the coagulation of the blood which is left in the uncontracted cavities of the heart. Such clots are, for the most part, soft, loose in texture, and black-currant jelly like, and rarely, if ever, I suspect, when formed after death, contain decolourised fibrin.

Others have been manifestly produced *during life.* These coagula resemble one another in this,—they are more or less completely fibrinous, presenting frequently, however, coloured clot either on their surface or in their interior; they are moulded to the inequalities of the heart's surface, and very frequently send processes between and beneath the carneæ columnæ, so that they are attached pretty firmly to the parietes. These ante-mortem clots, however, present varieties in character which can only depend on the length of time that has elapsed between the epoch of their formation, and the moment at which death has occurred. Some are soft and loose in texture,

and retain more or less of the colouring matter of the blood; these approximate in character to the *post-mortem* clots, and are evidently formed immediately prior to death. Others are almost wholly fibrinous, straw-coloured, jelly-like, and elastic: they are firmer than those just mentioned, and evidently of somewhat older date. Others, again, are tougher and closer grained than the preceding; they are inclined to be opaque, and to assume more or less of a buff colour: these are evidently older than either of the other forms. The fibrin forming these has begun to contract, and to squeeze the fluid of the clot from its interstices; and that series of changes has clearly begun which eventuates in the disintegration and destruction of the clot. As an example of the last form, I may quote from one of my *post-mortem* records of a case of phthisis: "The cavities of the heart were distended by coagulum. In the apex of each ventricle, and in each auricular appendage, the coagula were buff-coloured, toughish, and moulded to the inequalities of surface; and were, in fact, prolonged between the carneæ columnæ and musculi pectenati. But the remaining parts of the cavities (those parts through which the blood more directly passed), were filled with soft black-currant jelly like coagula, which were evidently recent, and perfectly separable from the fibrinous ones."

Now it seems to me clear that the clots just described, and those that form more particularly the subject of this communication, constitute a distinct and natural series; and the views which I entertain with regard to the production of the latter are as follow:—

Some time prior to death, from causes which I shall discuss further on, coagulation takes place in the blood in one or more of the heart's cavities, and then the tendency to coagulation, for a time, ceases. The coagulum thus formed, maintained in its position by the processes which are prolonged from it among the carneæ columnæ, gradually contracts in virtue of the contractile force inherent in coagulated fibrin. As it is bound rather firmly in most instances to opposite sides of a cardiac cavity, the gradual contraction in its mass, combined with the constant action of the heart, probably produces disruption. The continuance of contraction after disruption has occurred, tends

to give a rounded form to the fragments of clot which remain attached to the parietes of the heart; and this process of rounding is, no doubt, completed and perfected by the constant attrition to which the clots are subjected by the passage of the blood over their surfaces. The projecting portions of coagulum in this way assume the characters of those rounded solid nodules which I regard as the immediate antecedents of the softened clots. After this the coagulum begins to soften and disintegrate, as do coagula of sudden formation and of any size in other organs, as in the brain, lungs, arteries, &c. The softening appears always to begin in the interior, in those parts most removed from the influence of the vital current; the peripheral portions remaining solid, either in virtue of a low force of vitality impressed on them by the blood which washes them, or in consequence of constant renovation from the same source. The microscopic characters, both of the solid and the fluid parts of these softened coagula, in most instances bear out the views that I here advocate with regard to their formation. There are, however, two or three points which may, at first sight, appear to militate against my views, and which need, therefore, to be examined into and explained.

a. I have before remarked that most of these softening coagula are actually adherent, by delicate false membrane, to the surface of the endocardium: is that compatible with the origin I have assigned to them? I believe that it unquestionably is; I believe that a coagulum having formed in the usual way, and having become closely applied, though unadherent, to the cardiac walls, would, as a foreign body, by its constant mechanical irritation, produce, in the subjacent serous tissue, slight inflammation, accompanied by a sufficient effusion of lymph to produce the degree of adhesion I have alluded to. This opinion I found, not on theoretical grounds, but on the analogies afforded by the progress of clots in other organs. In the brain, for example, as is well known, the brain tissue immediately bounding on apoplectic clot, become, shortly after the formation of the clot, somewhat softened, and presents, under the microscope, a considerable abundance of compound granular cells; the presence of these cells appearing to confirm, what other appear-

ances indicate, that the clot has become surrounded by a halo of inflammation. But much more to the point is the series of changes which follow on apoplectic effusions into the lungs. When these effusions depend on disease of the heart, there can be no reason, of course, for supposing that their production is dependent on any process analogous to inflammation; and, indeed, when first formed, there is nothing in or about them to support any suspicion of the kind. Yet, after they have been in existence a few days, and when their peripheral portions are beginning to be decolorized, we find in, perhaps, the majority of instances, that where they reach the surface, the portion of pleura over them becomes covered by a thin film of lymph, which diminishes gradually in thickness as it recedes from the clot, and disappears wholly at no great distance from it. The case which heads this paper furnishes one out of many examples of the fact which I have met with. Here it is manifest that the presence of the coagulum has produced slight inflammation in the parts around, and an actual effusion of lymph on the contiguous serous surface; and the sequence of events is identical with that which I suppose to occur in the case of cardiac clots.

b. I have described one case in which the pus-like contents of the softening clots contained a large number of cells, which were evidently produced by something else than the mere process of softening. The fact of other cysts in the same case containing the ordinary amorphous contents, is in itself sufficient to prove (if any proof be needed), that these cells could have had nothing to do with the original formation of the clots, but that they must have been developed subsequently; and I am disposed to associate their formation, and also that of true pus (if it is ever found), with that inflammatory condition which produces adhesion between the clots and the endocardium. I suspect that the influence of the inflammatory condition of the endocardium is propagated into the mass of the clot, and promotes the formation of a low form of cell growth in those parts of its substance in which vitality is not wholly extinct. Though this explanation is not without its difficulties, it seems to me that it is at least as probable as any other that can be offered, and it certainly has

the advantage of being compatible with the views I entertain with regard to the nature of the clots.

As there can be no doubt that, in the great majority of cases, these coagula are formed in individuals in whom death is imminent, and who, though they may occasionally rally, are past the hope of recovery, it is evident that the opportunities for studying their further progress, for observing those changes which (supposing life to be prolonged) they would undergo, must be exceedingly rare. I have a very distinct recollection of a case which I examined about four years ago; and which, I believe, illustrates this subject: the record of it, however, I am sorry to say, I have mislaid or lost. Projecting from the interspaces between the carneæ columnæ, and connected with each other beneath these columnæ, by means of processes having the same texture as themselves, were numerous small whitish masses, from the size of a horse-bean downwards. Their surfaces were wrinkled, and, on section, some of them appeared to be collapsed bags, but none of them contained puriform fluid. Their substance was tough, and in it was a considerable quantity of earthy deposit. I do not remember in which cavities these bodies were found, neither do I recollect any other fact in connexion with the case, but I know that I examined these bodies very carefully at the time, and that the conclusion I arrived at was, that they were transformations of softening clots: and since, from analogy, such a termination might be predicted of them, I believe the conclusion I formed was the correct one.

7. *Cause.*—(A.) Since the softening clots are, as I have shown, comparatively very infrequent in cases of pyæmia, it is quite clear that pyæmia is unnecessary to their production. And, indeed, I think it may very safely be assumed, that even when these bodies are associated with pyæmia, the pyæmic condition of the system is not the cause of their formation, but simply a coincidence.

(B). I confess that I cannot at all understand how pus or tubercle, conveyed from some distant part of the system, should collect in the heart and become surrounded by a fibrinous capsule, which is the explanation of their formation assigned by some. My own cases certainly do not bear out any such views. Indeed, I feel sure that they are assumed without

adequate evidence of their truth, and I cannot but consider that they are wholly erroneous.

(c.) Rokitansky's opinion is, that they depend on some diseased condition of the fibrin, consequent on some dyscrasia of the blood, and he adduces typhus, pyæmia, together with tuberculous and cancerous diseases, as examples of cases in which this dyscrasia exists. Here, again, I hold a different opinion, except the signification of the term dyscrasia be extended so as to include the condition of the blood in every form of disease, which clearly would be to rob this explanation of all significance.

(D.) Do they arise in consequence of any inflammatory condition of the lining membrane of the heart? There are several reasons in favour of this view. In the first place, the blocking up of arteries in different pars of the body by coagulation of blood, dependent apparently on local arteritis, is not uncommon in cases of phthisis and some other diseases. And the coagula thus produced, have no little resemblance to the coagula which are under consideration. Again, the adhesion of these bodies, by means of filaments, to the parietes, tends to show that some inflammatory condition has occured in that part of the pericardium with which they are in contact,—a view which is supported by the occasional existence of the products of inflammation within the cysts themselves. These arguments, however, do not possess that weight which at first sight they might appear to do; for, in the first place, although these clots may have some resemblance to the clots in an inflamed artery, they have at least an equal resemblance to coagula which have formed under other conditions; in the second, the existence of lymph between them and the cardiac walls, by no means implies that the inflammation producing it preceded their formation, on the contrary, as I have endeavoured to show, there is very good reason for believing that the inflammation is a consequence, and a necessary consequence, of their presence; and, in the third place, the existence of inflammatory products in their interior, which is undoubtedly the exception, and not the rule, can scarcely be used as an argument in favour of the inflammatory origin of the majority.

Finally, if we compare these coagula with those vegetations which are undoubtedly the result of inflammation, we find a marked difference between them. For while the former have a rounded form, peculiar anatomical relations with the parietes, and choose, as it were, the remoter nooks and corners of the heart's cavities, the latter, whatever size they may attain, have a warty character, attach themselves usually to the smoother portions of the endocardial surface, and affect those situations which are most exposed to the current of the blood. Now, if these two forms of vegetations really do have the same origin, and if the differences between them are to be attributed to accidental circumstances only, it is to me a very remarkable and inexplicable fact, that we rarely, if ever, find the two forms coexisting in the same case. From the above considerations, I conclude that there is little reason for believing that the softening clots depend on local endocardial inflammation.

On what, then, do they depend? I think the cases I have appended to this paper, although their histories are very imperfect, will bear me out in the statement that these coagula are produced in those persons who are dying slowly, or who have been apparently at the point of death some time prior to the actual occurrence of death. We know that in chronic heart diseases, in chronic kidney and lung affections, and in phthisis, which form the staple of the cases I have collected, the patients are often dying for days, and sometimes even weeks, before life actually becomes extinct, and during that sinking state they are subject to occasional changes, at one time appearing to revive, at another lapsing into an almost moribund condition. I believe, that during this time, and, perhaps, more particularly on one of those occasions, on which the patient seems at the point of death, the vascular system participates in this condition, and the blood coagulates in one or more of the heart's cavities; that from this state the patient temporarily rallies, but that the clot, the evidence of the imminence of death, remains, and during the remaining period of the patient's life undergoes that series of changes which I have described. I believe, therefore, that these softening clots are merely transformations of coagula which have formed some

time prior to actual death, at a time when the patient had sunk into an almost dying condition, and that they are produced in the same way, from the same cause, and have the same nature as those which are ordinarily formed immediately before death, and which are so commonly found in the cavities of the heart. Not only, I think, do the structure of the clots and the character of the cases in which they are commonly found bear me out in the view I entertain with regard to their formation, but the few histories which I have added, and which, though imperfect, are correct as far as they go, also tend to give probability to my explanation.

8. *Symptoms.*—In the absence of facts, it seems to me idle to speculate as to what symptoms may accompany and indicate the existence of these coagula. And, in truth, if it were possible to diagnose their presence, I suspect that the knowledge thus obtained would be far more for the gratification of the physician than for the benefit of the patient. It may readily be supposed that if one of them became entangled in one of the valves, or in any other way impeded its action, that a murmur would be produced at the orifice; but from the fact of the coagula being usually found at a distance from the valves, it is clear that such a contingency is little likely to occur. There can be no question, however, that the presence of these coagula in the heart's cavities must considerably embarrass the action of the organ, and diminish materially any slight chances there might otherwise be of the patient's ultimate recovery.

My reason for devoting a separate paragraph to the consideration of the symptoms, was simply to afford myself an opportunity of drawing attention to some phenomena in case 12, which, though they may have been merely coincidences, I strongly suspect to have been dependent on the existence of the softening clots. The patient was as nearly dead as possible, supposed to be moribund, about forty days before she died, and at that time, I believe, the clots were formed. Ten or twelve days after this time she had slight, but decided, symptoms of pericarditis, and they lasted for about a week. Now, at the *post-mortem* examination, the only indications of

any pericardial affection, were upon the surface of the right auricular appendage, and in the neighbourhood of a small softening clot, which contained inflammatory products, and which, being formed between two of the musculi pectenati, was covered by little more than the peri- and endo-cardium. I cannot help thinking it very highly probable that the presence of the clot excited slight inflammation in the pericardium over it, just as pulmonary clots produce slight pleuritis in that portion of the serous membrane to which they are subjacent.

About the same time that this patient presented symptoms of pericarditis, she had a slight attack of erysipelas of the face, and two or three times subsequently she suffered from the same affection. Is it possible that these attacks may have been in any way dependent upon the presence of the cardiac coagula? Is it not, indeed, probable that the changes (inflammatory, or whatever else they may have been) going on in the clots may have had some influence in promoting analogous changes in other parts of the system, and hence in giving rise to the erysipelatous attacks?

Dr. Bristowe, *4th of December*, 1856.

Note.—I have stated in my report on softening clots in the heart that I had never met with these formations in the case of children, and that I suspected it was simply because, as a comparatively small number of children are admitted into the Hospital, I rarely had the opportunity of examining them.

Since that report was written a case of the kind has come under my observation. The case is that of a girl two years and a half old, who died of phthisis at the end of a month's sojourn in the Hospital. During the whole of this time she was sinking, and her death was daily expected.

At the *post-mortem* examination there was discovered extensive tubercular disease of the lungs, spleen, and kidneys, and a few tubercles were seen scattered throughout the substance of the liver. The heart was healthy, but appeared to be enlarged in consequence of all its cavities being filled with partially decolorized coagula. Perfectly distinct from these, and altogether unconnected with them, were a number of buff-coloured, rounded nodules, from the size of a small hazel-nut to that of a pin's head, which projected from the intervals between the fleshy columns of the left ventricle. They were little, if at all, adherent to the endocardial membrane; but sent among the inequalities processes which bound them to the surface, and which served to connect neighbouring nodules with one another. They were all of them buff-coloured and solid throughout, though some of the larger ones were decidedly softer in their internal than in their peripheral portions. J. S. B., *5th of June*, 1856.

APPENDIX *to Report on Cardiac Clots.*

	Age.	Sex.	Disease.	Description of Clots.	Microscopic Description of Clots.	History.
1	24	F.	*Phthisis.*—Tubercle in ovary, Fallopian tubes, and spleen.	The right auricle and ventricle contained numerous softening clots. The larger ones, of which there were two or three in each cavity, were globular or ovoid, and about the size of marbles. Their parietes, which were very lacerable, were about half a line or a line in thickness, and either of a uniform buff-colour, or marked, in a greater or less degree, by red streaks and spots. Their contents had the appearance of thick pus, in some instances creamy, in others sanious. Besides these the auricle and ventricle presented numerous coagula of smaller size, the smallest being, perhaps, about as large as a pin's head. All of them had a rounded free surface, and in all the parietal portions were firmer than the central, though the latter were not, in all cases, softened into a puriform fluid. All the coagula were firmly connected with the endocardium. This was, in great measure, due to their being moulded to the irregularities presented by the musculi pectenati and carneæ columnæ, beneath and between which, neighbouring, and apparently distinct, cysts were	The contents of the cysts consisted of granular matter, with oil-globules and cells; of which latter, there were all varieties, between well marked compound granular cells, and cells having the appearance of the white corpuscles of the blood.	

	Age.	Sex.	Disease.	Description of Clots.	Microscopic Description of Clots.	History.
				found in most instances to communicate. But in addition to this they were somewhat firmly attached to the lining membrane either by continuity of structure, or by the interposition of a delicate false membrane. At certain points, when they were more firmly attached than elsewhere, their removal left little circular depressions in the walls of the heart. In one instance a clot about the size of a mustard seed was distinctly attached to a tendinous cord by a pedicle half a line in length.		
2	50	M.	*Aortic valve disease.*—Hypertrophy of heart; pulmonary apoplexy; emphysema of lungs.	The left ventricle contained, in addition to ordinary coagulum, numerous small quasi-organised fibrinous clots, entangled amongst the carneæ columnæ, some of which were softened internally into a puriform fluid.		
3	52	M.	*Contracted granular kidneys.*—Congestion and solidification of lungs; hypertrophy of heart; slight pericarditis; anasarca; slight jaundice.	In the apex of the left ventricle and in the auricular appendages of the right auricle were several small adherent quasi-organised clots.		
4	45	F.	*Fibrous tumors of uterus. Abscess between uterus and rectum.*—Contracted granular	In the right auricular appendage were several small adherent quasi-organised coagula, softened internally into a pus-like fluid.		

	Age.	Sex.	Disease.	Description of Clots.	Microscopic Description of Clots.	History.
			mottled kidneys; ulcer of stomach; fatty heart and liver.			
5	36	M.	*Aortic valve disease.*—Hypertrophy of heart; inflammation of lung; anasarca.	In the right auricle, connected with the musculi pectenati, were numerous small quasi-organised coagula.		Complained first of symptoms of cardiac disease six months before death; used frequently to faint, but not for the last four months. Great distress and anxiety latterly, and for three days before death very restless, and at times delirious.
6	36	F.	*Pyæmia.*—Ulceration and perforation of cervix uteri after delivery; abscess between uterus and rectum, and perforation of the latter; Secondary deposits in pericardium, heart, pleuræ, lungs, and kidneys.	In apex of left ventricle were two or three small adherent coagula, the interiors of which were softened into a pus-like fluid.	Molecular matter and cells, which looked like the white corpuscles or pus-globules undergoing fatty degeneration.	
7	59	M.	Dilatation of arch of	The auricles presented numerous adherent quasi-organised coagula.		

	Age.	Sex.	Disease.	Description of Clots.	Microscopic Description of Clots.	History.
8	38	M.	aorta; hypertrophy of heart; pulmonary apoplexy; fibrinous deposits in kidneys. *Hypertrophy of heart;* (chiefly right side,) *chronic bronchitis.*—Pulmonary apoplexy; congested liver and kidneys.	Adhering to the parietes of the right auricle were numerous, more or less globular, coagula, varying from the size of a filbert downwards. They consisted of a smooth, variegated cyst-wall, containing a thick blood-stained puriform fluid. The left auricle and ventricle contained similar coagula.	The puriform fluid consisted of granule-cells; smaller cells, resembling somewhat pus-cells, or the white corpuscles of the blood, but more or less studded with oily globules; oil-globules varying from the $\frac{1}{500}$th of an inch in diameter, downwards; abundant granular matter, and numerous blood corpuscles deprived of their colouring matter. These latter were so faintly marked; that, although numerous, they readily escaped detection. In the first specimens,	

	Age.	Sex.	Disease.	Description of Clots.	Microscopic Description of Clots.	History.
					indeed, which were diluted with water, they were not even suspected to exist; they were, however, apparent in those that were mixed with saliva. There were, also, a few rhomboidal hæmatoid crystals, of small size, and a few colourless needles in tufts. The walls of the cysts presented the same elements. The granule-cells, however, were much more abundant, the blood corpuscles more distinct, and there was a considerable quantity of fibroid material.	
9	39	M.	*Chronic bronchitis.*—Hypertrophy of heart (right side); slight	Quasi-organised adherent clots in right auricular appendage.		Subject to cough for many years; laid up at time of admission

	Age.	Sex.	Disease.	Description of Clots.	Microscopic Description of Clots.	History.
			granular condition of kidneys; anasarca.			for six weeks. Pulse then exceedingly rapid and feeble, and all the symptoms of extensive bronchitis. He appeared to improve very much during the three or four days preceding death, which event was somewhat sudden. In the Hospital six days.
10	17	F.	Fever (?) — Fibrinous deposits in the liver; hæmorrhage into the substance of the kidneys; fluidity of blood; petechiæ.	The right and left ventricles contained numerous softening adherent clots, from the size of a marble to that of a pin's head. There was a small one in the left auricle connected with the foramen ovale. Several adhered to the musculi pectenati of the right auricle, and the auricular appendages of the same cavity were filled by an adherent, coloured clot, which, towards the cavity of the auricle, gradually lost its colour, and its free surface assumed the same appearance as that of the clots before mentioned. The surface of the clots was colourless,	The pus-like contents consisted of molecular oily matter, and cells, or fragments of cells, having much the appearance of pus, but which were, doubtlessly, the white corpuscles more or less altered. The walls presented the characters of coagulated fibrin mixed with	She died two days after admission, with symptoms and a history that seemed to indicate that she was labouring under typhus fever.

	Age.	Sex.	Disease.	Description of Clots.	Microscopic Description of Clots.	History.
				opaque, and ribbed. On section, the interior was found, in most cases, to be softened into a thick puriform fluid. When, however, softening had not, or had only barely commenced, the sectional surface of the fibrin presented a ribbed appearance very similar to that of the free surface.	the elements above described. There were, likewise, both in the fluid and in the solid parts, numerous small colourless needle-like crystals.	
11	43	F.	*Old disease of mitral, tricuspid, and aortic valves, with vegetations adhering to them.*—Hypertrophy of heart; pulmonary apoplexy; fibrous tumors of uterus; anasarca.	In both auricular appendages were three or four adherent clots, whch were softened centrally into a puriform fluid.		
12	32	F.	*Chronic disease of kidneys; double pleuritis.*—The kidneys were of natural size, and, to the eye, appeared pale, but otherwise healthy. Under the microscope the Malpighian bodies seemed natural; but the epithelium of many of the tubes was loaded	Both ventricles and the right auricle presented softening clots. They were largest and most numerous in the apex and lower parts of the left ventricle, and in the right auricular appendage. They were firmly attached to the walls of the cavities, chiefly by sending prolongations between and beneath the carneæ columnæ and musculi pectenati, but also by delicate bands and threads of false membrane. In the intervals between the fleshy columns, the clots formed more or less globular expansions,	The pus-like contents of the cysts were seen in some cases to consist of oil-globules and granular matter, with a few imperfect or breaking-down cells; but in other cases it consisted almost entirely of cells which had the usual size	A married woman, with a family; unhealthy and strumous-looking, with cicatrices of abscesses in neck. Has had one breast amputated in consequence of sinuses after milk abscess. On admission, was labouring under

	Age.	Sex.	Disease.	Description of Clots.	Microscopic Description of Clots.	History.
			with granular matter and oil. The most remarkable feature, however, was the large amount of earthy matter seated in the tubes. It was deposited in the form of globular, or polyhedral refractive masses, from the $\frac{1}{1000}$th of an inch in diameter downwards. These were rarely single; but generally arranged in more or less cylindrical clusters, of various, and often considerable length. They were clearly in the tubes. They were dissolved by acids. The pleuritis was recent and slight; but the amount of fluid in each pleura was from one pint to one pint and a half.	varying from the size of a pea to that of a filbert, all of which distinctly fluctuated. On section, each of these globular bodies was found to be softened centrally into a thick white pus-like fluid. The solid walls were generally white and reticulated, or ribbed on the surface, somewhat elastic and tenacious, though easy to be broken down; and varying between half a line and a line or two in thickness. The pericardium and heart were, for the most part, healthy. Along the upper margin, however, of the right auricular appendage, was a fringe of small conical masses of somewhat recently deposited lymph; and in the same line, close to the root of the appendage, was a globular pea-sized body, which projected beyond the surface of the heart, but was still covered by pericardium. This was found to be one of the softened clots, which had apparently formed between the muscular fibres, and thus bulged externally.	and general appearance of pus-cells, and were quite as abundant and perfect as those in the healthiest forms of pus. The division of their interior, however, into two or three globules on the addition of acetic acid, was certainly not so distinct as it usually is in pus. The contents of most of those in the right auricle, including the projecting nodule, had the latter character. The parietes of the cysts consisted of delicate fibrillæ, thickly studded with cells, like pus-cells, oil, and granular matter.	dyspnœa and cough, with some evidence of pleuritic effusion. Heart's action irregular and rapid, but with no abnormal sound. Much œdema of legs, ascites, and some puffiness of face. Passed small quantities of water, loaded with albumen; but of fair specific gravity. She improved somewhat under use of diuretics, but on the tenth day after admission had three epileptic fits. She appeared to be moribund; but rallied. On the twentieth day had slight erysipelas of head and neck. On the twenty-second, slight pericarditis. On the

	Age.	Sex	Disease.	Description of Clots.	Microscopic Description of Clots.	History.
						twenty-seventh the erysipelas had subsided; and soon afterwards the signs of pericarditis. No return of fits; but anasarca, dyspnœa, and cough increased; and she died on the fifty-first day after her admission. She also had one or two slight attacks of erysipelas subsequently to that above mentioned.
13	32	M.	*Gangrene of toes of both feet.*—Pulmonary apoplexy; small calculi in calyx of kidneys.	The left ventricle contained numerous cysts firmly attached to its walls, upon and between the carneæ columnæ: one of these, containing about one drachm and a half of fluid, occupied its apex. The walls of this were of a pale yellow colour, about half a line in thickness, and easily torn: the contents had the appearance of thick pus. The other cysts appeared precisely similar to this: they varied from the size of a small pea upwards. One was about	Under the microscope no cells were detected in the pus-like fluid; but it appeared to consist of distinct oil-globules, and an immense number of minute granules.	

	Age.	Sex.	Disease.	Description of Clots.	Microscopic Description of Clots.	History.
				one inch and a half in length, and three-quarters of an inch in its short diameter, another measured about an inch in diameter.		
14	62	M.	*Granular kidneys; hypertrophy of heart.*—Pulmonary apoplexy; anasarca.	In addition to the ordinary coagulum, a clot was firmly fixed in the left ventricle, apparently not by having contracted adhesions with its walls, but by a species of dove-tailing with the carneæ columnæ. That portion of its surface which was free, was irregular in shape, though tolerably smooth, and had an opaque buff-colour. On section this clot was found to contain irregular cavities filled with a thick, opaque reddish fluid: its walls were very irregular in thickness. The right auricular appendage was filled by a clot that was adherent to the musculi pectenati, and was softened internally so as to form a series of irregular intercommunicating cavities, filled with the products of softening, *viz.*:—a thick, opaque, brick-red fluid, similar in all respects to that found in the clot in the left ventricle.		A coachsmith: gave no distinct account of himself. Was typhoid when admitted; rallied somewhat after admission, and had symptoms of bronchitis. Afterwards he sank rapidly, and died between two or three weeks after admission.
15	21	F.	*Phthisis.*—Fatty liver.	Both the left auricle and ventricle contained small adherent quasi-organised coagula.		
16	60	M.	*Hypertrophy of heart, without valve disease.*—	The inner surface of the left ventricle was studded with numerous rounded clots, from		

	Age.	Sex.	Disease.	Description of Clots.	Microscopic Description of Clots.	History.
			Pulmonary apoplexy, anasarca. The chordæ tendineæ and musculi papillares connected with the mitral valves appeared disproportionately small.	the size of a Spanish-nut downwards, which were entangled between the carneæ columnæ, were smooth or slightly ribbed on the surface, and varied in colour from a pale buff to a dark red. Many of them were softened centrally, and contained a more or less red puriform fluid. Some similar clots were found in the left auricular appendage; and still more numerous and larger ones in the right.		
17	44	M.	*Bronchitis and congestion of lungs.*—Hypertrophy of right side of heart; atrophy of one kidney; anasarca.	In the left ventricle were several clots from the size of a filbert downwards, which were insinuated between the carneæ columnæ, having a reddish colour, and a slightly reticulated surface, and of which the larger ones were softened internally into a brick-red puriform fluid.		
18	39	F.	*Fibroid degeneration of heart.*—Hypertrophy; anasarca.	Both ventricles and the right auricle presented a few coagula entangled among the columnæ carneæ, which were ribbed on the surface, more or less decolorised, and, in some instances, softened internally into a puriform fluid.		Died six days after admission, having been ill for a few months. Had dyspnœa without marked bronchial symptoms. Livid face; feeble irregular pulse; urine not albuminous. *See*

	Age.	Sex.	Disease.	Description of Clots.	Microscopic Description of Clots.	History.
19	39	M.	*Disease of aortic valves.* — Hypertrophy of heart; disease of arch of aorta; chronic bronchitis.	In apex of right ventricle were a few coagula, from the size of a filbert downwards. They were bound by the carneæ columnæ to the parietes, were ribbed on the surface, and had a ribbed appearance throughout on section; this appearance being produced by alternate streaks of buff colour and red. They were not at all softened inside, and, apparently, had been in existence only a few days.		vol. vi. "Pathological Transactions," p. 148.
20	52	M.	*Partially atrophied kidneys; hypertrophy of heart.*—Anasarca.	Adhering to the walls of the left ventricle were numerous softening clots; and a few were attached in the apex of the right.		
21	40	F.	*Extensive deposit of miliary tubercles in both lungs; ulceration of large intestines.* — Malformed, but competent, aortic valves.	Entangled among the carneæ columnæ, towards the apex of the left ventricle, were a number of decolorised coagula. They were rounded, somewhat ribbed on the surface, and, for the most part, of a whitish, or buff colour. On section they presented a more or less variegated appearance, from the persistence, in many places, of the original deep blood hue. None of them were softened.		

	Age.	Sex.	Disease.	Description of Clots.	Microscopic Description of Clots.	History.
22	19	F.	*Adhesion of pericardium; hypertrophy of heart.*—Pulmonary apoplexy; anasarca.	Entangled among the carneæ columnæ of the right ventricle, were several buff coloured softened clots.		Rheumatism, with heart affection, nine months before admission. After cure of rheumatism her health was moderate, till one month before admission. Anasarca came on and shortly after she had hæmoptysis. On admission she had swelled legs orthopnœa, cough, and expectoration of blood. Heart's action violent, but sounds feeble, and without decided murmur. Pulse feeble, at times irregular, and from one hundred and twenty to one hundred and fifty. She continued in much the same state, except

	Age.	Sex.	Disease.	Description of Clots.	Microscopic Description of Clots.	History.
						that she became easier, and the hæmoptysis ceased for two or three days before death. She died eight days after admission.
23	45	M.	*Apoplexy; kidney disease.* — Hypertrophy of heart; pulmonary apoplexy; anasarca.	Softening clots in left ventricle, and both auricular appendages.		The details of this case precede the report.

27. *Fibrinous Deposits in the Substance of the Heart.*

H. E. æt. 33, admitted on the 24th of October, 1855, into St. George's Hospital. Anæmic, complaining of heaviness and soreness in the chest; swimming in the head, and of fainting fits, which have occurred frequently during the last six weeks. Says, that during the fits, he is not perfectly insensible. Eight months ago he had slight hæmoptysis, with cough and pain in the chest.

For the last four years he has been a shoemaker, and has drunk hard of brandy; previously he had been a gentleman's servant for fifteen years in the same situation.

On admission, the pulse was thirty-six, and feeble. The heart's sounds were free from murmur, but very distant, and the impulse was feeble. There was no increased præcordial dulness. The respiratory murmur was over clear at apices, and there was no dulness. At the bases of the lungs, posteriorly, the breathing was deficient, and mixed with moist sounds. There was very slight œdema of the ankles.

No information could be obtained how long the pulse had been so slow. Up to the 31st no change was observed in his symptoms, the pulse was, up or in bed, thirty-six. There was some frothy expectoration, for which a blister was applied, and steel, with diuretics and expectorants, were given with some relief. On the 31st, at the time of my visit, I found the pulse only twenty-eight. He sat up to have his chest examined, and did not appear more ill than on his admission. Half an hour afterwards he complained to the nurse of faintness; there was grinding of the teeth, twitching of the hands, but not of the legs. He could scarcely swallow some brandy which was given. His pulse at first gave twenty beats in the minute. He had three of these spasmodic attacks, in the last of which he died.

Post-mortem.—Vascularity of dura mater and inner surface of bones. Convolutions dry, with small quantity of fluid in ventricles. Substance healthy. There was opaque, reddish-brown fluid in pericardium. Spleen very large and soft; no deposit. Kidneys much congested. The heart proved very vascular; a

few shreds of lymph on surface, and some old lymph; the heart large, flabby. The right cavities of normal size and thickness, and lining membrane healthy. The left cavity dilated, and the walls of the ventricle especially atrophied, and the columnæ carneæ smaller than natural. The endocardium, covering left side of septum was opaque and thickened, and in the muscular substance beneath, there was deposit of fibrinous looking matter. Numerous old pleuritic adhesions on the left side of lungs, much congested behind. Liver large; capsule opaque.

Examination of the deposit.—The deposit* was situated on the left side of the septum ventriculorum; it was firm in texture, of a yellowish-white colour, varied in thickness at different parts, was disposed as a uniform layer beneath the endocardium, and corresponded only with those parts of the endocardium that presented traces of chronic inflammation. Careful examination showed it to consist of a fibrinous deposit, which was infiltrated in the muscular tissue. It was chiefly granular, with nuclei and nucleated cells embedded in it, whilst the muscular fibres in which this deposit occurred were found much altered; they had lost the beaded appearance they present in their natural state, in some parts presenting a finely granular appearance, and in other parts the fibres presented a longitudinal fibrillated appearance, bearing a close resemblance to some forms of fibrous tissue.—*Mr. Gray.*

Dr. Bence Jones, *20th of November*, 1856.

---

28. *Fibrinous Deposits in the Spleen, Kidneys, &c. from a Case of Carditis, with Softening of the Brain.*

These specimens of fibrinous deposit were taken from a female patient, æt. 16, who was admitted into the Middlesex Hospital for acute bronchitis. She was well developed, and had a florid countenance, but was nervous, hysterical, and only spoke in a whisper. There was dyspnœa, and cough, with rhonchus and sibilation heard all over the chest. The heart's action was

* See a further description, with illustrations by Dr. Bristowe, on a subsequent page, in connexion with Mr. Sidney Jones's case of tumor of the scapula.

loud and forcible, especially at the back; but there was no bruit. The pulse was seventy-two, scarcely perceptible and irregular in the right wrist, and altogether absent in the left.

Under treatment, with saline antimonials, &c. the bronchitis gradually diminished; but she refused her food, became more peevish and obstinate, occasionally grew restless, and had fits of crying during the night. In the course of a week the pupils became dilated, but were not insensible to light; the heart's action became very irregular; the pulse in the right wrist was still slow and feeble, in the left not perceptible; the pulsation in the vessels of the left leg, below the knee, was then found to be scarcely perceptible, and both left extremities were decidedly colder than those of the right side. Although the nights were afterwards passed more quietly, yet her distress continued great, with frequent moaning and crying, and a look of weakness approaching to idiotcy. Her complexion remained healthy, but muscular power now failed on the left side, and there was much pain in the lower extremities. For several days she refused to take almost any food, so that at one time beef-tea was administered by the stomach-pump on account of the extreme weakness. Subsequently she again took sufficient nourishment, and, on the twelfth day after admission she seemed better, enjoyed breakfast, and made signs for more bread and milk, but soon afterwards she suddenly expired.

On examination, the dura mater being removed, the arachnoid membrane was found distended by a serous effusion, which in some parts raised it up from the convolutions. The left hemisphere, about the middle of its external surface, presented a depressed softened patch, about the size of a crown-piece; on slicing off the upper portion of this hemisphere, the white central part exhibited a pinkish appearance, and was decidedly softened; opposite the depressed part just noticed, the grey matter was entirely softened and broken up, presenting a creamy, pale, pinkish-yellow appearance, which extended somewhat into the white substance. The lateral ventricles contained about two drachms of clear colourless serum. The right hemisphere was not softened. On examining the left middle cerebral artery, a thin fibrinous clot, not nearly filling the

vessel, was found to run from its origin for about one inch and a half; here the artery bifurcated, and a dark black clot filled and plugged up the two branches; on tracing these branches, they were found to proceed exactly to the softened patch of grey substance already described. The right lung was much congested, and at the back and upper part, was nearly in a state of red hepatisation; but anteriorly, crepitant. The left lung was pushed upwards by the enlarged heart, and was adherent to the pericardium and costal pleura; on section, it presented a tough, dark, compressed appearance, with small reddish-brown consolidated patches in the upper lobe. The bronchi were congested and filled with thick, brown, frothy mucus. The pericardium contained about six ounces of straw-coloured serum, and a small patch of recent lymph on the anterior surface of the heart. The heart weighed nineteen ounces; both sides were filled with soft black coagula; the cavities were all enlarged, and their walls thickened. The left ventricle was most enlarged and hypertrophied; at the cut edges a whitish fibrous looking substance was observed diffused through the walls, in the form of little radiating patches, but at some places this substance was uniformly mixed with the muscular tissue of the heart, which was of a very pale yellowish-brown colour. The valves were healthy. The lining membrane of the left auricle was thickened, and covered by fibrinous layers which could be peeled off. The liver was much congested, the interlobular substance increased in quantity. The spleen weighed four ounces and a half, and on section, exhibited large, firm, irregular (fibrinous) masses, of a yellowish-white colour, its thin lower portion being almost entirely converted into this substance. The left kidney weighed three ounces and a half, and at its middle and anterior part presented a small depressed patch composed of firm yellowish substance, on the surface of which a few nodules of healthy looking renal tissue were seen. The right kidney weighed only one ounce and a half; it was much deformed, and consisted, for the most part, of firm yellowish substance, very little of the renal structure remaining free from deposit. The axillary and left common femoral arteries were found plugged by fibrinous coagula about

one inch long, which were adherent to the lining membrane, and of a reddish-yellow colour.

Remarks.—Although a cachectic state of the blood and purulent infiltration are often accompanied by cerebral symptoms, yet they do not generally produce any marked disease within the brain. In this case, I am inclined to consider the limited patch of softening of the grey substance due to the obstruction in the branches of the middle cerebral artery supplying it; but this will not account for the softening of the remainder of the left hemisphere, which I think we must look upon as a propagation of the inflammatory process, and this seems probable, inasmuch as the right hemisphere is quite free from disease. But the fact of the deposit occurring in so many organs, and its blocking up such large arterial trunks as the axillary and femoral, would seem to indicate that the cause of the disease was in the blood itself; if not, we must then look to the mischief in the heart. There were no vegetations on any of the valves, but a fibrinous deposition existed on the lining membrane of the left auricle; and that the heart itself had been inflamed there can be no doubt, the inflammatory exudation having been converted into white fibrous masses which, on microscopic examination, exhibited wavy bands of areolar or connective tissue. It appears doubtful whether the obstruction in any of the arteries was produced by fibrinous particles carried direct from the heart, and it seems altogether more probable that the blood was, as it were, overcharged with fibrine, that a spontaneous coagulation took place in the larger as well as in the smaller arteries, and that this was followed by decoloration of the clots.

Previous history.—The patient whose case I have just described was an inmate at St. George's Hospital shortly before her admission at the Middlesex; and my friend Dr. Ogle has kindly furnished me with the following particulars. The catamenia only appeared twice in her life; but her general health had been good. Four months after the last period she was affected by pain at the right side of the head and face, as if from cold. A few days after, she awoke in the morning and

found she had lost all power in the right hand and arm, and could only *drag* her right leg along the ground. She had also lost her voice, but was not aware that she had had a fit or anything of the kind; she had not spoken since. When admitted into St. George's Hospital there was diminished sensation in the right arm and hand, which were swollen, and great loss of power and sensation in the right leg. Though she could not speak, yet she made many attempts; the mental powers seemed entire. The pupils were natural, and no distortion of the facial or other muscles existed. No pain was complained of, and no cough existed. The secretions seemed well formed, but the pulse was very weak, and the heart's action rather intermitting. No unnatural sounds of the lungs or heart existed; and no albumen in the urine. After a time the patient began to speak slightly in a whisper; but she never got beyond saying, "Oh!" or "Yes," and "No," with tolerable loudness.

In time she recovered the power of the right arm and hand, and could lift the arm above the head. This good seemed to be the effect of galvanism. When she had been in the Hospital some weeks she complained of sickness, and vomited her meals, and was greatly depressed in spirits. Blisters were applied to the neck, and she gradually improved in every way, saying one or two words occasionally. She went out of St. George's Hospital very much better, and promised to present herself shortly; but was admitted at the Middlesex, as already described.

Dr. Van der Byl, *15th of January*, 1856.

Report on the preceding case.—The case brought before the Society by Dr. Van der Byl, appears to be one of acute arteritis, associated with endocarditis; and illustrates very strikingly some forms in the pathology of these affections; more especially with reference to the production of plastic matter within the arteries, as the result of their inflammation, and to the consequences of its diffusion through, and accumulation in, different parts of the vascular system.

In acute idiopathic arteritis, the plastic matter that is forced out by the inflamed patch in the artery, appears to be disposed of in four different ways.

1. It may be deposited upon, and become adherent to, the lining membrane of that portion of the vessel which is inflamed. In such cases as these the artery will be found to be plugged up, more or less completely, by firm, tough, leathery, buff-coloured fibrine, which is so closely adherent to its lining membrane, as to be stripped off with difficulty from it. The calibre of the artery itself will be contracted at this point, so that the contained plug is firmly embraced by it. These appearances are well illustrated by the axillary artery in Dr. Van der Byl's case.

If the plug occupy a considerable portion of the vessel, and particularly if so situated in an artery of the extremities as to occlude the mouths of the chief collateral vessels of the limb, gangrene will not improbably ensue. If of limited extent, as in Dr. Van der Byl's case, the interruption to the circulation will only be sufficient to occasion coldness of the extremities, with deficient or absent pulse.

In every instance of this kind which has fallen under my observation, there has been, as in Dr. Van der Byl's case, pains in the limbs, sometimes of an intensely severe character, and occasionally associated with an exquisite degree of cutaneous sensibility.

2. The plastic matter not completely blocking up the artery at the point originally inflamed may be washed down by the current of blood still passing across it into the lower portion of the vessel, and there accumulating in the form of a firm maroon-coloured cylindrical coagulum, may obstruct the terminal branches to such an extent as eventually to lead to gangrene of the limb. Between the two points so obstructed, a portion of the artery will usually be found to be pervious. It is, I believe, this obstruction of the artery at a second point, at some distance below the primary seat of disease, that causes arteritis so frequently to be followed by gangrene; the obstruction occasioned by the second or distal plug of lymph being so complete and so occlusive as to render it difficult for the circulation to be carried on with the requisite amount of vigour to maintain the vitality of the part. This appears to be the state of things in the femoral artery of Dr. Van der Byl's case, in

which there is a plug composed of the ordinary buff-coloured fibrine, then an interval of healthy pervious artery, and then a portion of the vessel plugged up in the way already mentioned. As to what distance this secondary deposit extended it is impossible to say, as the vessels have been cut off short. Although existing to a sufficient extent to impede seriously the circulation, it was evidently, from the symptoms during life, not sufficient to arrest it entirely.

The plug of lymph in the left middle cerebral artery appears to have been of the same kind, and the softening in the corresponding hemisphere of the brain to have been dependent on the obstructions in this vessel.

3. The plastic exudation that is poured out by the inflamed vessel, may be washed by the current of the blood into the capillaries of organs beyond the seat of diseased action, especially the spleen and kidneys, and, becoming arrested in the ultimate ramifications of the vascular system, accumulate in the form of light buff-coloured, or reddish-yellow fibrinous concretions. These may also form as the result of endocarditis, as has been specially pointed out by Hasse; and as the endocardium appears to have been inflamed in Dr. Van der Byl's case, I think it most probable that the yellowish-white fibrinous masses formed in the spleen, kidneys, and heart, proceded from this direct source, rather than from the more distant one of the inflamed arteries. The fibrinous concretions found in the substance of the heart itself probably resulted from the exudative matter carried directly from the interior of that organ through the coronary arteries; and so far as my observation goes, this is not a frequent form of this deposit.

4. Fibrinous concretions may form in large and distant venous trunks, as the result of arteritis; but as there is no evidence of its having occurred in Dr. Van der Byl's case, it is needless to pursue further this pathological condition.

Mr. Erichsen, *5th of February*, 1856.

---

29. *Fibrinous Coagulum, obstructing the Left Common Iliac Artery, and causing Gangrene of the Leg.*

A married woman, æt. 39, was admitted into the Middlesex Hospital, under the care of Mr. De Morgan, on the 4th of March, 1856. She was tolerably stout, robust looking, and two months advanced in pregnancy. She stated that about three weeks before she began to feel shooting pains, with a sensation of numbness and coldness in both legs and feet. After stooping down to pick something from the ground (six days previous to her admission), these symptoms became increased in the left, but passed away completely from the right leg. On admission, there was no pulsation in the left femoral artery, which could be felt, hard and cord-like. The foot and leg, nearly as high as the knee, swollen and crepitating on pressure, was of a purplish green colour; the toes nearly black, covered with bullæ, containing a dark fluid, cold, without sensation, and emitting a gangrenous odour. The right leg natural; great anxiety of countenance; pulse small and irregular; the general surface cold and moist. The gangrene continued to extend, reaching, ultimately, the upper part of the thigh; the general symptoms increased, and she died two days after her admission into the Hospital.

On *post-mortem* examination thirty hours after death, a firm, yellowish-white, elongated, fibrinous coagulum, about the size of an almond, but rather thicker, was found lying in the entrance of the left common iliac artery, which it completely obstructed, its upper end projecting into the aorta: it was not adherent to the artery, and the lining membrane of the latter presented no discoloration or sign of inflammation at this part. Below this, the common iliac, external and internal iliac, and femoral arteries, with all their branches, were filled with dark-coloured and tolerably firm coagulated blood.

The pericardium contained about an ounce of straw-coloured serum, and a little recent lymph was deposited on the surface of the heart, near its base. The heart was flabby, with much fat about the base, and weighed eleven ounces and a half.

The right and left cavities both contained a considerable quantity of coagulated blood; and, embedded in this, and not

adherent to the walls of the heart, were three or four firm, whitish, fibrinous coagula, about the size of hazel-nuts, exactly resembling that in the iliac artery, but firmer, more opaque, and of altogether different appearance from the ordinary colourless coagula usually found in the heart after death. Owing to an accidental circumstance in the examination of the heart, it was not ascertained in which of the cavities these were found; but it is believed that they existed in both the right and left ventricles. The mitral valve was much thickened, the orifice contracted, the aortic valves somewhat thickened and shrunk. The right pleura contained about half an ounce of serum; the left eight ounces. Slight adhesions at both apices.

The lungs somewhat congested, with limited patches of hepatisation, both red and grey, in the lower lobe of the left.

In the spleen was a distinct fibrinous deposit, about an inch in diameter, of a reddish-grey colour, with a few darker spots.

The liver weighed forty-eight ounces and a half; capsule somewhat thickened; on section pale, and slightly fatty.

Kidneys congested, somewhat granular on the surface, capsule adherent.

Brain healthy; no obstruction in any of the cerebral arteries.

There can be little doubt that the coagula found in the heart had formed sometime previous to death, being the result of some peculiar condition of the blood; and the symptoms would indicate that one of these, having escaped from the heart, and found its way into the general circulation, had at first been arrested at the bifurcation of the aorta, where it gave rise to partial obstruction of the circulation of both extremities; afterwards, perhaps in the act of stooping down, it became tilted into the left iliac artery, completely obstructing that vessel, while the current of blood was thus allowed to pass freely again through the right leg.

A careful examination of the coagulum found at this spot, and of those discovered in the heart, appears to show that they are identical in nature; and that the obstruction is not the result of local disease of the artery is well seen in the preparation, which is now in the Museum of the Middlesex Hospital.

Mr. W. H. Flower, *6th of May*, 1856.

---

30. *Large quantity of Fibrinous Deposit within the substance of the Kidney, the Supra-renal Capsule, the Renal and Supra-renal Veins, perfectly converted into Fat. Total Obliteration of the Inferior Vena Cava of old standing.*

The left kidney contained a mass of soft, putty-like, pinkish-coloured material, occupying a very large portion of its anterior half; and the same was the case with the left supra-renal capsule, which was exceedingly large, owing to its extensive destruction and occupation by soft deposit like that in the kidney. The left renal vein was exceedingly large in calibre; even larger than an ordinary vena cava, and almost quite distended by the same kind of soft material as before spoken of. This was likewise the case with the left supra-renal vein, which was very greatly enlarged. The right supra-renal and renal veins were natural. The entrance of the left renal vein into the inferior vena cava was open and free; but below the communication the entire vena cava was filled by firm, fibrinous, indurated material, and was shrunken and reduced to the state of a dense thick cord. This was of very old standing, as the contained material was with great difficulty separable. There was also much soft recent fibrin blocking up the left external iliac vein. The left kidney was, moreover, very softened and granular; and the right one was to a slight extent diseased, its surface being granular. The right supra-renal capsule appeared tolerably natural.

The abdominal viscera generally were congested, as were the lungs; and the heart was very soft and flaccid. The costal cartilages were found to be unusually ossified; and the integuments were of a very yellowish colour. Moreover, the superficial abdominal and thoracic veins were greatly enlarged.

Microscopical appearances.—The appearance of the deposit, wherever examined, showed that it had undergone most complete fatty degeneration; nothing being seen but large globules of oil, quite as large as the fat-cells of ordinary adipose tissue, not a trace of anything like cell, or fibre, or nucleus being observable. Hence it is to be inferred that this large accumulation

of fatty substance was originally deposited as such; or, what is more probable, was owing to the conversion of an albumino-fibrinous material, and was not a specific deposit, either scrofulous or carcinomatous. No blood-cells were visible, so that if they were originally mixed with the matter, they had undergone alteration at the same time.

History.—The preparation was removed from a man, æt. 50, who was brought into St. George's Hospital, suffering from ascites and anasarca. The pulse was quick, and the tongue furred: the urine was scanty and albuminous. He was accustomed to drink freely of gin, and, in his trade as a carpenter, had been much exposed to wet. About ten weeks before admission into the Hospital, he had suffered much from pain in the loins. Under the use of diuretics, purgatives, and stimulants, he improved. Pain in the chest came on, and dyspnœa, which increased, and became paroxysmal. The patient died in an attack of dyspnœa.

It was specially worthy of observation in this case, in connexion with the disease of the supra-renal capsule, that no kind of discoloration of the integuments was observable.

Dr. J. W. Ogle, 20*th of May*, 1856.

IV. DISEASES, ETC. OF THE ORGANS OF DIGESTION.

1. *Specimens of Imperfectly Calcified Dentine.*

In the development of the sclerous tissues, the complete impregnation of the animal basis with calcareous material is the all-important item of their normal evolution; and anything which interferes with, or prevents, this nutritional process damages the physical, and as the functional are dependent on the physical, damages also the functional, characters, of the structures in question.

These remarks apply just as much to the tissues composing the teeth as they do to the bones of the skeleton.

The subject of imperfect dentine calcification is not new.

It has been noticed, though its anatomical appearances have been singularly misinterpreted, by Mr. Tomes.*

Czermak has referred to it, rather in its explanatory relation to the calcification process as it occurs in a normal way, than as a pathological condition: and he, indeed, it was, who first gave a correct explanation of the appearances in question.

In a pathological sense, in some of its details, it has been correctly, though briefly, described by Wedl, and fairly figured by him.

The anatomical appearances have as yet, however, never been described thoroughly in themselves, or in all their detail, or in relation to the different parts of the tooth affected.

The specimens upon which the following descriptions are based thoroughly illustrate the anatomy of this subject, and an account of them will probably be not out of place, if submitted to the Pathological Society.

The morbid condition I am about to describe, being an incompletion—an arrest at a half stage—of that which is a normal process, it will be necessary for me to allude to the change as it occurs in a regular and healthy course, and the more so, as this is not described in any of our English textbooks on histology.

* The account which Mr. Tomes gives of the interglobular spaces of dentine, and the explanation of their production, is not a little remarkable. Assuming the "conversion" theory in its severest form, though in a manner quite incompatible with his own account of the histological development of dentine, Mr. Tomes says, that the interglobular spaces are caused by the imperfect calcification of the *areolar* tissue of the tooth-pulp, and in confirmation of this doctrine he gives three illustrations, figs. 47, 48, and 49,—one exhibiting "the dental pulp in its first stage," said to be from Todd and Bowman's "Physiology," but which certainly is not in their work, and displaying appearances with which I am wholly unacquainted. A second figure, being "portion of areolar tissue inflated and dried," *magnified twenty diameters*, exhibiting only the coarse arrangement of ordinary subcutaneous areolar tissue, as seen with very low powers. A third figure, displaying interglobular spaces in a section of dentine, *magnified at least three hundred diameters;* and because the outlines of the latter, showing ultimate histological elements, resemble (and the resemblance is sufficiently remote) the outlines of a piece of dried subcutaneous areolar tissue, as coarsely seen with a power of twenty diameters—therefore they are one and the same structure!

I need scarcely observe, in reference to the coarse anatomy of a developing tooth, that the dentine of the organ commences formation upon, or rather in the surface-structure of the formative pulp, and that the increase of growth is from above and without, downwards and inwards—the growth being strictly endogenous. The manner in which the particular structure of dentine (tubes and intertubular substance) is produced, I need not stop here to notice, as the subject I am discussing—calcification of the animal basis, here in an incomplete form—has no sort of relation to histological forms previous to earthy impregnation.

When a very small and thin layer of dentine (its organic element) is formed upon the upper outer surface of a tooth—and I would here use the term *layer* rather for convenience of expression than as implying a truly laminated structure, though a sort of latent lamination does really exist—when, then, a thin layer of dentine in a soft state is formed over the surface, its calcification rapidly follows the development, only a very minute thickness of animal substance anticipating this change.

Now the calcification consists not in an even, slow impregnation of the whole basis with earthy matter, nor in the interstitial deposit of earthy particles in a web of animal matter, nor a change having relation to the course of the tissue affected: it is an independent element of nutrition, affecting isolated points of the animal basis—points which become completely calcified, while the intermediate tissue remains unchanged. These points gradually invading the contiguous tissue evenly enlarge in each direction, becoming spheres; these still enlarge till they touch each other, and, progressing still further, gradually merge into one another; and, if the process continue to its complete issue, the fusion is so thorough that all indication of the calcification globules, and the intermediate uncalcified cartilage (if cartilage it may be called) is obliterated. The dentine is even, compact, and complete.

If, however, from a deficient nutrition, from an imperfect supply of calcareous matter, the animal basis of the dentine

becomes only partially calcified, then the calcification globules remain distinct, or are partially fused, the intermediate cartilage being soft and unaltered; still the internal growth goes on, fresh layers of dentine being formed, thus separating the imperfectly developed layers from the nutritional influences of the vascular element of the receding pulp. A thin layer of dentine appears to be sufficient to effect this purpose, and this may itself be completely elaborated or not; but when once this separation has occurred, no change appears to take place subsequently in the imperfectly calcified layer, and that which should have been a temporary and transient condition becomes permanent, and, therefore, abnormal.

It must be remembered that during life, though there is this great difference in density between the calcified globules and the interglobular cartilage, there is no interruption in structural elements; the interglobular space is completely filled with uncalcified cartilage, and the dentinal tubes pass indifferently through the hard and the soft structures. When, however, such teeth are extracted and allowed to get dry, the tenuous animal substance shrinks and dries up to a mere film, while the calcified globules remain hard, sharp, and firm. These circumstances it is necessary to recollect, as they imply and explain certain optical appearances which would otherwise be unintelligible. The result of the drying up of their animal substance is, that interspaces filled with air occur between the globules, have outlines exactly corresponding with the spherical bulgings of the hardened dentine. These interglobular spaces are opaque-black by transmitted light, and dead-white by reflected light; on the same principle, and for the same reasons, as such is the case in the tubes and loculi in dentine and the lacunæ canaliculi and interspaces in bone.

This condition of half calcified dentine may exist in any degree, from the slight indication known as the "contour marking," in which thin alternate layers exhibit this state to a slight degree, to others in which the whole mass of dentine is a conglomerate mass of globules.

The first specimen I have to describe, is that of a bicuspid tooth, which exhibited this condition in a very marked degree.

The tooth itself was very white and opaque in colour when whole. Its history, and that of the individual from whom it was obtained, I do not know. A section of the tooth exhibits the same white opacity; and, when seen by transmitted light, it is very black and opaque. The enamel is unusually perfect for a tooth exhibiting this defect of calcification.

Viewed under the microscope (*see* Plate VII.) with a magnifying power of ten or twelve diameters, the dentine of the crown exhibits an irregularly disposed layer of granular, imperfectly calcified dentine over the whole, but separated from the enamel by a thin layer of tissue perfectly developed. The dentine near the pulp-cavity, both of the crown and neck, seems to be perfectly formed. In passing from the crown to the neck and root, the opaque layers and masses of imperfectly calcified dentine are seen to be arranged in irregular lines, having a direction downwards and outwards, and, in passing down the tooth, it will be seen that the outward direction diminishes, while the downward increases, till the lines become almost parallel with the outline of the tooth. The direction of these lines is rendered apparent by alternate layers between them of perfectly formed dentine. These lines of opacity are neither more nor less than contour lines severely expressed.

It will be observed that these masses of opaque dentine are most apparent and marked towards the outer surface of the tooth; and the cause of this is obviously to be accounted for thus:—in the growth of a forming tooth, an expanded cap of dentine, as at first seen, is ultimately converted into a cylinder with a tube up the centre, and, to effect this, it is necessary that the growth on the outer limit of the tooth should be rapid, while that in the centre is slight, and when the crown is formed, almost none; thus, where there is the largest demand, the supply being deficient, there the result of the imperfect supply is most marked.

Towards the extremity of the fang the dentine is wholly globular; none is perfectly formed, and all indication of lamination is lost.

It *usually* happens that, when the dentine of the crown exhibits imperfect calcification, the enamel is imperfect at a

DESCRIPTION OF PLATE VII.

The figure illustrates Mr. James Salter's remarks on Imperfect Calcification of Dentine, p. 178.

The representation is of a section of a bicuspid tooth, as seen with a magnifying power of about 10 or 12 diameters.

Trans Path Soc Vol V P. VII

E M Williams del. Tuffen W[illegible]

W West Lith[r]

DESCRIPTION OF PLATE VIII.

The figures illustrate Mr. James Salter's remarks on Imperfect Formation of Tooth Structure, p. 183.

Fig. 1. Represents a section of an incisor tooth, showing imperfect formation of enamel, and imperfect calcification of dentine, at the parts immediately beneath the irregularities in the enamel. Magnified 7 diameters.

Fig. 2. Dentine globules, the interspaces perfectly black from contained air. Magnified 200 diameters.

Fig. 3. Globular dentine, the interspaces filled with Canada balsam. Magnified 200 diameters.

Fig 1

Fig 2



Fig 3

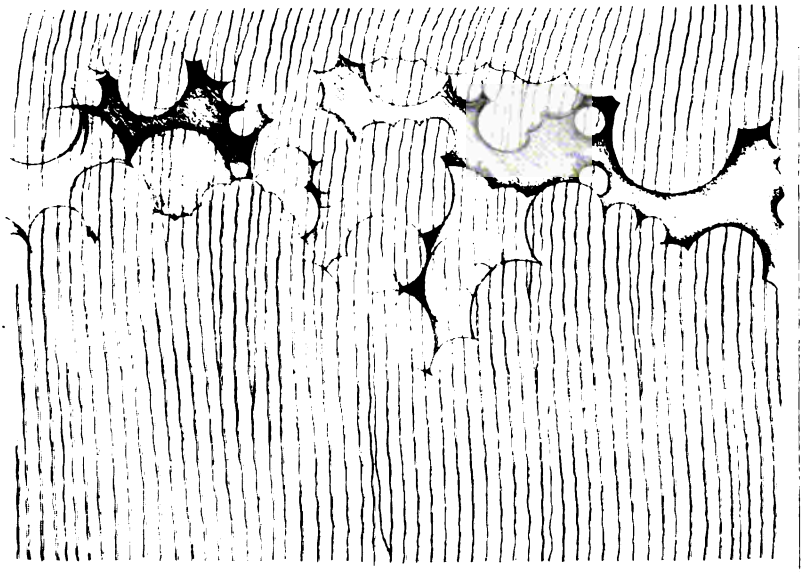

Dr Hyde & Mr Jas Salter del. Tuffen West sculp. W West imp.

spot corresponding with the external abutment of the imperfectly calcified layer, and exhibits the condition known as "rocky" enamel,—the converse of that is, I believe, *constant*, namely, that whenever a tooth exhibits rocky enamel it will be found that the dentine beneath the grooves, irregularities, or pits, displays the condition I have been describing. This will be seen illustrated in Fig. 1. Plate VIII.

If a section of imperfectly calcified dentine be examined dry, or mounted in Canada balsam so rapidly as to prevent the fluid resin from running into and filling up the interspaces, the dentine globules are seen in various spherical and convex forms bounded by black, opaque, interspaces (Plate VIII. Fig. 2.). The dentine in the globules themselves is perfectly formed, and the tubes may be traced across the globules, and skipping the interspaces across succeeding globules as though in a continuous line. The globules are largest towards the centre of the tooth, and smaller and more numerous towards its surface, where, in the fang, they spread out beneath the crusta petrosa, forming, what Mr. Tomes has called the "granular layer." The term "layer" is incorrectly used, for it is not continuous beneath the crusta petrosa, being interrupted, and only the external abutment of the sheets of imperfectly calcified dentine.

If a specimen of globular dentine be mounted slowly, so that the Canada balsam can run in and fill the interspaces, the structure looses all its black opacity, and becomes very transparent (PlateVIII. Fig. 3.). The conglomerate nature of the mass is very distinct, and exhibits a curious appearance: some of the globules are sharp, clear, and in focus, while others are indistinct and looming obscurely out of focus; some isolated and spherical, others fused together in every variety of proportion.

The circumstances under which this condition is produced, all point to a depressed and imperfect nutrition at the time of development, as its cause :—

1. I believe it is almost universal in rickets: at least, as far as my own experience goes it is so : and it has been observed by others in that diseased condition.

2. It frequently happens that an illness in early childhood affects the layer of dentine that is formed during that period, and this is in the form very generally associated with rocky enamel. Where this is the case, all the teeth are affected—at least all that have commenced calcifying—not at the same part in each, but at a position which corresponds with the amount of development which each tooth had attained at that particular time.

3. This condition is not infrequent where the tegumentary organs generally are feebly developed. I have noticed this especially in young ladies with preternaturally thin and transparent skins, with short papillæ, whose eyelashes and eyebrows are small and thin, hair of the head very fine and soft, papillæ of the tongue very short. There is a peculiar stamp of complexion which is characteristic: and in these people the teeth are usually found very small, the cusps short, the fangs short, and the dentine exhibiting this condition of imperfect calcification—the teeth, in fact, as dermal organs, sharing in the general defect of the tegumentary system.

Mr. James Salter, *20th of May*, 1856.

---

2. *Specimen of Dentine of Repair.*

The specimen that is the subject of this communication exhibits, with much clearness and precision, two examples of the development of that peculiar form of secondary dentine known as "dentine of repair," developed on one side as the recompense or repair for lesion, the result of grooving of the neck of the tooth by mechanical friction; on the other as a compensation for the inroads of superficial caries.

The tooth in question was a canine which I removed from the mouth of an aged person. The front of the tooth exhibited at the neck, the horizontal grooving which is so frequently seen as the result of much mechanical friction.* The groove was

* I cannot lose an opportunity of correcting a palpable mistake recently committed by Mr. Tomes, in reference to the sensibility of superficial dentine laid bare in horizontal grooves by friction. In support of a theory by which he endeavours to account for the sensibility of dentine by a

rather flatter and broader than usual; it was very polished. The summit of the cusp was also somewhat worn by the attrition of mastication. On the posterior surface of the neck of the tooth was an excavated carious cavity, situated between the enamel and crusta petrosa, having eroded each to some extent. The caries was not in an active state, but hard and indolent.

The illustrations (Plate IX.) represent a section of this tooth, vertical, from before, backwards. In making the section, a portion of the enamel of the summit of the cusp chipped off, and, from a bending in the fang, it was not possible to open the pulp cavity from end to end (*see* Fig. 1.). The upper half is exposed in about its centre; in the lower half the dentine of the fang is exhibited just one side of the pulp cavity. The groove in the front of the neck of the tooth is seen to be deep and broad. Following the dentinal tubes from the limits of the excavated surface, in their waved course, downwards and converging, to the pulp cavity, we see in the latter a plano-convex mass of supplemental dentine imposed upon the primary tissue, corresponding in its boundaries with the external lesion, and opposite to it: not that the dimensions are the same, nor that the position is mathematically opposite; but thus,—in passing from without, inwards, the tubes converge and descend; converging, they occupy a less space in the pulp cavity, and descending they occupy a position below. The repair, therefore, is equal to the lesion, and opposite to it, not mathematically, but physiologically. In this instance, as is the general rule, all the dentinal tubes (neither more or less) that are shortened and wounded without, are prolonged and repaired within. Usually

nervous supply, Mr. Tomes, in a paper recently read before the Royal Society, an abstract of which has appeared in the Society's proceedings, asserts that the dentine, laid bare by the superficial grooving of the necks of teeth, in which the tubes have been filled with secondary calcific deposit, *is not sensitive.* A statement more at variance with general experience, cannot be conceived. As far as my own observations are concerned, and the observations of many Surgeon-Dentists of much experience of whom I have made inquiries since the appearance of Mr. Tomes's statement, I would say, that under no other circumstances is dentine so frequently, or so intensely, sensitive, as in the condition in question.

masses of dentine of repair are peculiarly glassy and transparent; and the tissue between it and the external surface partakes of the same character, arising, not from the absence of tubes, but from their being filled up by secondary deposit within them. In the portion of the present specimen that I have been describing this character is peculiarly absent, the tubes being open and opaque.

On the posterior surface of the pulp cavity, somewhat above the former, is a mass of repair dentine corresponding to the superficial caries of the neck before mentioned. The relation of the repair to the lesion is the same as in the previous instance, with this exception, that it is rather in excess, and occupies an area somewhat larger than that represented by the internal abutment of the tubes externally damaged. The primary dentine between the caries and the repair is clear from tube obliteration; and the upper two-thirds of the repair is excessively clear from the same cause; and this transparent portion *exactly corresponds* with the tubes externally injured, the opaque portion being that which is in excess. The filling up of the dentinal tubes with secondary deposit, is always (at least in the human subject), a phenomenon associated with irritation and hypernutrition; and the circumstance that here the repair of the caries is mostly clear, and is in excess, and that the repair of the wear is opaque, and not in excess, would suggest the idea that the former is brought about by more energetic action than the latter; and that caries of the surface of the dentine produces more stimulation of the corresponding portion of the formative tooth-pulp, than the same amount of injury from mechanical wear.

In the summit of the pulp cavity will be observed a small patch of dentine of repair, corresponding with the worn point of the cusp. All these appearances may be seen by referring to Plate IX. Fig. 1. The relation of the repairs to the respective lesions, may, perhaps, be better understood by observing the outline sketch (Fig. 2.), a diagrammatic interpretation of the first figure.

This specimen is not published with any idea of novelty, but as illustrating in one section the phenomenon of dentine repair

DESCRIPTION OF PLATE IX.

The figures illustrate Mr. James Salter's remarks on a Specimen of Dentine of Repair, p. 184.

Fig. 1. Represents a section of a canine tooth, showing dentine of repair consequent on two causes of lesion, friction wear and caries. Magnified 8 diameters.

Fig. 2. Outline diagram of the above. Three instances of dentine of repair are seen, corresponding with

a. The worn point of the cusp.

b. Grooving by mechanical friction.

c. Incipient caries.

Fig

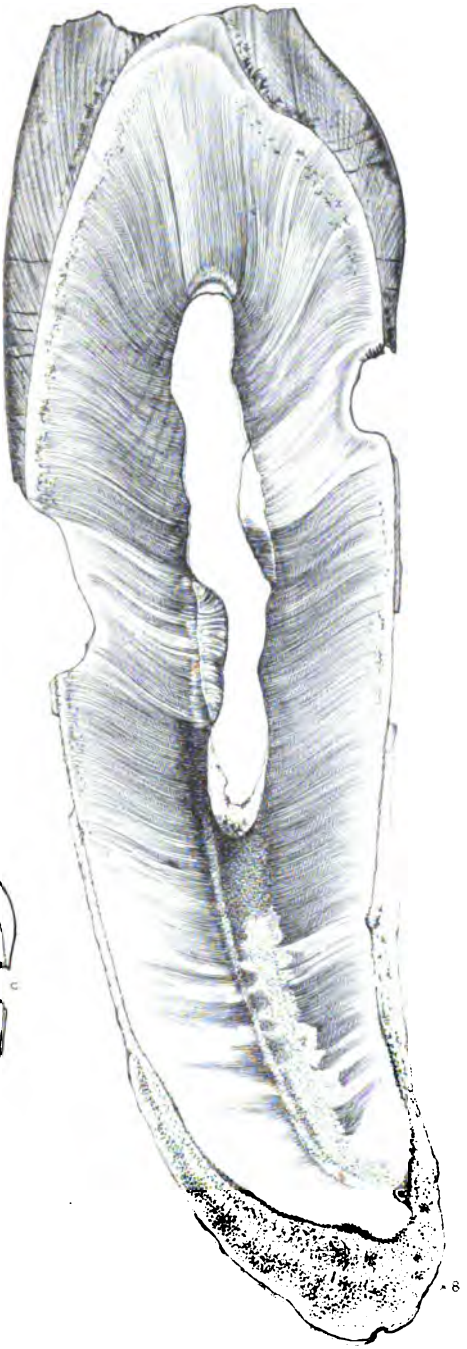

Fig 2

E M Williams del. Tuffen West sculp

W West imp

consequent upon two causes of lesion, — friction wear and caries.

Mr. James Salter, 20*th of May*, 1856.

---

3. *Papilloma, or Warty Growth on the Palate.*

A gentleman of middle age had been troubled with irritation in his throat for some months, and applied to Mr. Hilton for relief. That surgeon found, growing upon the soft palate, near the uvula, a small tumor of about the size and general appearance of the uvula itself. It was snipped off without the occurrence of much bleeding. It was submitted to Dr. Wilks for examination, who furnished the following report :—

The tumor was found to be nearly three-quarters of an inch in length, and about the size of a small bean; it resembled, in general appearance, a compact bunch of grapes, or perhaps, more nearly, a cauliflower, being composed of a number of small round lobes, each about the size of a pin's head, attached to a central axis. It was thus very like the warty epithelial growths seen on the penis, and other parts of the integument. Upon more minute examination by a lens, each of these nodules was seen to be made up of eight or ten smaller ones; and when a section was made and viewed by the same magnifying power, the usual appearance of a warty or papillary growth was distinctly visible. As in the cutaneous warty excrescence, the new papillary growths form distinct eminences or centres, around which the cell structure arises, and each contains within it a blood-vessel, so each lobe of this tumor was found to be composed of a number of circular growths corresponding to new papillary formations, made up of the most delicate cell-structure, and each containing within it a loop of blood-vessels. By this low magnifying power, however, these smaller lobules appeared to consist of thick fibrous capsules, arranged side by side, and containing within them the capillaries; but when placed under the microscope, their apparent fibrous structure resolved itself into simple epithelial cells, such as are found in the healthy palate. Upon the periphery of the papillary growths, these cells lay in juxtaposition, and their nature was clearly seen; nearer the centre

they were superimposed; and towards the centre many of them were of a much smaller size, and approached a linear shape, so that the appearance of fibres was readily given to them. In none was there a nucleus above the usual healthy size; nor were the cells conglomerated into masses or capsules; nor was any other appearance present indicative of a cancerous nature.

The tumor, then, was a simple warty or papillary growth, such as is seen in similar excrescences on the skin; only from being formed in the mucous membrane, the structures were far more transparent and delicate, and the blood-vessels were clearly seen. Such growths have by some been designated papilloma.

Mr. HILTON and Dr. WILKS, *4th of December*, 1855.

---

4. *Malignant Disease of the Cardiac End of the Œsophagus.*

In the specimen, tuberous masses of a dirty white colour are seen occupying the termination of the œsophagus. They extend from the cardiac orifice of the stomach upwards for the space of about three inches, and occupy more or less completely the circumference of the tube. In size they vary from a pin's head to that of a hazel-nut; they are more or less aggregated and grown together, presenting an irregular, somewhat softened and broken up appearance. The masses feel firm in some parts, soft and friable in others. Examined with the microscope, the constituents present the characters commonly found in the epithelial form of cancer.

The specimen had been removed from a gentleman, æt. 70, whom Dr. Quain had seen on several occasions, in consultation with Mr. Collambell, of Lambeth. The patient had long suffered more or less from dyspepsia. When he came under observation about twelve months before his death, his symptoms were a peculiar pain and uneasiness referred to the "pit" of the stomach, occurring during the act of swallowing food; spasms in the same situation, shooting to the ear, and flatulence. He had cough and some wheezing which disturbed him at night, and the force of which at that time sometimes caused him sickness. He had lost some little flesh; in other respects his functions were tolerably well performed. His tongue was

clean, his pulse quiet, his bowels kept open by "Morrisson's pills," which he took freely; his urine was healthy; he formerly had piles.

A careful exploration of the chest and abdomen revealed nothing beyond the signs of subacute bronchitis. Remedies were, in the first instance, applied for the relief of this complication, and with success. He was again seen after a month, and now complained almost entirely of the distressing grinding sensation opposite the epigastrium, when swallowing either liquids or fluids. He had no pain subsequently to the act of swallowing, and seemed to be able to digest his food tolerably well, save that flatulence occasionally distressed him. The distress in swallowing was sometimes so great as to deter him from attempting to take sustenance: he had lost flesh, and become decidedly sallow. There was no hardness or tumor to be felt at the epigastrium, which was merely more prominent than natural, and emitted a clear resonance on percussion. The symptoms pointed pretty clearly to some form of chronic inflammation, or of malignant disease about the cardiac orifice of the stomach. The remedies prescribed in accordance with this view, afforded, from time to time, a greater or less amount of relief, when, finally, about a fortnight ago, he was seized with symptoms of acute pleurisy, leading to considerable effusion into the right pleura. Beneath this attack he sank.

With the exception of the morbid condition just mentioned and that previously described, the organs of the body generally were as healthy as they are found in individuals of the like advanced age. Dr. QUAIN, *6th of November*, 1855.

---

5. Stomach in a Case of Poisoning by Essential Oil of Almonds.

The specimen was taken from a man, æt. about 39, whose mind for some time had been the subject of excitement. It appeared that on the morning of his death, whilst apparently in his usual health, he was met by his servant on the staircase descending from his sitting-room. On passing into the room, which her master had just left, this servant observed a tumbler and a bottle on the table, and almost immediately afterwards

heard a noise, as of a person falling, at the foot of the stairs. Hastening thither, she found her master insensible and groaning. He was immediately carried to his room, and Mr. Wright, of Edward Sstreet, a neighbouring surgeon, sent for. This gentleman came at once, and found him insensible, breathing, or gasping, slowly. He used some remedial means, but death took place in a few moments. It was estimated that ten minutes had elapsed from the time this individual took the dose, which proved fatal, to the time of his death.

The body was examined about fifty-four hours after death. There were some ecchymoses from position. There was no smell of prussic acid. There was much subcutaneous fat. On cutting through the abdominal walls, the previously absent smell of bitter almond emulsion was manifested. The stomach was removed, with a portion of the œsophagus and duodenum. On laying this organ open, it was seen to contain a quantity (ten drachms by measure) of a semi-transparent, oily-looking, liquid, which contained some albuminous-like flakes, and emitted an intensely powerful smell, as above mentioned. The stomach itself was large and capacious, contained no food (none had been taken since the preceding evening), and its surface was of a bright chocolate-brown colour, covered with large deep rugæ, and much mammilated, more especially towards the pylorus. The mucous membrane was softened. The œsophagus was coloured as the stomach. The pylorus defined this colour at the other extremity, for the duodenum was of a bright red colour. The whole appearance conveyed to the mind the impression that the stomach had been acted on by a powerful irritant.

The ten drachms of fluid were analysed by Mr. Redwood, and found to be pure essential oil of bitter almonds, each drachm of which contained 3·42 grains of anhydrous prussic acid. There were thus about thirty-five grains of this poison *removed* from the stomach, and it is probable, allowing for waste, &c. that the man had originally swallowed at least half as much again. The other organs, so far as examined, were found to be healthy. The arachnoid, over a portion of the left hemisphere of the brain, was opaque; and just at the ante-

rior extremity of the middle lobe below, the membrane was puckered and firmly adherent to the substance of the brain, of which portions came away with the membrane.

The point of especial interest in the case was, that so large a quantity of prussic acid could be swallowed, and yet the patient be able to walk from the first floor to the hall of an ordinarily sized London house. Dr. Quain believed that, in this instance, the protracted effects were due, in the first place, to the oily character of the medium which probably prevented rapid absorption, and, secondly, to the irritating characters of the essential oil. Dr. Quain remarked on the risks attending the common use of the essential oil of bitter almonds. The subject of this case had, by his position in business, the means of getting free access to this agent for the purposes of flavouring, and the bottle which contained it was labelled essence of bitter almonds, though it was really the essential oil. It ought, in reference to these cases, to be known that this essence could be had deprived of prussic acid, yet still retaining its flavouring properties.*

Dr. QUAIN, *4th of December*, 1855.

---

6. *Perforating Ulcer of the Stomach.*

S. B. æt. 45, of nervous temperament, spare and delicate habit of body, married, and the mother of three children, suffered since childhood from almost constant dyspepsia. Food, however light, invariably caused pain in the stomach, which was generally more or less relieved by the recumbent posture. Medicines gave but a very temporary relief. Sickness never took place either immediately after food, or at any other time. The bowels were generally constipated, and the menses regular.

On the 8th of September, 1855, she returned from Scarborough and Harrogate, to which places she had been for the benefit of her health. She was met by her husband at the Chesterfield railway station, where she mounted a dog-cart, for the purpose of accompanying him home. About twenty yards from the railway station, whilst passing over a line of rails, the

* "Pharmaceutical Journal," December, 1853.

vehicle gave a sudden jolt, and, at that moment, she felt something give way within. This sensation was instantly followed by excruciating pain in the abdomen, which became more intense every moment, and the patient in two or three minutes, fell, powerless and in the greatest agony, a dead weight upon the shoulder of her husband. A few minutes afterwards she was carried into my dining-room, and laid on her right side upon a sofa. Her countenance was pale, her features were nipped, her eyes wildly staring, and the general expression was indicative of intense suffering. Her skin was deathly cold, the pulse extremely quick, and scarcely perceptible, and a fixed, constant, and rapidly extending pain of the abdomen, bespoke the setting in of peritonitis. This, from the history of the case, the nature and sudden occurrence of the symptoms, was diagnosed to depend on perforation of the stomach, and consequent extravasation. The patient died twenty-seven hours afterwards.

A *post-mortem* examination, made thirty-six hours after death, showed intense peritonitis, particularly on that side (the right) on which the patient had lain—a thick layer of recently exuded lymph on the lower portions of the ileum, sticking the folds of the bowels slightly together—a similar amount of exudation on the cæcum and ascending colon—inflation of the small bowels, and general redness of their peritoneal surface, and effusion into the abdominal cavity of a flaky serum, mingled with the extravasated contents of the stomach. As the latter organ lay *in situ*, a perforation was observed close to the upper curvature and at the anterior surface of the stomach, and situated a short distance from the termination of the œsophagus. It was of a somewhat oval figure, the long diameter being about three-fourths of an inch, whilst its short diameter measured a little more than half an inch. Its internal opening was very slightly larger than the external one, and the margins of the ulcer were as sharply defined as though a piece had been punched out of the stomach. The tissues of the stomach around the ulcer were thickened, particularly at the upper curvature; whilst from the lower margin of the ulcer, the stomach, along the whole circumference of its cir-

cular fibres, was nipped up and contracted, as though a cord had been run round the walls of the organ, and drawn somewhat tightly at this point, thus producing, as it were, a partial division of the viscus into two sacs. Beyond a puckering and corrugation of the mucus lining of the stomach, in the immediate neighbourhood of the perforation, no abnormal condition of that structure was apparent to the naked eye.

Dr. QUAIN for Dr. BLACK, 1*st of January*, 1856.

---

7. *Intussusception of the Cæcum and part of the Ileum into the Colon in an Adult; Death after four months' symptoms.**

T. T. æt. 25, an engraver, tall (six feet two inches) and spare, but accustomed, with some exceptions, to good health. On the 30th of August, 1855, he consulted me, stating that he had been ill for three months, and was, he thought, "in a deep decline." His aspect was very anxious, and his manner a little excited, and I noticed that he seemed to prefer to stand leaning somewhat forward, and resting his hand on the table. He complained of no pain at the time, but said he had suffered much previously, repeatedly assuring me that he was extremely ill, and did not expect to recover. He had expectorated rather freely, but had very slight cough, and had never spat blood. A careful stethoscopic examination detected nothing amiss with either heart or lungs. The pulse was quick and sharp, the tongue furred in the centre, red, and pointed at the tip. His chief symptoms had been loss of appetite and sickness, with attacks of colicy pain in the abdomen. He lost flesh greatly, and for six weeks had been obliged to stay from work. His debility had, however, not been so extreme as to prevent his taking exercise, and he had walked upwards of two miles to my residence. After a somewhat cursory examination, I prescribed for the case as one of gastritic dyspepsia, and desired him to see me

* The subject of this case was seen by me but once before death, and the true nature of his disease was not suspected during life; the particulars respecting several important symptoms are, consequently, not in such full detail as is desirable.—J. H.

again in a few days. During the next ten days I chanced to be out of town, and he several times called upon a medical friend, who was acting for me. This gentleman, after going carefully into the case, was equally at fault with myself as to diagnosis, and saw nothing to induce any suspicion of organic disease.

On the 12th of September, his mother called to say that he had suddenly become much worse, and, on the following day, I heard that he was dead. This was thirteen days from the date of his first application, and nearly four months from what he believed to be the commencement of his illness. In the autopsy, which was performed forty-eight hours after death, I had the assistance of my friend Mr. Buxton Shilleto. The abdomen was distended and tympanitic, and its integuments much discoloured by advancing decomposition. On opening the peritoneal cavity, it was found to contain about two pints of a homogeneous brownish fluid, which, although looking somewhat like intestinal contents, had not the least fæcal odour. No rupture of the bowel could be found, nor did continued pressure on the distended coils cause the air to escape at any part. The peritoneum in all parts was reddened in patches, but there were no adhesions, nor any traces of exudation of lymph. The upper half of the ascending, and first part of the transverse colon, was felt to contain a solid mass, by which it was distended to about the size of an adult's wrist. On further examination, this proved to be an intussusception of the cæcum, of the last six inches of the ileum, and of the first part of the ascending colon into the latter gut. The whole of the appendix cæci had been taken up, its end being just visible at the lower extremity of the invagination. The parts were firm, but nowise tense, and there was not the slightest appearance of approaching gangrene in any portion. The colon above having been laid open, it was found to contain much mucus and coagulated blood, but no fæcal matter. The upper extremity of the intussuscepted gut was open, the opening being, however, concealed by a valvular fold, which proved, on further examination, to be the everted ilio-cæcal valve. At this open-

ing, the finger easily entered and passed down the interior of the gut. The ileum, where it entered the invagination, was just sufficiently grasped to be tightly held, but it was not in any sense strictured, and, after having been opened, the little finger might, without much difficulty, be passed up it. The several layers of bowel involved in the intussusception were found to be firmly adherent to each other by tense and strong bands of false membrane, evidently of old standing. These adhesions existed only where the serous coats were in contact. The mucous membrane was everywhere turgid, and of a purple colour, from long-continued congestion. The cavity of the bowel, which was thoughout pervious, contained clots of blood. The small intestine above the seat of disease was distended with air, and contained also some fæculent matters. No other lesions of importance were discovered in the body.

The real nature of the disease having been now ascertained, a careful inquiry was made of the man's parents as to those symptoms which might have been supposed likely to attend it, and the following facts were ascertained:—His illness had commenced quite gradually about four months ago, the chief symptoms being unusual costiveness of the bowels and irritability of the stomach. A surgeon, for whom he was engaged in some lithographic work, said to him one day that he looked ill, and advised a course of medicine, which was the first he had thought it needful to take. From this time his symptoms increased, he began to vomit after almost all his meals, and rapidly lost flesh. Attacks of severe pain in the abdomen would now occur, the violence of which was often so great, that he would roll on the floor, and for the time lose all control over himself. During these attacks, he would often hang himself by the hands from a ladder in the workshop, and swing his legs backwards, a procedure which sometimes gave marked relief. It was noticed by his friends that, instead of a remarkably upright gait, he had got into the habit of walking with a stoop forwards. Throughout his illness his appetite had been very poor, and he had lived chiefly on biscuit and milk, at

times taking other kinds of food, but generally vomiting soon after. The bowels, from the first costive, always responded more or less to medicine, and latterly became so irritable, that a small dose of salts would produce within an hour or two repeated evacuations, the latter, however, being very scanty, and consisting chiefly of mucus. He had remained at work during most of the illness, but had greatly lost flesh, and had acquired a haggard anxious expression of countenance. It was not known whether or not the stools had ever contained blood.

Mode of death.—On the day preceding death, he had walked out as usual. About five in the afternoon he was suddenly seized by pain in the abdomen, so severe, that he rolled on the floor and declared that "he must now die." After it had lasted about ten minutes, according to custom, he hung himself by the hands to the ladder, but obtained very little relief. About an hour later he walked a quarter of a mile to a house where he usually slept. In the evening he was much worse, and, during the night, sank into collapse, and at times wandered in his mind. In the morning he asked for breakfast, but vomited it again whilst eating. The pain continued to recur at times, and death took place at two P. M., the pulse not having been perceptible at the wrist for six hours previously.

Comments.—From the circumstance that the intussusception was the only lesion found after death, taken in connexion with the fact that symptoms referable to it, *viz.*, constipation, sickness, and paroxysms of pain, had been amongst the earliest to occur, there can be little room for doubt that it was the one original disease, and had existed throughout the time assigned. Should any doubt be felt, the condition of the gut, as to adhesions, &c. ought wholly to dispel it. We have then a case in which, instead of death occurring within a few days, as is usual, the illness was protracted over a period of four months, and the mode of death from gradual exhaustion, rather than from acute disease. The explanation of this must be sought in the fact, that the invaginated tract of bowel in all probability had remained more or less pervious, a circumstance by which also

the extremely ill marked character of the symptoms themselves must be accounted for. The bowel had been kept in the condition of an incarcerated hernia, retained persistently in its unnatural position, but only subject to strangulation at times, when perhaps a little more than usual had slipped up, or there had been an increase from swelling in the thickness of the intestinal coats. Regarded from this point of view, the history of the case, its termination, and the disclosures of the autopsy, tally well together. The patient, at length enfeebled by long-continued impairment of nutrition, sank under an attack of pain similar to those which he had formerly lived through. Nor is even the obscurity which attended the diagnosis difficult to account for. The signs of intestinal obstruction were wanting; indeed, obstruction, in the strict sense of the word, did not exist. The bowels were costive, but they still acted, and the stomach, although irritable, was far from being so intolerant of all ingesta as usually is the case when the intestinal canal has become suddenly occluded. In all probability, a certain amount of the fæcal remains of food had passed through the invaginated tract during the first three months at least of the illness, and the kind of food taken had been that which would afford but very little of refuse. The attacks of pain had not been of a character likely to lead to any definite opinion; they were referred to the hypochondriac region, and might have depended on various causes, more likely to exist than the condition actually present. The mode in which the patient was accustomed to seek relief, by suspending himself by his hands, is well worthy of note, more especially as a similar one is recorded as having been resorted to in a former case of like nature. The position alluded to is one in which not improbably some dragging back of intussuscepted gut might be effected, and thus, supposing that the paroxysm had been caused by the invagination of an additional portion, relief might be obtained. Mr. HUTCHINSON, 16*th of October*, 1855.

---

8. *Internal Strangulation of Small Intestine.*

J. H. æt. 56, a patient in the Somerset County Lunatic Asylum, under the care of Dr. Boyd, was attacked on the 16th of November, 1855, with general febrile symptoms, abdominal pain, and constipated bowels. No external swelling or circumscribed tenderness existed. On the third day of his illness there was vomiting, and the bowels became relieved under the use of injections. The peritoneal inflammation continued, and the patient died on the fifth day, exhausted from vomiting and abdominal pain. No history could be obtained as to the state of his bowels previous to the present illness, the patient being of unsound mind, which was hereditary both on the father and mother's side: he was also exceedingly deaf, a condition which was also supposed to have been transmitted from his parents.

On *post-mortem* examination the day following death, there was general redness of the peritoneum; the intestines were adherent by recent lymph. In the right inguinal fossa, near the entrance of the internal ring, was a very dark nodule of strangulated intestine. On removal and careful examination, the confined portion of intestine was found to be nine inches of ileum, with a portion of mesentery, strangulated by a band of fibres from the lower border of the internal ring; it being conjectured that the intestine, at some considerable period before death, had entered the inguinal canal, and returned into the abdominal cavity, separating in its transit some of the inter-columnar fibres. The strangulated intestine was dark in colour, with the coats of the intestine and mesentery much thickened from long impeded circulation, caused by pressure from the strangulating band.

The internal ears were examined by Mr. Joseph Toynbee, who reports :—

The right ear.—Meatus externus. At the middle of the posterior wall is a small round projection of bone, which narrows the calibre of the tube.

Membrana tympani.—Externally more concave than natural; very vascular and opaque.

Tympanic cavity.—The mucous membrane thicker than

natural: blood-vessels distended. The base of the stapes projects into the cavity of the vestibule further than natural; and it is completely anchylosed to the margin of the fenestra ovalis by a deposit of bone which grows from the outer wall of the vestibule.

Labyrinth.—The vestibule and cochlea contained a sanguineous fluid; and the blood-vessels of the membraneous labyrinth were distended with blood. A considerable quantity of bony deposit filled the scala tympani cochleæ, near to the tympanic circulation, and it completely covered the membrana fenestræ rotundæ, which was apparently converted into bone.

Left ear.—The meatus externus presented an osseous protuberance. The membrana tympani was thick and very vascular.

Tympanic cavity.—The mucous membrane was very thick and vascular; the stapes firmly anchylosed by bone to the fenestra ovalis. The vestibule and cochlea were full of blood and serum. The membrane of the fenestra rotunda ossified.

Mr. Obre, *4th of December*, 1855.

---

9. *Case of Ileus produced by Invagination of a portion of Bowel, which was subsequently discharged by stool. Recovery.*

V. T. æt. 18, of bilio-sanguineous temperament, by trade a quarryman, in strong and robust health, partook of a hearty meal of pork, baked pudding, &c. about half-past twelve on Sunday, 25th of March, 1855. Two hours afterwards he was seized with severe pain in the abdomen, which came on in paroxysms, and which was very shortly accompanied by vomiting. These symptoms continuing and increasing in severity from hour to hour, the attendance of a surgeon was requested the same evening. Medicines were administered with the view of relaxing the bowels, which had not been relieved since the first occurrence of pain. These failed in the desired object. They were repeated from time to time during the three following days: enemata were likewise repeatedly given, but all without effect. The symptoms continued; tenderness of the bowels aggravated by pressure; hot skin, thirst, furred tongue, quick, hard, wiry pulse; and stercoraceous vomiting followed.

He was now leeched, fomented, and subsequently blistered by the medical attendant.

On Thursday, 29th of March, I saw him for the first time. There were present symptoms of general peritonitis accompanying those of ileus. The abdomen was tumid, extremely tender to the touch, particularly in the neighbourhood of the ileo-cæcal valve; the vomitings were frequent, of a dirty mustard colour, highly stercoraceous in their odour, and were followed by hiccough, which continued for some time; the tongue and fauces were red and dry; there was intense thirst, together with hot and dry skin; quick, small, and somewhat hard pulse; and scanty high-coloured urine. The bowels had not as yet been relieved in the natural way.

The treatment now pursued had for its object the subduction of the existing inflammation; and with this view effervescent salines, conjoined wlth hydrocyanic acid, and calomel and opium were exhibited internally at intervals of two hours; whilst local depletion by leeches, followed by *constant* anodyne fomentations, and these ultimately succeeded by a repetition of the blistering which the patient had undergone in a previous stage, were practised externally.

During the four following days, the more urgent symptoms gradually subsided: and from the ninth day of attack the vomiting entirely ceased, and the abdomen was much less tender to the touch. A careful examination could detect no tumor or isolated swelling in any portion of it; but when one hand was placed between the umbilicus and pubes, and a repeated vibratory motion was suddenly communicated by the other to the abdominal walls and subjacent viscera in the right inguinal region, distinct succussion was both felt and heard. In no other part of the abdomen could this sensation be produced. Here, then, seemed to be the seat of obstruction.

All the symptoms had greatly improved; the gums were tender, but no evacuation from the bowels had as yet taken place.

During the tenth and two following days, occasional warm-water enemeta were thrown into the lower bowel, some of which, after being retained for a short time, were returned

without any admixture of fæcal matter; whilst those administered on the twelfth day of the attack, brought away more or less of fæculent discharge. The disposition to evacuate thus manifested by the bowels was at once followed by the exhibition of a dose of castor oil by the mouth, and by further warm water enemeta, after the lapse of two or three hours from the taking of the oil. These means produced several scanty, but decidely fæculent evacuations, which were repeated daily, and in somewhat increased quantity, until the nineteenth day. At this time the patient, at intervals of several hours, had three evacuations, the last of which only I saw. This consisted of blood of a bright florid colour, from a pint to a pint and a half in quantity, and mingled with many pieces of what, on examination, proved to be portions of the small bowels, one of the largest of which is that laid before the Society. The patient's mother told me that the two previous evacuations were of precisely the same character as that which I saw, and that they both contained many "skins," a term by which she designated the portions of intestine discharged.

The loss of blood sustained by the patient had rendered him pale and faint; besides which, there was considerable soreness in the right iliac region. The recumbent posture, opiates, and, as there was now a disposition to purge, mild astringents were adopted. A starch injection, with laudanum, was given at bedtime for a few nights; whilst the diet, which had hitherto consisted of milk, gruel, and the different farinaceous foods, was continued. Under this treatment convalescence was established at the close of the sixth week; and, in a fortnight afterwards, the patient returned to his usual employment.

Remarks.—The above case is interesting in the following particulars:—

I. The nature and seat of the obstruction.

II. The mode in which the obstruction was produced.

III. The effect of the treatment adopted.

As to the nature and seat of the obstruction, the discharge of portions of bowel on the nineteenth day clearly showed that the obstruction depended on invagination; whilst an exami-

nation of the discharged portions of bowel, taken in conjunction with the predominance of pain in the right inguinal region, particularly after the subsidence of peritonitis and the separation and dejection of the invaginated intestine, coupled with the fact that succussion could only be produced over the site of the lower portion of the ileum, leaves little or no doubt that the seat of obstruction was in the immediate neighbourhood of the ileo-cæcal valve. Let it, then, be admitted that the obstruction occurred at this point. The next important query involves the mode in which the invagination took place. In seeking to solve this question the evidence must be of a *negative*, rather than of a *positive* character. In pursuing this method of proof, it will be necessary to show what are the conditions in a bowel which allow the invagination of one portion within another, and whether or not these conditions apply to the case in question.

For the occurrence of invagination in a bowel like the ileum, it seems to be requisite that there shall be *paralysis* of one portion of it, with at least normal peristaltic action of that portion immediately above the paralysed part. These conditions fulfilled, the propulsive action of the upper portion is suddenly arrested at the junction of the latter with the paralysed part of the tube, which, offering but a passive resistance to the downward action of the upper part, whose contractions necessarily draw it nearer to the axis of the tube, easily yields, and allows the upper portion to pass within it, and thus to constitute an invagination.

Paralysis, then, being one essential condition of such iliac invagination, how is it produced? In one of three ways, namely:—

I. By a *simple* loss of innervation in some portion of the tube.

II. By a matting together of its muscular fibres from inflammatory exudation, and by the consequent abolition of their contractile power.

III. By mechanical distension from within, owing to the presence of alvine concretions, &c.; or by such an amount of pressure externally to the gut, that the peristaltic action of the

latter remains more or less abolished, even after the removal of the exciting cause.

That there was paralysis of any portion of the ileum from simple loss of innervation, is opposed by the fact that, up to the moment of attack, the patient was in robust and perfect health; and that all the functions of the body had hitherto been performed in their natural way.

That a matting together of the muscular fibres of any portion of the ileum from inflammatory exudation, and consequent abolition of contractile power, was the cause of invagination, is negatived by the above argument, and by the absence of all inflammatory symptoms until some time after those indicative of intestinal obstruction had taken place.

That mechanical distension from within, owing to the presence of alvine concretions, was the cause of temporary paralysis of a portion of the muscular coat of the ileum, which thus permitted invagination to take place, appears to be disproved by the regular and daily evacuation of the bowels up to, and even on, the morning of the day of attack; by the natural appearance of the evacuations during this time and by their character when the bowels were again moved after the nineteenth day, which character was manifested by the liquidity of the evacuations, and by their freedom from scybala.

That pressure externally to the bowel had paralysed a portion of its muscular coat, and thus induced a condition favourable to invagination, is opposed by the argument first used, and by the fact, that neither effusion into the peritoneal cavity nor any morbid growth therein preceded the occurrence of iliac symptoms. From what causes, then, did the invagination take place?

In attempting an answer to this question, attention must be directed to the relative position of the ileum and colon, and to the direction of the intestinal force in the onward propulsion of the contents of these bowels. It will thus be observed that the lowest portion of the ileum, at its junction with the colon, forms with the latter a considerable angle; and that the propulsive force of the ileum is consequently exerted in a direction transversely, or nearly so, to that of the colon. At the ileo-

cæcal valve, therefore, the propulsive action of the ileum is abruptly arrested, whilst that of the colon is, as yet, entirely passive.

The tendency of this active iliac force transversely to the axis of the passive colon is to protrude the former into the tube of the latter; but, in the ordinary action of the ileum this occurrence is prevented by the resistance of the ileo-cæcal valve. When, however, an undue motor action is excited in the muscular coat of the ileum, the ileo-cæcal valve may be overpowered, and the resistance to the active force of the former being thus removed, the successive contractions of the ileum from above downwards would protrude the latter into the tube of the colon. This I conceive to be the mode in which the invagination in the above case took place; the robust health of the patient, by imparting a vigorous tone to the muscular coat of the bowels, the copious meal taken but a short time before the setting in of iliac symptoms, probably half masticated, and, consequently, but imperfectly digested, by exerting an unusual degree of contraction of the muscular coat of the ileum, would act respectively as predisposing and exciting causes. On this view the effect of the treatment is easily explained. It is clear that the purgatives administered at the very outset of the attack, by increasing the peristaltic action of the ileum, would tend to the further protrusion of that bowel into the passive and unresisting colon; and that they could not, therefore, attain the object for which they were given. It ought, then, in my opinion, to be received as an *axiom* in physic, that where invagination is *suspected*, purgatives *ought not* at first to be used. With a less degree of confidence emetics may be recommended, for the inverted peristaltic action thereby produced, *might* have the effect of liberating the invaginated portion of bowel. To this end, also, a copious bleeding from the arm, by arresting the undue contractions of the ileum, by probably relieving, to some extent, the vascular engorgement of the invaginated portion of bowel, and by favouring the action of the emetics would contribute; whilst the frequent use of copious enemeta, by exciting the action of the colon, would exert, if any, a favourable influence on the obstruction. These

are the means which, at the very outset of the above case, would, in my opinion, have been justified by the pathological cause of obstruction; but when to invagination inflammation was added, and when, in consequence, recovery could only be hoped for by controlling that inflammation, and by waiting, as it were, on nature, the treatment which was then pursued, as it seemed to be the only one sanctioned by theory, was also justified by its perfect success in the recovery of the patient.

Dr. QUAIN for Dr. BLACK, *5th of February*, 1856.

---

10. *Fatal Intestinal Obstruction in consequence of a Twist in the Mesentery, and the falling of some folds of Intestine over a true Diverticulum.*

In December, 1855, a baker boy, of a strong robust constitution, was seized early in the morning, after taking a hot cup of coffee, with violent pain in the stomach, followed by sickness. About nine hours after the attack he was seen by Mr. Beale and Mr. Williams, of Plaistow, who found that the boy's bowels had been relieved two days before, that his pulse was one hundred and twenty, his tongue slightly furred, countenance anxious, with pain on the right side of the abdomen. These symptoms, together with complete constipation, continued, varied in intensity, until the sixth day, when those of general peritonitis set in, and carried the patient off on the ninth day from the attack. On an inspection, conducted forty-eight hours after death, the peritoneum was found to exhibit the results of inflammation, the intestines being matted together, and connected with the abdominal walls. The duodenum, jejunum, and ileum, were greatly distended, the lower portion of the small intestine having been highly inflamed, and about two loops of it being quite black from congestion. The mesentery in connection with these loops had been twisted on itself, and caused their strangulation; and while in this state, the folds had fallen over an intestinal diverticulum proceeding from the small gut to the linea alba, about one inch below the umbilicus, thus giving rise to an additional amount of mechanical obstruction to the circulation.

This diverticulum was five inches long, and thirty-four inches distant from the cæcum.

Mr. NATHANIEL WARD, 18*th of March*, 1856.

---

11. *Stricture of the Sigmoid Flexure of the Colon, with Perforating Ulcer, fatal five weeks after labour.*

H. H. a female, æt. 32, was first seen on Saturday, the 9th of June, 1855. She was complaining of acute rheumatism in the left hand, which was swollen, red, and tender. She had been confined about three weeks previously, the labour was protracted, but the child was living and healthy. The lochiæ were arrested a few days after confinement, only a thin white discharge remaining.

The bowels had not been relieved since the previous Tuesday, and then only after taking several large doses of castor-oil. She had suffered from constipation for years, and had been confessedly careless about the regular action of her bowels. Ten years previously she had an attack of enteritis, and at different periods since had experienced slight abdominal pains, short in duration, and not confined to any particular spot. Once (some three years previously), whilst turning suddenly in bed, she experienced a sensation in the bowels as of something giving way, followed by slight pain, which, however, soon left her. She had never seen any blood in her stools, except what came from piles, to which she had been for some time subject. She had never suffered from diarrhœa.

When first seen the tongue was clean, and of a deep red colour; her pulse quiet; there was no sickness, and but little appetite. She suffered severely from pain in the hand, to which she attributed her sleeplessness at night. There was slight abdominal tenderness, not restricted to any one spot. Ordered a saline aperient, with colchicum, and an enema, if necessary, on the following morning.

Sunday, 10*th*.—She slept little during the night. Expression anxious. Had several times vomited a clear fluid, and still felt very sick. The tenderness of the bowels greatly increased, very slight pressure being unendurable; this tenderness was espe-

cially marked in the epigastric and left hypochondriac regions: pain in the hand abated. Injection brought away several yellowish-white masses, moulded to the form of the bowel, and resembling mortar in appearance and consistence, but with no appearance of true fæcal matter. Tongue red (like raw meat) and rather dry. Pulse one hundred and twenty, and full. Urine passed without difficulty. Effervescing medicine ordered, with calomel and opium, and a blister over the abdomen.

Monday, 11*th*.—Slept somewhat during the night. Abdominal tenderness greatly diminished, and pain relieved since the blister rose. Tongue moister. No vomiting. Pulse one hundred. Injections to be repeated, a quart each time.

Tuesday, 12*th*.—Slept well during the night, without any sickness. Tenderness of hand diminished. Slight abdominal tenderness on strong pressure, and occasional pain in the bowels. Pulse quiet. Tongue very red, but moist.

Vespere.—Vomited once this evening; ejected matter of a yellow colour, with brown, flocculent sediment, and an unmistakably stercoraceous odour. Pulse one hundred, soft, and rather full—no action of the bowels. The propriety of performing Amussat's operation was debated in consultation. The indistinct localization of the symptoms, and the circumstances of the patient being considered, it was not deemed advisable; there being, moreover, strong objections on the part of the family. A large injection was administered (upwards of three pints), and *retained about twenty-five minutes*.* No fæces came away with it, but on the surface there floated an irregularly-shaped mass of organised lymph, about the size of a pigeon's egg, and much resembling one of the white clots sometimes found in the heart. Calomel and opium ordered.

Wednesday, 13*th*.—Slept tolerably well during the night, but wandered a little on waking. Injection repeated without any result. Occasional pain in the bowels, chiefly referred to umbilical region. Great tenderness on pressure in epigastric region: abdomen very much distended with flatus. No sick-

* As the *post-mortem* examination proved that none of this could have passed above the stricture, room for this large quantity of fluid must have been made by the dilatation of the rectum.

ness; frequent eructations had occurred, but without affording much relief. Turpentine stupes were applied.

Thursday, 14*th*.—Slept well during the night. Pain in the bowels diminished. Tenderness very slight, even on severe pressure. Face sunken, and skin assuming a dingy muddy hue. Injections twice repeated, had each time brought away small lumps of fæcal matter the size of peas. Pulse weaker, tongue dry and red, with great thirst.

Friday, 15*th*.—No pain, no sickness. Injections brought away similar pea-shaped pieces of fæcal matter. Pulse moderate. Wine given freely, and opium in increased doses.

16*th*, 17*th*, 18*th*.—No change, except that she gradually became weaker, and the bowels became enormously distended with flatus. Slight tenderness felt chiefly in the umbilical and right lumbar regions, but no complaint of persistent pain. Vomiting occurred several times, but not of stercoraceous character. No action of the bowels, further than a continuance of the small fæcal lumps in the injections. Face thin and yellow: tongue dry and cracked. The wine taken readily.

Tuesday, 19*th*.—Much weaker. The form and size of the distended intestines plainly perceptible through the abdominal walls. Injection brought away some larger pieces of fæcal substance, about the size of shillings.

Wednesday, 20*th*.—Pulse very weak; no pain; but the sense of distension greatly complained of.

Thursday, 21*st*.—Extremities cold; pulse hardly perceptible. Very collected, but drowsy. No pain, but complainings of a sense of coldness in the bowels. Died about midnight.

Autopsy eighteen hours after death.—The body, which was comparatively small, was not much emaciated; the rigor mortis was present. The abdomen was enormously distended into a conical form, and measured twelve inches and five-eighths from its apex to the horizontal plane, upon which the body lay, the height of the chest from the plane being eight inches and seven-eighths. It was slightly discoloured at its upper surface, and on percussion sounded tympanitic. On opening the abdominal cavity, the entire mass of intestines was found distended with flatus, the larger bowels more so than the former. The cæcum was

so greatly distended as almost entirely to obliterate the folds of the intestine, and was large enough to contain an object twice the size of a full-grown fœtal head. On carefully tracing the bowels from the stomach (which was of normal appearance and not distended) nothing was found to account for the obstruction during life, till reaching the sigmoid portion of the colon, when the central part of that flexure was found to be constricted, with the walls much thickened and indurated. At the lower margin of this stricture an ulcerated opening was present, of the size of a sixpence, through which some ounces of fluid fæculent matter had escaped into the peritoneal sac. On removing this part of the diseased bowel, and carefully examining it, the obstruction was found to be so complete, as only to admit a body as large as an ordinary lead pencil to pass through it. Above the stricture, on slitting up the bowel, there was found some semi-solid, greyish-white fæculent matter, with a tinge of slate-colour, and which appeared completely to obstruct the passage downwards, acting, in some respects, the part of a wedge. This substance was not found in any other part of the canal, and was examined with care for magnesia, but it contained none. The mucous membrane of the stricture was in a state of ulceration, with an irregular jagged surface, and from the induration present (due to the effusion of lymph into the submucous cellular tissue and muscular coat of the bowel) it appeared probable that the stricture had existed for many months. There were traces of inflammation around the perforating ulcer, whose edges were ragged, and the surrounding part of the bowel was very soft and easily torn, this ulcer was of recent occurrence. Lines and stripes of inflammatory redness existed along the free margin of the small intestine, throughout the greater part of its length. All the remaining viscera were perfectly healthy; the uterus had contracted to its natural dimensions. The head and chest were not examined.

The flatus in the intestines probably accounted for the little tenderness during life, as the distended bowel would act like an air-pad to ward off direct pressure.

Dr. GIBB for Dr. H. G. WRIGHT, *29th of November*, 1855.

12. *Perforation of Cœcal Appendix from an Intestinal Concretion.*

J. H. æt. 36, was admitted into Guy's Hospital under Dr. Barlow's care, on the 10th of August, 1855. He was then suffering from acute peritonitis, and was too ill to give any detailed account of his symptoms. It was learned, however, that previously being in good health, he was seized six days before with pain in the right side of the abdomen, and that the inflammation extended itself until it had reached the stage in which he was found on admission. He died in a few hours, and a *post-mortem* examination took place.

The body was that of a fine strong muscular man. Acute general peritonitis, with much effusion of lymph, existed. Upon examining the cæcal region, the root of the appendix was found ulcerated, and protruding through it was a hard brown substance, and lying beside it loose in the abdomen was a smaller body of the same description. The one fixed at the entrance of the vermiform process, was about the size of a bean, and much distended the appendix in the part where it lay. The mucous membrane was ulcerated, and the wall at one side, where the concretion was endeavouring to free itself, was destroyed. The other concretion, which had entirely escaped, was only half the size. At first sight these appeared to be gall-stones, but a closer examination proved them to be true intestinal concretions. The larger one, when a section was made, was seen to be composed of concentric layers: the internal being of a whitish colour, and the external brownish. The former occupied the great bulk of the concretion, which was thus white, tolerably firm, and presented no crystalline or peculiar arrangement beyond that of the concentric coatings. Surrounding this was a brown irregular covering, composed of two or three layers of the same material mixed with fæcal matter. The stone was easily broken, the external part being the more friable; the powder to the naked eye and the microscope, presented nothing more than amorphous granular matter. On chemical analysis, I found it to consist of earthy phosphates, and, on submitting it to Dr. Odling for further trial,

he informed me that "the concretion consisted principally of phosphate of lime, but contained very evident quantities of triple phosphate."

The case is an example of a by no means uncommon disease, which is included in the subject of inflammation of the cæcum and appendix, or typhlitis, as it has been called; and the intestinal concretion also affords an example of what I believe to be generally the cause of the complaint. There is no doubt that foreign bodies do occasionally fall into the vermiform process, and there set up an ulcerative disease; but, judging from my own experience, I incline to the belief that typhlitis is by no means so often due to the presence of external bodies, as it is a disease originating in the part itself. I judge so from the fact, that in several cases of which I have witnessed the inspection, similar concretions to the present have been found, and that the discovery of foreign bodies has been the exception; indeed, on more than one occasion, instances which have, from superficial observation, been styled date-stones and cherry-stones, have, on further investigation, proved to be concretions: the most common of which, perhaps, is a peculiar waxy-looking substance filling the end of the cæcal appendix, and resembling very much in outward appearance a date-stone. Such substances are, no doubt, secreted by the appendix itself, but whether the earthy concretions, as in the present instance, are formed in the same place, or whether they are produced in other parts of the intestinal canal, and afterwards fall into the vermiform process, requires some further research to discover, but I incline to the former opinion. Dr. WILKS, 18*th of December*, 1855.

---

13. *Tuphlo-enteritis from Hardened Fæces in the Appendix Vermiformis.*

A healthy boy, æt. 12, was seized with symptoms of obstruction and inflammation of the bowels a week after receiving a kick in the right side. He died in eight days. The symptoms were pain and swelling in the iliac region, constipation, and constant vomiting, latterly stercoraceous.

Examination made five days post-mortem.—The intestines were inflamed, and matted together with recent lymph. Some purulent effusion also existed. On removing the cæcum, the appendix was torn, giving exit to a small lenticular mass of fæces, soft outside, hard within, the size of a pea, consisting of concentric layers, which lay about an inch from the orifice, at which point the appendix was inflamed, dilated, and softened. The rest of the mucous membrane of the intestines was healthy; but at the cæcal valve there was a small pedunculated submucous tumor in the ileum.

In this case two questions arise. Did the kick excite the disease? If so, was it by impelling the fæces into the appendix which caused the consequent inflammation? or did it only excite inflammation in the appendix around the fæces previously lodged there?

Dr. Ogier Ward, *4th of December*, 1855.

---

14. *Villous Disease of the Colon.*

G. W. a foreman tailor, died in the Middlesex Hospital on the 20th of February, 1855. He had been a man of regular and sober habits; and up to the 2nd of September, 1854, had generally enjoyed good health. Previously to this date his bowels acted with regularity, and he had not observed anything unnatural in his motions. On the morning of the 2nd of September, he was seized with purging, vomiting, and cramps, and was admitted, under Dr. Hawkins, the same evening, in a state of complete collapse. The purging was profuse; the motions presented the usual character of cholera evacuations, but in addition contained a considerable quantity of blood. He soon rallied from the collapse, and fever of a mild type supervened, during which diarrhœa and occasional vomiting continued. As the fever passed off he was left in a state of extreme debility and depression, a circumstance which was, no doubt, partly owing to mental causes, as he lost his wife in the same epidemic of cholera.

Although the bowels still continued in a disordered state, and the motions frequently contained blood, he recovered

sufficient strength to go to the Walton Hospital on the 6th of October. He, however, returned on the 1st of November; the same symptoms persisting. After this the emaciation increased, and extreme pallor of the skid was noticed. The bowels were generally purged; the motions sometimes contained solid matter, but were almost invariably mixed with blood. Sickness became almost constant, the tenderness great. He gradually sank and died six months after his first seizure with cholera.

During the attack of cholera he was treated with calomel, salines, and stimulants. Subsequently various astringents were employed, such as krameria, catechu, copper, &c.; but these remedies appeared to possess little power either in controlling the diarrhœa, or in checking the hæmorrhage.

Post-mortem examination made twenty hours after death.—Body extremely emaciated, but not perfectly devoid of fat. The whole extent of the colon, from the ilio-cæcal valve to near the anus, is affected with villous growth. The disease is more developed in the portion near the ileum, than in that near the anus. In the former situation the growths form an almost complete covering to the membrane, whilst in the latter there are many irregular patches in which the mucous membrane is in a healthy condition. These villous growths are all of small size, none being as much as half an inch in length, the majority scarcely an eighth. They are composed of a number of villi of various sizes and forms, irregularly grouped together, and covered by a membrane continuous with that lining the intestine. The small intestines are quite healthy, but they contain a large "tænia solium." The liver is large, pale, and rather fatty. All the other viscera are free from disease.

Since exhibiting a specimen of villous disease of the bladder to the Society,* I have had the opportunity of comparing the structure of these growths with that of the healthy chorion, and I find that beneath the microscope the resemblance is as striking as it is to the naked eye. The specimen, also, of fungus tumor of the bladder exhibited by Mr. Shaw on a former occasion,† on careful examination, proves to be an example of the

* *See* a history of this case on a subsequent page.

† *See* "Transactions," vol. v. p. 200.

same disease. In this latter case there was a pendulous villous growth hanging from the side of the bladder; and, in addition to this, half the mucous surface of the bladder was covered with small villi.

The microscopical appearances of the growths in the colon (Plate X. Fig. 1.) of the tumors in the bladder just referred to (Fig. 2.), and of the chorion (Fig. 3.), are so closely similar, that, with some slight modifications, the same description applies to all. The chorion, which is the subject of this description, was taken from a uterus at about the tenth week of pregnancy. The villous growth in the colon, and Mr. Shaw's tumor of the bladder, had been kept some months in spirit before the examination was made.

If a portion of the growth be examined beneath a low power of the microscope, the villi will be seen branching out from the central mass, without any regularity or uniformity of arrangement. Smaller villi will be seen sprouting out from the sides of the larger; and from these, again, still smaller villi arise. The forms of the villi are extremely variable, some being thick and short, others long and club-shaped; others, again, thin and almost filamentous. Some of the latter are as much as $\frac{1}{20}$th of an inch in length, and $\frac{1}{400}$th in diameter.

When examined beneath a higher power, each villus is seen to be composed of a fine membranous envelope like the finger of a glove, enclosing a quantity of granular matter, in which numerous cells are embedded. In some parts these cells are so closely packed together, that the villi appear to be entirely built up of them; whilst in other places cells are seen sparingly scattered amongst the granular substance.

The cells are chiefly spheroidal in form, and cannot be distinguished from those of the membrane adjacent to the villous growth. They are about the size of the white corpuscles of blood, slightly granular, and contain one or two nuclei. In the stems of some of the longer villi the cells are more elongated, and some approach in character the plastic cells of lymph.

On tearing a portion of the growth with a needle, numerous fibrils are seen; in the more delicate villi these closely resemble the fibrils of coagulated fibrin; but in the larger and more solid

DESCRIPTION OF PLATE X.

Figures 1 to 3 illustrate Mr. Sibley's observations on Villous Disease of the Colon, p. 212.

Fig. 1. Represents some of the villi from the colon. Magnified 200 diameters.

Fig. 2. Some of the villi from Mr. Shaw's case of villous growth in the bladder. Magnified 200 diameters.

Fig. 3. Villi of the chorion. Magnified 90 diameters.

Fig. 4. Diagrams to show the mode in which the villi are supposed to be formed.

Figures 5 to 8 illustrate Dr. Bristowe's and Mr. Sydney Jones's report on Fibroid Deposit in the Heart in a case of Dr. Bence Jones's, at p. 167, and on a similar deposit around the Scapula, p. 346.

Fig. 5. Section of the growth over the scapula in Mr. Sydney Jones's specimen.

Fig. 6. Varieties of cells and nuclei from the same.

Fig. 7. Section from heart exhibited by Dr. Bence Jones.

Fig. 8. Varieties of cells and nuclei from the same. These are all magnified 420 diameters.

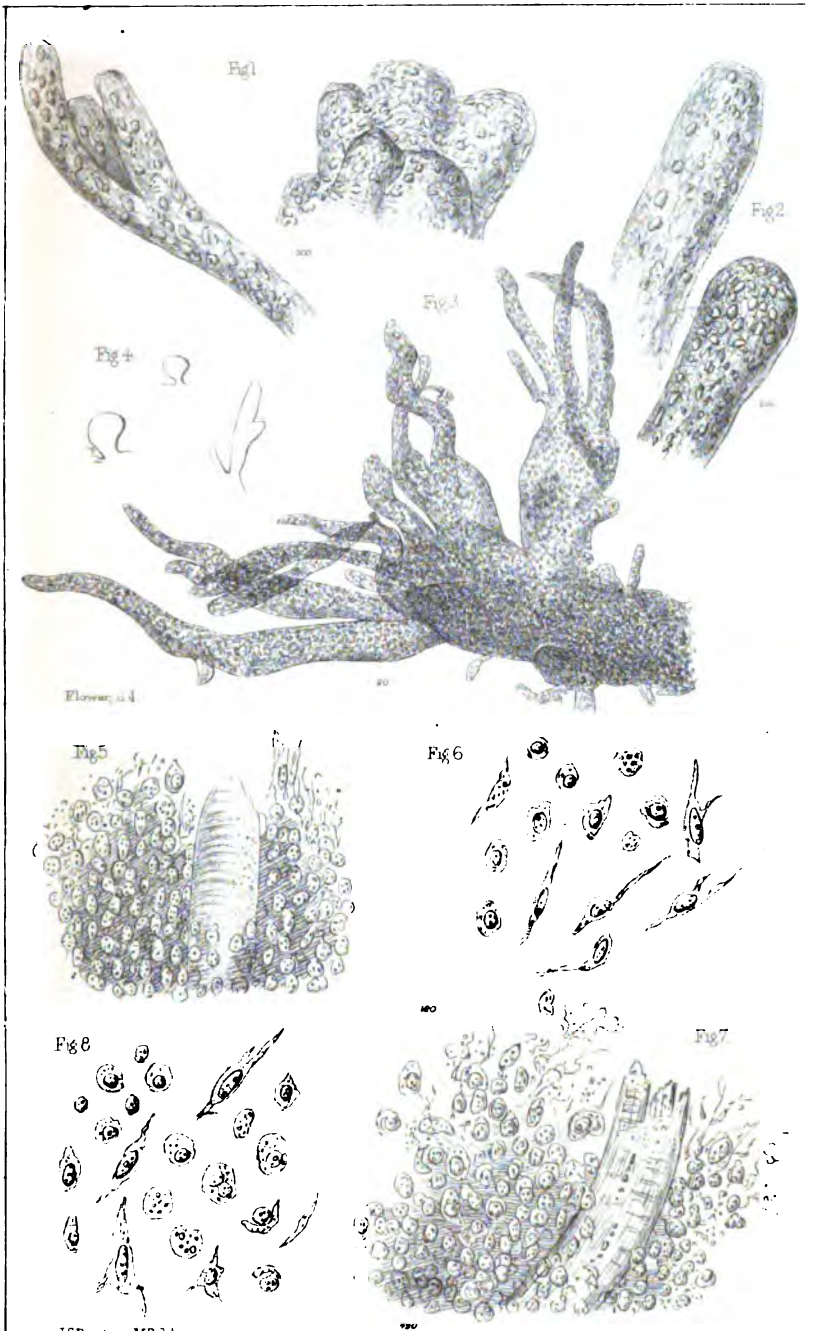

Tuffen West, lith

W West, Imp

portions they assume the character of ordinary connective tissue, enormous numbers of nuclei being associated with them. Vessels are observed in all except the smallest villi. In some there is a simple loop of a capillary, but in the larger villi there is a more or less complicated net-work of vessels.

The mode in which these villi are developed is remarkable. The younger villi sprout out from the older ones in a manner very similar to that in which a young hydra grows from the side of its parent. The enveloping membrane of the parent villus becomes bulged: the bulging gradually increases, till an excrescence in the shape of villus is produced. The cells appear to be formed subsequently, few being seen in the younger villi. So, also, the vessels are probably not developed till the villus attains some magnitude. The areolar tissue of the larger villi is, no doubt, partly a fresh development, and is partly formed by the dragging of the adjacent tissues into the new growth.

As to the differences of structure among these various examples of villous growth, that in the colon is characterised by the shortness of the villi, by their being frequently club-shaped, and by the absence of great vascularity. In the cases in which the bladder was affected, the villi, both in form and vascularity, more closely resembled those of the chorion. Many of the villi (especially those in the bladder) exhibit the appearance that is described as "fatty degeneration" in the chorion.*

It will be sufficient here to call attention to this curious homology between a diseased and a natural tissue, without entering into speculations as to what possible similarity of circumstances might subsist between this growth and the chorion that could lead to so singular a resemblance in structure.

Although Andral, and I believe most of the older pathologists, considered villous disease as a simple growth, most recent writers regard it as a species of cancer, particularly Rokitansky, who describes it as possessing the structure and characters of malignant disease. The description which has here been given, of course tends to prove its non-malignant nature.

Mr. SIBLEY, *6th of May*, 1856.

* Wedl, "Pathological Histology."

15. *Unique Congenital Malformation, associated with Umbilical Hernia and a Pendulous Artificial Anus.*

On the 21st of August, 1855, I was requested by Mrs. B., an intelligent midwife, to see an infant at whose birth she had assisted a few hours before, and who possessed a remarkable malformation. The mother, a healthy and well-formed woman in every respect, had borne many healthy children, most of whom are living. The infant was small, but healthy-looking, it might have been the size of between a seven and eight months child, but had been born at its full period of time, and nothing unusual had occurred at its birth.

Projecting from the umbilical opening was a portion of the funis, the upper and anterior part of which was dilated into the form of a sac, which consisted of a fold of peritoneum, quite thin and transparent, and through which could be distinctly seen several folds of small intestine. Attached to the left side of this sac, was a blood-red triangular shaped mass, with a villous surface, like injected mucous membrane, terminating in two conical projections, with an opening at the end of each. This hung like a small bag partially filled with gas, which could be squeezed out on pressure, the contents passing into the transparent tumor, the bowels inside of which could be returned to the abdomen, with the exception of a couple of folds, which were evidently in connexion with the blood-red tumor itself. Behind the peritoneal protrusion the cord passed downwards. These parts are represented in the drawing made six hours after birth (Plate XI.). The organs of generation were natural; the root of the penis was three-quarters of an inch below the lower margin of the navel, the testes were in the scrotum, and the bladder I saw emptied in a full stream, and with much force. From the two conical bodies meconium was frequently passing in small quantities at a time, and on passing a probe into the anus it ascended an inch only, leading to the suspicion of deficiency, which was strengthened by fæculent matter passing from the spots just mentioned; but on the 24th, three days after, copious motions from the rectum took place, thus showing that the channel was clear, very little,

DESCRIPTION OF PLATE XI.

The figure illustrates Dr. Gibb's case of Congenital Malformation, associated with Umbilical Hernia and a Pendulous Artificial Anus, p. 216.

a a. Umbilical cord.

b. Sac of peritoneum, containing intestine.

c. Inversion of the vermiform process.

d. Inversion of portion of the ileum.

e. Inversion of the cæcum.

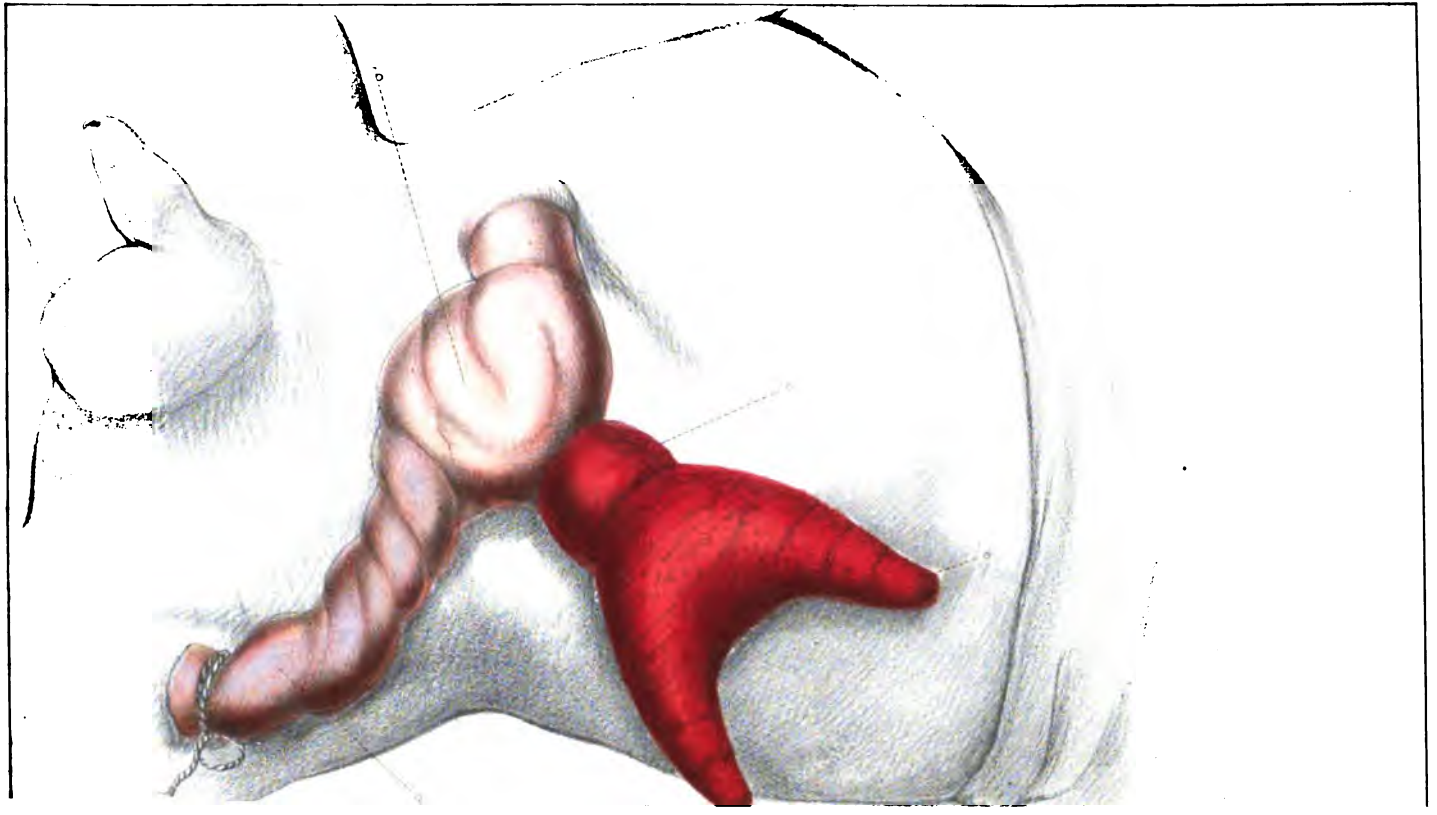

however, passed during the remaining few days of life. The child did not at any time take the breast, the milk of which was squeezed into its mouth; it thus got into a very weak condition, and suffered much apparently from pain in the tumor and round about the navel. On the 24th, bleeding occurred from the conical bodies of the tumor, which continued daily, and less fæcal matter passed than at first; from one of these bodies a watery fluid oozed out. On the 30th, the tumor appeared shrunk to some extent, the peritoneal sac had lost its transparency, and was becoming quite hard and rough; the navel was drying up, and the blood-red tumor was more of a dark crimson, and somewhat retracted. A very thin watery fluid passed frequently from the anus, the skin was quite yellow, the body much emaciated from inability to take food, which seemed to depend in some measure upon an immobility of the lower jaw, and it died in the evening about eight o'clock, having lived nine days.

Autopsy twelve hours after death.—The body was very diminutive, the size of a small seven months' child; it measured seventeen inches in length. Rigor mortis complete, the surface of the body generally congested and mottled, the skin of a yellowish-pink colour; that of the face was a distinct yellow, and the expression of the countenance indicative of pain; the abdomen was slightly distended, but the body and limbs were emaciated. From the umbilical opening protruded a hard mass, containing intestine, terminating in the inverted portion of bowel, which was now a dark maroon colour, and, together with the tumor above it, much shrivelled. On passing a probe into the right conical prolongation, it entered the abdominal cavity; this could not be effected in the left.

Abdomen.—The intestines were much congested; on lifting them up to examine the large bowel, it was found pursuing its usual course, maintaining the sigmoid flexure in the ordinary position; but its calibre did not exceed in size that of the ordinary ascaris lumbricoides, as well as being the same colour; it looked like a continuous round white worm, extending from the anus, and terminating within the hernial tumor, which is shown in the drawing taken after birth. This was most clearly

ascertained to be the colon and rectum. The stomach was tied at its cardiac orifice, and, together with the mass of intestines, and the umbilical tumor, removed; the mesentery was carefully detached, and the intestines isolated, when it was found that the portion of bowel corresponding to the lower portion of the ileum, together with the cæcum and its appendage, formed the hernial protrusion; the larger intestine, from the anus to the umbilicus, measured nineteen inches, and the small intestine, from the pyloric orifice of the stomach to the umbilicus, measured fifty-six inches. The probe was again passed into the right conical prolongation, and immediately entered the small intestine. There was thus a distinct communication, which constituted an artificial anus. The instrument did not enter into the other more than three-quarters of an inch. The round ligament of the liver, which is shown in the preparation, passed out of the umbilicus with the hernia, and the urachus and umbilical ligaments of the bladder; these were impervious, and were filled with a firm, hard, and continuous cord-like clot. The other viscera were healthy, the liver being small, if anything, and rather soft; its structure was chemically examined, and contained an abundance of sugar. The stomach was partly filled with a tenacious mucus of a drab and brown colour, which gave an intensely acid reaction, and contained sugar, this was partly accounted for by the presence of milk-globules, as shown by the microscope.

Thorax.—The viscera were healthy, the pericardium was partly dry on its surface, and quite transparent, permitting the heart to be seen within it; the heart was filled with coagulated blood in all its cavities; the foramen ovale was nearly closed. The lobes of the lungs were slightly adherent, but not from inflammation.

Head not examined.

Remarks.—A large number of remarkable deformities have been recorded, but the present appears almost unique; and, although the interior of this strange tumor has not been dissected, I believe the blood-red tumor to be nothing else than an inversion of the cæcum—the right conical body being a part of the ileum inverted, and the left the vermiform process. The

large intestine has most probably become partially obliterated, and, in consequence dwindled into an insignificant tube, which would have become perhaps wholly obliterated in the course of time, had the child lived. This malformation I conceive to have existed from the earliest period of closure of the abdominal walls during the obliteration of the omphalo-mesenteric vessels. Dr. GIBB, *20th of November*, 1855.

---

16. *Specimen of Strangulated Femoral Hernia.*

A female, æt. 53, suffered from vomiting, umbilical pain, and constipation of the bowels for four days, and died without receiving medical advice. At the *post-mortem*, a portion of intestine, the size of a small egg, was found *perfectly strangulated* in the left femoral ring. The strangulated portion was intensely blue, but the structure of the gut was unaltered: an old omental hernia also occupied the sac.

This specimen illustrates that sloughing, or perforation of an intestine, are not necessary to cause death in unrelieved strangulated hernia. The small intestines in this case were preternaturally red, but not inflamed.

Mr. H. OBRE, *6th of November*, 1855.

---

17. *Omental Crural Hernia, spontaneously cured by Adhesion of the Omentum around the Neck of the Sac. From a Female.*

The sac is remarkable for a central hour-glass constriction, apparently produced by the passage of the ilio-inguinal nerve and superficial epigastric vessels across it superficially. The long diameter of the tumor lies in the direction of Poupart's ligament. The outer end was most prominent during life, the inner being obscured by the adipose tissue of the pudendum. The interior is separated into two smooth irregular cavities by adherent false membrane, and contains omentum only. It has the usual coverings. Mr. JOHN WOOD, *20th of February*, 1855.

18. *A Case of Triple Umbilical Hernia, containing various portions of the Abdominal Viscera.*

The patient, æt. 78, about eighteen years ago resided in Croydon, where her case excited much interest amongst some of the medical men. She was an intelligent old woman. About thirty-two years ago, after her last confinement, she found a little lump about the size of a marble protruding through the umbilicus. This gradually increased, until at length it acquired the size of the fist, when she sought advice. Various remedies were resorted to, but none of them appeared to be of any service. It still continued to grow in bulk, became very heavy, and caused considerable dragging down pains; its size attaining the bulk of a man's head. She could neither stand erect nor lie down flat. Her chest nearly approximated to her knees. Having lost her husband, she was obliged to resort to some avocation for support, and she kept a fruit-stall somewhere about Kensington Gardens, where she was, whilst able to crawl, crouched down upon a stool vending her fruits, this being the position most comfortable to her feelings. She had occasional attacks of gastralgia, sickness, and constipation, which were as often relieved by medicines. At length she became bed-ridden, and died the 22nd of February, 1856.

The mass presented was hanging pendulous from the umbilical region; and, in the many sacs which it contains, will be found incarcerated the lesser curvature of the stomach, the duodenum, the jejunum, a considerable portion of the small intestines, and the omentum, greater and less, and the ductus communis choledochus. The primary aperture at the umbilicus first gave way after a severe labour, which allowed a small knuckle of the ileum to insinuate itself, and escape from the abdominal cavity; by a gradual process, increasing quantities were forced through with the omentum, till the jejunum made its appearance, when this portion of the prima via succumbed to traction and pressure. Afterwards the duodenum followed in the same course, when, after thirty years constant work, the lesser curvature of the stomach became also incarcerated in this pendulous cavity, when death ensued.

At the primary aperture, on its posterior border, will be seen the omentum; on the anterior border, the stomach; and on the left border, the small intestines. Each structure was divided and separated from its neighbour by strong adhesive bands attached from side to side.

This specimen is *compound*, both in the number of chambers and substances incarcerated therein as well as in its openings.

The *primary* opening was at the umbilicus, as seen in the specimen; this grasped the stomach, omentum, and ileum: then the *first chamber* was formed between the lining membranous structure of the abdomen, and the *posterior* aponeurotic membrane of the rectus abdominis muscle; the next opening formed was through this aponeurosis; and the *next chamber* formed was in the substance of the muscle; then the external aponeurotic structure binding down the rectus muscle, gave way, making the *third opening*, which allowed the contents of the second chambers to force through, and thus forming the *third chamber*, the contents of which were arrested by the cuticle.

In this depending portion, destruction of the vitality of the gut had taken place; which is most likely in a gangrenous state, as may be observed from the green tinge on the skin.

Thus, in the mass, there existed three chambers or ventricles; the anterior, middle, and posterior, each filled with portions of the alimentary canal, having separate openings or communications one with the other, permitting the intestines and their contents to pass unmolested for a period of thirty years, without any constriction.

The stomach was considerably elongated, and tensely drawn down from the œsophagus to its entrance into the hernial sac; a traction which kept the chest bent upon the abdomen.

This case is interesting, and shows how long life can be preserved under such circumstances; and how, too, the fæces find their natural exit, however adverse and tortuous their course. Her bowels were relieved up to the last day of her life; and she had at no period, that I could ascertain, stercoraceous vomiting; certainly not whilst I attended her, for a period of

eight months. She ate and drank well, and was in good spirits. She had more fat about her than is usual for persons in her advanced years, showing that this state of things did not interfere with nutrition.

This case might have yielded to surgical treatment if the patient had resorted to it in the commencement; but it would have been impossible for a surgeon to have reduced this hernia subsequently by operation.

Dr. QUAIN for Mr. W. H. BORHAM, *4th of March*, 1856.

---

19. *A Specimen of Strangulation and Ulceration of the Small Intestine.*

A weaver's wife, a feeble and thin woman, æt. 45, was admitted into the London Hospital, under Mr. Luke, for a right femoral hernia that had been strangulated for six or seven days. Fæculent matter escaped after the coverings of the sac had been divided; and, on opening the sac which had given way at its inner part, the fæces were seen to issue from an ulcerated opening in the gut, equal in length to the concave border of Gimbernat's ligament. The patient died five hours after the operation.

On the *post-mortem* inspection, it was found that about four-fifths of the calibre of a piece of the small intestine had formed the rupture.

In this instance the taxis had never been applied. The case illustrates the fact, that the greatest amount of lesion to the bowel, in strangulated femoral hernia, occurs in that part of it which is in relation with the sharpest and most unyielding of the tendinous boundaries of the femoral canal, namely, Gimbernat's ligament.

Mr. NATHANIEL WARD, *18th of March*, 1856.

---

20. *A Case of Hydatids of the Liver, attended with Hæmorrhage into the Stomach and Bowels, proceeding along the Bile-Ducts from one of the Hydatid Cysts.*

E. A. æt. 29, a prostitute, had lived a very irregular life,

being frequently exposed to wet and cold, and suffering from want of food and clothing; at other times drinking to excess. She was admitted to University College Hospital, under Dr. Garrod, in July, 1855, for jaundice. Her illness had commenced a week before admission with retching; this was followed in two days by jaundice, with loss of appetite and thirst. On admission the liver was found to be enlarged, being full an inch below the umbilicus, and the epigastric region was very tense and tender.

After the action of an emetic, which caused her to bring up some considerable quantity of clear fluid, she felt much better; there was much less tension about the epigastrium, and the liver dulness did not extend so low down as before. After this she took mercurial pills and purgative draughts and some taraxacum; under the influence of these her jaundice diminished. She one day expectorated a small quantity of blood. About a month after admission, she was seized with severe spasmodic pain in the epigastrium, which lasted four or five hours. The liver dulness certainly did not at this time extend so low down as on admission.

She continued much in the same state, having nearly got rid of her jaundice, but remaining very anæmic, suffering occasionally from nausea, when, at the end of another month, she was suddenly seized with spasmodic pains in the stomach, and vomiting of blood. Blood, also, was passed per anum. She became excessively blanched, very restless, with cold clammy perspirations; and died in about twelve hours, with symptoms of internal hæmorrhage.

On opening the abdomen, the liver was found to be much enlarged: its weight was ninety-one ounces. The right lobe gave, in the greater portion of its extent, a feeling of distinct fluctuation. On making a section into this part, a large quantity of dark red fluid escaped. The interior of the cavity contained a large amount of soft clot. Apparently lining the cavity, but in some parts separated from the wall by loose clot, may be seen a buff-coloured layer of material, which is very fragile, about one-eighth of an inch thick, and finely laminated. On the surface next the liver it has a cribriform appearance;

it is evidently decolorised fibrine. This layer has a round aperture in it at one part, which corresponds to an aperture in the wall of the cavity leading to a biliary duct. This aperture, nearly one-third of an inch in diameter, which contained a worm-like black clot, is found to lead freely into a main division of the hepatic duct very near to its leaving the main trunk. After detaching the fibrinous membrane from the wall of the cavity, this wall is found to be much stained with bile, rough, and irregularly laminated. The liver substance outside the cavity is about an inch thick behind; in front there is little or no liver substance left. The wall of the cavity is pretty firmly connected with surrounding liver, but can be dissected from it. It is found to be composed of two layers; the outer one is of varying thickness, very tough, and has a fibro-cellular appearance. The inner one is not so thin, and is crisp on section; its internal aspect is much bile-stained, and rough: it is deficient opposite the large opening from the biliary duct. In addition to the large aperture, there are numerous smaller ones which lead to bile ducts. At one portion of the wall the two layers are separated by a soft, partially decolorised clot, about the size of a small walnut.

The hepatic duct is found to measure rather more than half-an inch in circumference, near its junction with the cystic duct. The branch of the vena portæ which accompanies the division of the duct leading to the cavity, is found to coast along its wall, but does not communicate with it. The corresponding hepatic artery, however, is found to communicate with the cavity by an oblique opening, at a distance of five-eighths of an inch from the aperture in the duct. The weight of the liver, after emptying the large cyst, was fifty-four ounces, so that its contents weighed thirty-seven ounces.

So far the character of this cyst was not very clearly determined: but, on examining further, there were found two smaller cysts, one about one inch and a quarter wide, containing a thick ochre-coloured matter of a creamy consistence, and with a cartilage-like wall; the other on the under surface of left lobe, as large as a walnut, having a lining membrane like the other, and containing a thin, translucent membrane folded in upon

itself, and some cheesy-looking stuff. This substance, examined microscopically, was found to be partly granular, and to contain many plates of cholesterine. Echinococci, or, at any rate, the teeth or characteristic hooks of these could be found in abundance. There is no doubt, then, that the third of these cysts was of hydatid origin; and there can be little doubt regarding the other two.

The upper portion of the small intestines was filled with fluid blood; the lower two-thirds of the ileum were empty.

It would seem, then, that the liver was the seat of three hydatid cysts. The largest of these had communicated freely with the biliary ducts; hæmorrhage had occurred into the cyst, probably from a branch of the hepatic artery. This blood had, in part, passed into the intestine along the hepatic and the common bile ducts, so as to cause hæmatemesis and melæna, and fill half the small intestines.

It is not an uncommon thing for the cyst of an hydatid in the liver to communicate by ulceration with a biliary duct; but I believe it is an uncommon thing for it to communicate with one of the blood vessels; and, certainly, it is very rare for it to communicate so freely as to cause a fatal hæmorrhage,—blood being passed before death from the stomach and the rectum in considerable quantities.

It would appear that hæmorrhage must have occurred into the cavity of the cyst previously to the final and fatal hæmorrhage, which occurred during the last few hours of life. The character of the layer of fibrin necessitates this supposition.

Dr. HILLIER, 16*th of October*, 1855.

---

21. *Hydatids in the Liver.*

M. L. admitted on the 30th of October, 1855. A married woman having two children. Never very strong. Four months ago the abdomen began to swell, at first slowly, and she believed herself pregnant. Three weeks ago it increased much more rapidly, and caused much dyspnœa and vomiting. She was tapped on the 22nd of October, but on admission into St. Thomas's Hospital she was as large as before the operation,

and it was evident that there was much fluid in the abdomen. She was tapped on the 6th of November. She gradually sank, and died on the 11th.

Post-mortem.—The liver was large and irregular in shape, enveloped in soft recent adhesions; a few firmer and older ones extended between its upper surface and the diaphragm. On endeavouring to remove it a tumor was discovered behind the gastro-hepatic omentum, which pushed it and the stomach considerably forward. This was found to be an hydatid tumor, about the size of a cocoa-nut, which had originated in the lobulus Spigelii, and had grown in, and filled up, to a great extent, the small sac of the peritoneum. It was somewhat adherent to the surrounding parts, and especially to the posterior surface of the stomach: the vessels going to the transverse fissure of the liver were pushed forward, and somewhat displaced by it; and the vena porta was flattened, compressed, and evidently obstructed by it. The walls of the tumor consisted of a dense fibrous material, about a line or two in thickness, the free surface of which was irregular; and, in many parts, evidently being removed by a process of ulceration. The sac contained some clear fluid, and a large number of hydatids; some collapsed, others plump, and evidently healthy. Among the former were large fragments, which appeared to have belonged to the large hydatid. The latter varied from the size of a hen's egg downwards. Echinococci were present in abundance. No ducts or vessels could be detected opening into the cavity.

At the posterior and right angle of the right lobe, was a cyst about as large as a duck's egg, but nearly globular in shape; the walls of which were of a dense fibrous material, and its cavity was filled by collapsed and laminated hydatids, whose walls were thick, and were universally stained of a bright orange-colour. There was a slight degree of moisture between them, but no measurable quantity of fluid. This cyst appeared also to have arisen in the substance of the liver; but was separated from the surrounding tissue by a deep fissure, which was partially obliterated by old adhesions. Independently of these tumors, the liver was somewhat enlarged, and

its surface was uneven and lobulated. On section, it was found to be irregularly congested, the tissue between the congested portions being irregularly pale. Under the microscope the pale condition was found to be due to deposit of fat in the cells.

The abdomen contained a gallon of straw-coloured and slightly turbid fluid; and the entire peritoneal surface, but chiefly the parietal portion, and that covering the intestines, was intensely red and inflamed—more in some parts than in others—diffused, but at the same time patchy; and some portions of the small intestines (those apparently which had been subjected to the greatest pressure) retained their normal colour. The abdominal parietes were lined nearly throughout by a layer of soft recently deposited fibrin. This varied in thickness; was rough and irregular on the surface; and in some places was deposited in patches. The mass of small intestines was slightly adherent to the flanks and to the great omentum anteriorly. The convex surfaces of the liver and spleen were closely applied and united to the diaphragm.

The small intestines were attached to one another, so as to form one roundish mass; the surface of which was enveloped in a layer of lymph, whence processes were sent down between the coils uniting them slightly to one another.

Dr. Barker, *20th of November*, 1855.

---

22. *Cirrhosis of the Liver, accompanied with profuse Hæmorrhage into the Stomach and Intestines.*

The subject was a girl, æt. 13, who had in early life been much exposed to the weather, and to privations of every kind. She had never been a healthy child; was thin, and of a very sallow complexion. Her breath had habitually been short. She is said on several occasions to have suffered from ascites and jaundice. On the 24th of January, 1856, she got up in her usual health; on the afternoon of this day she had a rigor, and felt very sleepy; she soon afterwards was observed to pass an unusual quantity of water. The next day she continued very drowsy, and had entirely lost her appetite. In the

evening she lost from the nose about two table spoonfuls of blood; and, during the night, she screamed and moaned very much; her bowels acted two or three times, but the character of the motions was not noted. A surgeon saw her at this time, and did not think seriously of her state. The next day she was brought to University College Hospital.

On admission her skin generally was very hot, especially her head; she was very drowsy: could be roused and induced to put out her tongue, which was sticky and brownish. Her pupils were large, acting equally, but imperfectly, under the influence of light. She could not be made to speak, but frequently moaned. Her eyes were not suffused; the skin was of a dusky tint. Pulse was one hundred and twenty-four. Respirations thirty-six in a minute. There was no renal tenderness; she had passed a large quantity of urine in bed. The abdominal walls were a little retracted, normally resonant on percussion.

She was cupped on the temples, to four ounces, and had a purge. The cupping made her rather faint. The bowels acted five or six times; the motions appeared to contain a little blood. At five P.M. she was ordered to take a grain and a half of calomel every four hours. At midnight she was found to be cool and the pulse very weak. During the night she was several times convulsed, and at half-past eight in the morning of the 27th of January she died.

Post-mortem.—Nothing remarkable was found in the head, except a little yellow discoloration of the membranes, as if jaundiced. In the heart nothing abnormal was observed, except that the edges of the mitral flaps were thickened, the cordæ tendineæ were shortened, and the endocardium was stained yellow. The lungs were slightly emphysematous.

The liver presented a very peculiar appearance; in many respects it resembled a brain; being lobulated and divided into two slightly unequal hemispheres, in shape very much like it; in colour being intermediate between the brain and ordinary liver colour.

The left lobe was about the shape and size of a healthy spleen; it was lobulated on the surface.

The peculiar shape of the right lobe appears to be due to the enlargement of the lobulus Spigelii, and the contraction of exudation matter between it and the right lobe. The capsule of the liver was not thickened, but was very firmly adherent. On section, the liver is seen to be made up of roundish lobes, which are subdivided into lobules, between the former are thickish partitions of cellular tissue. The section is of an ochre colour, and presents an appearance not much unlike very condensed adipose tissue jaundiced, and with an excess of areolar tissue. It is very tough, and in the neighbourhood of the broad ligament there is a quantity of exudation matter, which sends partitions into the liver substance; the same is true to a less extent near the transverse ligament. It weighs twenty-six ounces.

The stomach and upper part of the small intestines were almost full of black clotted blood. Peyer's patches were more injected than the surrounding intestine; they were not rough or notably elevated. Near the centre of a large patch, about two inches from the ilio-cæcal valve, is a small point of ulceration. The mucous membrane of the stomach presents, to a remarkable extent, the mammillated appearance. It is stained with blood near the pylorus; and, at some points, there are some patches of nearly uniform injection.

Dr. HILLIER, *5th of February*, 1856.

---

23. *Cystic Disease of the Liver, associated with similar Disease of the Kidneys.*

Brain and its membranes healthy.

Pericardium healthy. The heart was hypertrophied, and weighed nineteen ounces and a quarter. All its parts were proportionably enlarged. Its valves were healthy.

Pleura and lungs healthy, except that the surface of the left lung was studded with minute cartilage-like points.

Peritoneum healthy. Stomach and intestines healthy. Spleen large, weighing three pounds and half an ounce, dark-coloured and firm. Pancreas healthy. Testicles healthy.

The liver was large, and weighed four pounds six ounces

and a quarter. Its shape was natural. Its capsule was unthickened, and there were no adhesions. Its surface was studded with numerous bluish patches, from mere points in size up to about an inch in diameter. Many of these were single, but many were in clusters of two, three, four, or more. The smaller patches were usually round, and so also were some of the larger ones, but the majority of the latter were irregular in shape, and evidently formed by the union of several smaller ones. Some of them formed convex projections, but the greater number were even with the surface of the organ. On puncturing them, they were found to be the superficial indications of cysts formed in the substance of the liver. On section, these cysts were found to be thickly disseminated throughout the entire organ. They varied from mere points up to the size of a pigeon's egg. The smaller ones were globular, the larger more or less anfractuous. Their lining membranes formed thin transparent polished fibroid layers, marked by opaque white lines and projecting folds, which were clearly the remains of walls that had separated originally distinct cysts. Moreover, in many cases, neighbouring cysts were seen communicating by circular or ovoid orifices of different sizes, and the party-walls of others presented circular thinnings which evidently were the precursors of permanent communications. The fluid contained in these cysts was in every instance a thin, colourless, transparent serum. The general substance of the liver appeared to be perfectly healthy, and had a nearly uniform liver-brown colour. The gall-bladder was healthy, and contained healthy bile. So far as could be discovered by the naked eye, the vessels and ducts of the liver were healthy.

The kidneys were very much enlarged, one weighing two pounds seven ounces and a quarter, the other two pounds and three-quarters of an ounce. They measured between eight and nine inches in length, and their other dimensions were proportionate. Their surfaces were irregular and lobulated, and appeared to be formed by a series of cysts, which presented hemispherical projections from about the size of half a hen's egg downwards. The projecting walls of these cysts were, for the most part, thin and transparent, though in different de-

grees, but they were separated from one another by opaque rims of thicker fibroid tissue, assuming the appearance of a network, the interstices of which were round or polygonal, and of various sizes. On section, nearly the whole of the cortex and medulla of the kidneys was found to be replaced by a multitude of cysts, which was so numerous and closely packed, and which presented such variety as regards their contents, that the diseased organs might easily have passed for ovarian tumors. The cysts varied in size from that of a hen's egg, to points scarcely visible to the eye. A few were globular, but the majority were irregular in shape, and evidently formed by the confluence of several smaller ones. Their parietes consisted of a fibroid layer, with, for the most part, a smooth polished surface. They varied from delicate transparent films to dense opaque layers of considerable thickness, and they presented numerous circular thinnings, which were clearly the prelude to actual perforations. Many of the cysts, especially the larger ones, presented clusters of cysts projecting more or less into their interior, and their parietes displayed projecting folds and sinuous thickenings, which were clearly the remains of old cyst-walls. The cavities, too, were frequently crossed by bands of fibroid tissue, which evidently had had a similar origin.

The contents of the cysts varied extremely; those of some were thin, colourless, and limpid; those of others presented various shades of red, were often thick and muddy, and contained a considerable quantity of brick-red sediment; those of others again were almost black; and, in some cases, the contents were opaque, and more or less buff-coloured—at one time of the consistence of thin pus, at another, almost as thick as putty.

The cysts occupied nearly the whole of the glandular substance of the kidneys, and the cones were nowhere distinguishable. Here and there, however, small portions of the cortex, varying, on section, from half a square inch in area downwards, were still remaining. These had a whitish appearance, with little remains, to the naked eye, of kidney structure in them, and were studded more or less thickly with cysts, from the size of a pea, downwards.

The pelvis and infundibula, and more especially the calices of each organ, were considerably dilated, but contained scarcely any fluid. Their lining membrane was injected, but very little if at all, thickened.

The ureters appeared healthy. The mucous membrane of the bladder was congested, and its cavity contained a considerable quantity of flaky-looking, puriform fluid.

Microscopic examination. — The liver-cells generally were healthy. The walls of the cysts consisted of fibroid tissue, the free surface of which was lined by epithelium. This consisted of flat polygonal cells, united pretty firmly to one another by their edges, so that they became detached in masses, which looked like shreds of nucleated membrane. Each cell contained a nucleus as nearly as possible similar in size and shape to that of a liver-cell. The fluid within the cysts presented no microscopical elements beyond occasionally a little detached epithelium. The microscope threw no light on the origin of the cysts; there was nothing to show that they had originated in the ducts. The walls of the cysts in the kidneys, like those of the liver cysts, consisted of fibroid tissue, which was more or less dense. This tissue was rendered transparent by acetic acid or glycerine, and then displayed in its substance blood vessels in greater or less abundance, together with, here and there, an atrophied Malpighian body, and here and there a urinary tubule attenuated and filled with granular matter, or in an otherwise unhealthy condition. The cysts were lined by an epithelial layer, exactly like that lining the cysts in the liver. The cells composing it very closely resembled the cells of the uriniferous tubules, and, coming away as they did in patches, which were often more or less curled at their margins, were occasionally, at first sight, mistaken for them. The similarity between the cells of the tubes and those of the cysts suggested, when it was first observed, the idea that the cysts had really originated in dilatations of the tubes, and that their epithelium was identical in consequence of that origin. The basis on which the above surmise was founded, however, was shown to be fallacious, by the fact of the epithelium in the liver-cysts being of precisely the same character as that in the kidney-cysts.

By carefully adjusting the focus, the walls of the majority of the larger cysts, and, indeed, those of many of the smaller ones, were found to present here and there shallow pits and depressions of various forms. In no instance, however, could it be made out that these had anything to do with renal tubules; and, indeed, it seemed certain that they were only a repetition, on a smaller scale, of those irregularities which were visible to the unaided eye, and that they had been produced in the same way, *viz.*:—partly by irregularity in the growth of individual cysts, and partly by the coalescence of neighbouring ones. In the small isolated portions of the kidneys which still retained something of the original healthy character, tolerably healthy Malpighian bodies and renal tubes were detected; some of the former, however, were atrophied, and some of the latter contained more or less granular matter. Cysts of small size were detected here and there, but there was nothing in their appearance to indicate their origin. Few, if any, of the microscopic cysts, which have been described by Mr. Simon, were to be seen.

The microscopic characters of the contents of the cysts varied. The pus-like fluid owed its creamy and opaque character to the presence of numerous large transparent concretions, which were round, ovoid, or somewhat polyhedral, presented a number of concentric rings, and contained a nucleus or central portion, which was either homogeneous and structureless, or studded with granules and globules. The thick grumous material contained similar concretions; but they had, for the most part, a yellowish or brownish tinge. The latter presented also numerous altered blood corpuscles and remains of extravasated blood. The concretions above described cracked in the radial direction under pressure, and were, for the most part, dissolved after having been immersed for some time in spirit. Cholesterine also was present.

The above case is interesting as affording an example of a rare form of affection, *viz.*:—cystic disease of the liver. And the interest is enhanced by the fact of the co-existence in the kidneys of the same form of disease. I regret to say that I can throw no light upon the origin of the cysts in either of the

organs. There was nothing in the naked eye or microscopic characters presented by the liver and kidneys, and by the cysts developed in them, to indicate the cause of their origin, or the structures in which they had originated. I am inclined to think that the co-existence of the same form of disease in the liver and kidneys was merely a coincidence; this opinion, however, is founded solely on the difficulty I experience in tracing any necessary connexion between them, and in the fact that the cystic disease of the kidney, unattended by corresponding liver disease, is not at all uncommon.

The history of the case is unsatisfactory. The patient was a shoemaker, æt. 53, who stated that he had enjoyed good health until ten weeks before admission, when he was attacked with severe pain in the epigastrium and right side, which was supposed to depend on pleurisy. He was laid up for five weeks, and on the subsidence of the severe symptoms, he first noticed that his urine was bloody. The urine continued in this condition, presenting also a copious yellow deposit, up to the time of his death. He was very low and feeble on admission and died two days afterwards.

Dr. Bristowe, 1*st of April*, 1856.

Report on this Specimen.—The portal vein was injected with plain size, and the duct with Prussian blue. In two or three instances the injection escaped from the duct into the cysts, by the rupture of their walls; in no case were dilatations of the ducts themselves observed. Many of the smallest cysts were found to be situated in the central part of the lobule, and therefore at some distance from the ducts. Hence I infer that these cysts were not produced by obliterations of the duct.

In several instances the network in a particular part of the lobule, was seen to be very lax; its meshes three or four times their natural diameter; the capillary vessels were much stretched, and the liver cells apparently disintegrated, their position being occupied by granular matter. As fluid accumulated, the network would be still further stretched, until at last all the normal structures would be removed. I am led to conclude, therefore, that the formation of the cysts commenced within

the lobule itself, and not in the interlobular fissures, and I think it probable that the first change which took place consisted in an alteration of the secreting cells (liver cells).

The formation of the cyst in this instance does not depend upon closure of a part of the tube; and the subsequent accumulation of the secretion behind this point. Indeed, from the anatomical arrangement of the parts, a physical explanation of this kind is inadmissible in the present case.

Dr. LIONEL BEALE, 15*th of April*, 1856.

24.—*Cystic Disease of the Liver and Kidney.*

These are old preparations belonging to the Museum of Guy's Hospital, but brought to the Society to be placed in association with those of Dr. Bristowe, exhibited at the preceding meeting. The latter specimens presented a very remarkable cystic disease of the liver, accompanied by a similar condition of the kidney. The cystic degeneration in this organ not being uncommon, Dr. Bristowe was inclined to regard the similar affection in the two organs as a mere coincidence.

With reference to the present specimen, I had often been struck with its remarkable nature while on the shelves of the Museum at Guy's. I had never met with, or heard of, a similar specimen, until I saw the one brought to the Society by Dr. Bristowe. Unfortunately, no history is attached to the preparation, and the following is the only account appended in the catalogue :—

"Portion of liver, with numerous cysts embedded in its substance. They prevail towards one extremity, and affect the convex rather more than the concave surface. They appear to be dilated cells rather than adventitious structures. (Dilated vessels or ducts, or depending upon the intervening substance, the acini being wasted?) The kidney in contact with this part of the liver is almost converted into a mass of irregular cysts."

The account given of the kidney is—"Kidney greatly enlarged; structure pervaded with numerous cysts of large size, apparently the result of the dilatation of the uriniferous tubes.

The infundibula are somewhat distended, but they are but little altered. The liver, in its immediate vicinity, is also pervaded with irregular cysts."

It would appear, from the wording of these descriptions in the catalogue, that the diseased portion of the liver was in contact with the kidney, and that an inference is drawn that the development of cysts in the former was dependant upon this contiguity. All proof, however, is wanting that the disease has been propagated in this way; but, judging from the analogous instances of the spread of inflammatory action, or of cancer and tubercle by contact, there seems no *à priori* objection to the possibility of such a mode of development of the disease.

As regards the nature of the cysts themselves, the specimen is probably too old to make out their character. The cysts are crowded together in immense numbers, and vary from the smallest possible size to that of a walnut, and are separated from one another by thin membranous partitions. They resemble closely those in the kidney, which is increased to five or six times its natural size, being, in fact, one mass of cysts, some of which reach the size of an ordinary egg. There can be no doubt that there would be the same variety of opinion with respect to the origin of these cysts in the liver, as there is about their production in other organs, pathologists being at present much divided as to their mode of formation, whether arising from areolar spaces, from dilated ducts, or whether they are altogether new growths. In the liver, where the ducts are so liable to be obstructed, a view founded upon their dilatation would be very likely to be taken; and such a process, no doubt, does sometimes occur. Cruveilhier, in his large work on "Pathological Anatomy," gives drawings of cavities in the liver, which he believes to be dependent upon dilated ducts. His two cases, however, are so, meagrely reported, that no conjectures can be formed about their nature. Dr. Budd, in his work, also speaks of this form of disease, and says it happens now and then in catarrhal or suppurative inflammation of the hepatic ducts, that many of the small ducts become temporarily blocked up at some point, and that the portion behind gets dilated into an

irregular pouch, which is filled with a glairy or purulent fluid, more or less tinged with bile. Dr. Budd then quotes a case from Cruveilhier, occurring in *La Charité*, of a woman who died with jaundice, after a few days' illness, and in whom the liver, on section, presented small irregular cavities, containing a thick purulent mucus. There were thousands of such cavities in the right lobe; some of these seemed formed of small gall ducts, dilated. The common duct contained a calculus. Dr. Budd then remarks, "that the saccular distension of the small ducts seem to have resulted from inflammation of their lining membrane, which, by blocking up the ducts for a time at certain points, caused the portions beyond to be dilated into irregular pouches by accumulation of purulent fluid and bile, which had no longer an outlet;" and he then adds "that it would seem that sacculated pouches formed, as in this case, by permanent closure of the duct at the point of obstruction, may be converted into small permanent cysts, filled with a glairy fluid more or less tinged with bile. It is difficult to account in any other way for the cysts of this character that are now and then found in the liver."

I have quoted these views from Dr. Budd's work, to show what is at present known on the subject; but at the same time I do not think such mode of formation of cysts obtains in the present instance. A dilatation and obstruction of bile ducts is not uncommon, but with these there are jaundice and more or less acute symptoms. In Dr. Bristowe's specimen, however, and my own, the disease appears to be chronic and local, and unattended with any manifest symptoms; and thus it appears to be one altogether analogous to those slow cystic degenerations seen in other organs, as the choroid plexus, kidney, chorion, &c., in all which cases my own opinion is that the cysts depend upon new growths. The principal interest in the present imperfect specimen, is its close resemblance with that of Dr. Bristowe, which is, no doubt, one of a very rare disease.

Dr. WILKS, *15th of April*, 1856.

---

25. *Hypertrophied Spleen. Leuchœmia. Cirrhosis of Liver. Deposit of Carbonate of Lime on Lining Membrane of Gall Bladder.*

The spleen weighed four pounds four ounces and a half; it measured eleven inches and three quarters in length, and four inches in breadth at its broadest part. Adhering by a narrow neck to its lower extremity was a rounded accessory spleen, about the size of a walnut. On section the organ presented a reddish-brown colour, with numerous lighter specks about the size of millet seeds, produced by the Malpighian bodies. The consistence of the pulp was rather firmer than usual, except at the upper extremity of the organ, where it was somewhat diffluent; in other respects there was no alteration from the normal structure. The capsule, at several parts, was thickened, indurated, and of almost cartilaginous consistence.

The blood, from whatever part of the body it was taken, exhibited, under the microscope, the appearances which have been so well described by Dr. Bennett and Virchow, under the designations of *leuchœmia* and *leucocythœmia*. There was a great increase in the number of colourless corpuscles, which, on the addition of weak acetic acid, presented a single, double, treble, or quadruple nucleus. Some of these nuclei had a crescentic form, and most of them appeared to be depressed in the centre, not unlike small red corpuscles. Some of the cells, in addition to these nuclei, contained several minute oil globules. The red corpuscles were not collected in rolls, as in some of the cases of leuchœmia which have been described. Suspended along with the red and white corpuscles was a quantity of granular matter and a few oil globules.

The spleen and blood were obtained from the body of a female, æt. 37, of whose history the following are a few particulars. She was born in London, where she had always resided. She had lived a very temperate life; but had always been very delicate. The catamenia did not appear till she was twenty, and had always been scanty; and though she had been married for eleven years she never had any family, nor even a miscarriage. In 1850 she first noticed a swelling in her right side; but this

did not give her much inconvenience till the end of 1853, when the whole abdomen began to enlarge: and on the 12th of April, 1854, she was admitted into the Hospital for Women in Soho Square, under Dr. Tanner.

She was then suffering from diseased liver and ascites, her abdomen measuring forty-three inches and three-quarters in circumference, and eighteen inches and a half from the ensiform cartilage to the pubes. During her stay in Hospital she was treated with iodide of potassium, mercurial ointments, and purgatives, and the abdomen was tapped four times. On the 17th of April, three hundred and fifty-six fluid ounces were drawn off; on the 19th of May, four hundred; on the 16th of June, four hundred and thirty-one; and on the 7th of July, four hundred and four; altogether fifteen hundred and ninety-one ounces. After the last operation the fluid did not collect again; and on the 7th of September she left the Hospital with the abdomen the natural size, and apparently cured.

After this there does not appear to have been any return of the ascites; but some months after she began to suffer from ulceration of the mouth and throat, with discharge and great fœtor of the breath. Several of her teeth came out; and in October, 1855, a portion of the alveolar process of her lower jaw exfoliated. She applied to various medical men for relief; and, on the 12th of March, 1856, came under my care at the Western General Dispensary. She was then confined to bed from extreme debility, was remarkably pale and much emaciated. She complained principally of pain and difficulty in swallowing; and, on looking into the mouth, there was observed extensive ulceration of the fauces and back of the pharynx, as also round the margins of the teeth. The breath had a fœtid odour, like that produced by mercury. She stated, however, that she never had taken mercury, and an inspection of various prescriptions confirmed her statement. She never had syphilis, and her voice was scarcely affected. She had but little appetite; her bowels were regular, and the fæces of natural colour and consistence. The pulse was rather quick, but very feeble. Her mother stated that she was liable to occasional severe attacks of epistaxis, and bleeding from the gums. On

examining the abdomen, the hepatic dulness, on percussion, was not increased, and no fluctuation could be made out, but the whole of the left side, from the ribs to the crest of the ileum, and as far forwards as two inches and a half from the umbilicus, was filled up by a solid tumor.

She was treated principally for the affection of the mouth. Strong solutions of nitrate of silver and chlorine gargles were applied locally; and at the same time wine, ammonia, and quinine were freely administered. No improvement, however, took place. The ulceration extended. One of her teeth and some small pieces of bone from the alveolar processes came away, and the body of one of the cervical vertebræ became exposed. The difficulty of swallowing increased, and at last, on attempting to swallow fluids, they were mostly rejected by the nares. She continued to sink, and died on the 30th of March.

The body was examined on the third day after death. The head and throat were not permitted to be examined. The heart and lungs were healthy. On opening the abdomen, the great omentum was found firmly adherent to the abdominal wall. There was about a pint of serous fluid in the abdominal cavity. The spleen presented the appearances already described. Both it and the liver were firmly adherent over their surface to the surrounding parts. The liver was in an advanced stage of cirrhosis. There was bile in the ductus communis choledochus, but none in the gall-bladder. The gall-bladder was collapsed, and, on opening it, its lining membrane was found perfectly white, and encrusted with fragments of a white earthy matter, many of which were firmly adherent. The neck of the gall-bladder was quite blocked up by this matter. This earthy matter was found to effervesce strongly with acids; and microscopic examination showed it to consist of rounded crystalline particles, varying in size from $\frac{1}{400}$th of an inch to an almost infinite degree of minuteness, and which, in some few instances, appeared to be made up of radiating acicular crystals, cohering at the centre.

The pancreas was not examined. The kidneys were pale and anæmic, but otherwise healthy.

Dr. MURCHISON, *15th of April*, 1856.

V.—DISEASES, ETC. OF THE URINARY AND GENERATIVE ORGANS.

1. *Cystic Disease of the Testis occuring in an Infant, and probably Congenital.*

The specimen of cystic disease of the testicle exhibited, was removed by me lately from a child, æt. 2 years and nine months, at the Hospital for Sick Children.

The right testis, prior to the operation, measured six inches and a half in circumference in one direction, by seven inches and a half in another. It was oval in shape, generally smooth, but presenting two or three slight elevations on the surface. It was tense, slightly fluctuating in some parts, but very hard behind, feeling there like a mass of bone. The scrotum was not reddened, nor in any way adherent to the testis. The cord appeared healthy. The tumor was only slightly tender on being handled, but gave rise to pain and inconvenience from its weight and liability to injury. The left testis appeared natural.

The child was stout and healthy-looking; there was no appearance of scrofulous taint, and no enlargement to be detected in the lumbar region. The parents were healthy, and no hereditary disposition either to struma or to cancer could be traced.

The child was three months old when the mother first noticed that the right testicle was much larger than the left, it being then of the size of a hazel-nut. Her attention was accidentally drawn to the part, and she states that she really cannot say whether any enlargement existed at the time of birth or not.

The tumor increased in size, at first slowly, afterwards more rapidly, till the child was fourteen months old, when he was brought to me from Bedfordshire. The testis was then nearly the size of a small hen's egg, and presented the same general characters as have been previously described. I punctured it with a grooved needle, and let out a small quantity of clear

jelly-like fluid, mixed with whitish flakes, presenting, under the microscope, some granular corpuscles with large irregular granules. The mother was unable to leave the child in London on that occasion, but promised to bring him again at some future time if the swelling continued to increase; accordingly in the January of the present year, he was admitted into the Hospital.

Previous to removing the testicle, I again punctured it with a needle, and evacuated about a teaspoonful of the same kind of clear fluid as on the previous occasion.

I may mention that the child has progressed most favourably since the operation, without a single bad symptom.

For the very careful description of the tumor which follows, as well as for the admirable drawings which accompany it, I am indebted to my colleague, Mr. H. V. Carter, who has already had some opportunities of investigating this form of disease of the testis at the College of Surgeons, and who kindly undertook the examination.

General description of the Tumor.—It is of a regular, almost globular form, measuring two inches in the long, and one inch eight lines in the short, diameter. It is invested to the usual extent with the tunica vaginalis, and at the posterior surface may be seen the *epididymis*, presenting its normal aspect, though somewhat attenuated from expansion and pressure. The *vas deferens*, with the exception of being very small in size, is also unaffected. The *tunica albuginea* is intact, and preserves its smooth, uniform appearance, owing to the regular and even growth of the tumor. Within the cavity of the tunica vaginalis are two or three slender, elongated, thin-walled cysts (Plate XII. Fig. 1 *a a.*), which spring from the tunica albuginea; two of these are found near the head of the epididymis, and one below.

The appearance of a vertical section of the tumor is as follows (Plate XII. Fig. 1.):—The whole surface is uniformly studded with very numerous cysts, and no remains of the normal structure and disposition of the gland can at first be seen. The cysts vary in size from that of a horse-bean to something less than

DESCRIPTION OF PLATE XII.

The figures illustrate the naked eye appearances on section, and the microscopic structure of Mr. Athol Johnson's case of Infantile Cystic Disease of the Testis, p. 241.

Fig. 1. Section of the tumor.

a a. Cyst appendage in the vaginal cavity.

b. Epididymis.

c. Vas deferens.

Fig. 2 *d.* Represents some of the contents of the cysts, *viz.*—Delicate walled granular cells, large and small, some undergoing fatty degeneration; one is shown containing pigment.

e. Fibrous matrix.

f. Lacunæ from the osseous spicula.

Fig. 3 *g g.* Ciliated epithelium from the walls of the cysts.

h. Pavement epithelium occuring in the cyst-appendages; but unfrequent.

The microscopic characters are all represented as enlarged 400 diameters.

Fig 1

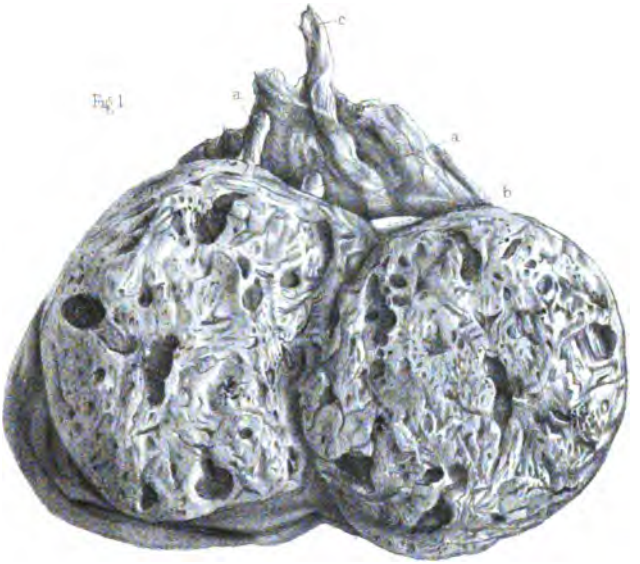

Fig 2.

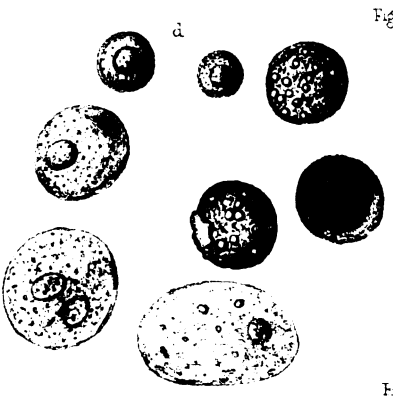

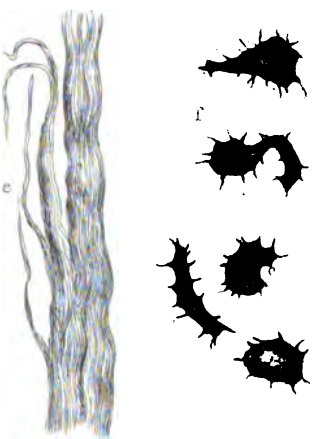

Fig 3

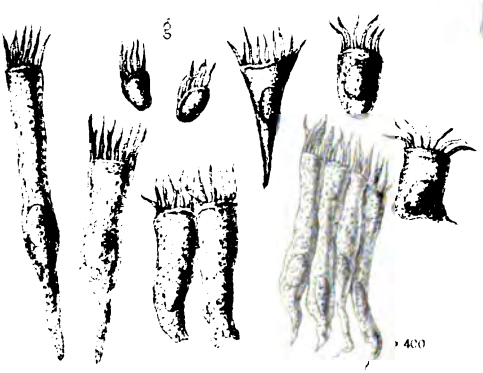

H 7 Carter del. Tuffen West lith.

W West Imp

a pin's head; their contents consist of a clear glairy mucus, almost colourless, which flows out very abundantly when the cysts are opened; they are embedded in a matrix which is manifestly of a fibrous character. A few spots of dark pigment are seen, and osseous spicula project from a considerable bony mass placed at the back part of the tumor, which required some force to divide it on making the section of the testicle. The cysts are multilocular and smooth-walled; they are not simple cavities like cysts found in the kidney, or the hydatid cyst; but many of them probably communicate with one another by the irregular extensions sent off from their sides. There are no growths from their walls. On the whole, the cysts are larger at the circumference than near the centre, and are, moreover, flattened at the former situation; this seems to indicate growth outwards; in no other respect can any peculiar arrangement be observed. The tunica albuginea is evenly spread over the mass, and on closely examining its inner surface, a thin layer of gland-like tissue may be detected in some parts; this has clearly been pushed outwards in the growth of the cysts, but cannot be seen everywhere at the circumference. It may be added that gland-tissue is also found dispersed throughout the entire mass of cystic growth, by the aid of the microscope. In this peripheral layer of normal tissue, a cyst was detected, having its origin amongst the tubuli seminiferi, and which, projecting outwards, had perforated the tunica albuginea, ultimately forming one of the three cyst-appendages, noticed above, as floating free in the cavity of the tunica vaginalis. The cysts are innumerable.

Microscopic examination.—The contents of the cysts consisted of a few blood corpuscles, cholesterine, no spermatozoa, abundant cell-forms, either very large, oval, or round, delicate-walled granular cells, having one or more nuclei, or smaller cells of rounded form, clear, and presenting a central clear nucleus, or modifications of the first cells smaller in size and elongated in form (Plate XII. Fig. 2 *d.*). The first variety of cells is most abundant; they may be seen in a state of involution, containing fat granules; the pigment is also found in similar cells.

The flocculi found in the mucus are composed of masses of *ciliated epithelium*, which appear in all cases to have lined the walls of the cysts: a very unusual circumstance. The form of this epithelium resembles that of the mucous membrane of the air passages; the cells varied greatly in size and shape (Plate XII. Fig. 3 *g g.*). The cyst, which was observed to arise amongst the peripheral gland-tissue and to project into the cavity of the tunica vaginalis, differed essentially from those forming the mass of the disease, in being lined with the usual pavement epithelium (Fig. 3 *h.*).

A minute examination of the fibrous *inter-cystic* tissue disclosed, as before stated, *tubuli seminiferi* in most parts; these appeared to be atrophied, and were of very irregular diameter; their dilatation into cysts seemed not improbable, but could not be clearly seen. On the other hand, cysts lined with *ciliated epithelium*, were traced down to a size little beyond the diameter of a seminal tube, and large cells or smaller cysts were frequently seen in groups or alone, which apparently could not possibly be connected with the tubes in question. In the opinion of the writer of this report (Mr. Carter), these cysts have probably an origin independent of the tubuli seminiferi, and this opinion is grounded on, 1, the microscopical appearances; 2, the singularity of the lining epithelium; and 3, the fact that a cyst, manifestly arising amongst the tubes, resembled the usual variety of the cyst-growth, having a pavement epithelium on its inner walls.

The osseous spicula are developed in the fibrous tissue (Fig. 2 *e.*); no cartilage cells were discovered; the lacunæ or bone-cells (Fig. 2 *f.*) are irregular in form and disposition, usually of large size, and having few canaliculi proceeding from them. Haversian canals were very rare, and the concentric lamellæ very imperfect.

Remarks.—This specimen of the rare affection to which the name of cystic sarcoma of the testis has been given, appears to me to present some points of interest.

1. As regards the age of the patient. The disease usually commences at the middle period of life. In this instance it was

either congenital or nearly so, a circumstance so very rare, if not unique, as to lead me, before the operation, rather to suspect that the case might be one of fœtal textures included or contained in the testis, a few instances of which are now on record. The peculiar sensation as of a mass of bone at the back part of the tumor, tended also considerably to strengthen this suspicion.

2. The existence of bony structure, with lacunæ, canaliculi, and even Haversian canals, is not common; small masses of enchondroma, indeed, have been frequently found mixed up with the cystic growth, but no mention is made in Mr. Curling's excellent work on the subject of bone having been found in true cystic disease, though of course it has been in other affections of the testicle.

3. The existence of the cysts lined with ciliated epithelium resembling that found in the air passages is certainly most unusual. Mr. Curling, in his remarks on this disease, describes the cysts, in the non-malignant form, as lined by tesselated epithelium, and as arising in dilatations of the tubes. In the malignant affection of the testicle, on the other hand, where the great bulk of the tumor is composed of cysts of various sizes, the presence of nucleated cancer cells would indicate the nature of the disease.

In this specimen, however, whilst the cysts which arise from amidst the peripheral gland tissue, and which project in the curious manner observed in the specimen into the cavity of the tunica vaginalis, were lined with the usual pavement epithelium, the cysts constituting the mass of the disease contained ciliated cylindrical epithelium. These latter cysts, moreover, could be traced down to a size little exceeding the diameter of the seminal tubes from which they were distinct, and with which their arrangement appeared to render it impossible they should be connected. It will be seen, consequently, that Mr. Carter arrived at the conclusion, for the reasons given in the report, that the cysts, forming the principal mass of the disease, had their origin *independent* of the tubuli seminiferi, and not in the manner now usually admitted.

I may mention in conclusion that Mr. Carter has directed my

attention, in relation to this form of cyst, to the description of a tumor given in Wedl's "Pathological Histology, p. 448. This tumor, taken from the sacral region in a child, and situated in the continuity of the bone, presented numerous cysts containing a gelatinous or glutinous fluid, whilst on their inner surface the remarkable occurrence of the most beautiful and perfect ciliated epithelium was observed.

Mr. ATHOL A. JOHNSON, *5th of February*, 1856.

---

2. *Thick Wall Cyst in the Tunica Albuginea Testis.*

A moderately healthy man, æt. 63, was admitted at the Metropolitan Free Hospital, on account of a tumor involving the left testicle. He stated that about six years ago he had consulted a surgeon, the enlargement having then existed for six months. The swelling was punctured, and some clear water having been let out, it almost wholly subsided. Very shortly afterwards, however, a slow and painless increase in size again commenced, and in about two years the part attained its present size. During the last three or four years it had, as regarded size, been stationary; but the inconvenience which its weight caused him had been felt more and more, and he was now very anxious for some medical treatment. He had a hernia on the same side; and the disease of the testis had prevented him from wearing a truss, as aching was always caused by the pressure of the pad. The affected part was about the size of a goose's egg, somewhat flattened, heavy, and inelastic. Its upper five-sixths were rounded and tolerably smooth, and were separated by a shallow but easily felt depression from the lowest part, which was soft, and felt like the testis itself. The opinion formed was that the disease was a dense walled cyst, within the capsule of the gland, but with the greater part of the latter isolated below it, was confirmed by the patient's description of his sensations. Pressure on the upper part of the tumor, he said, caused only a "numby feel," but when the lowest part was compressed, it felt "as if his testicle was nipped." No fluctuation could be felt. The diagnosis of irremediable disease being positive, and the man being anxious to have the organ

removed, excision was performed in the usual way in February, 1856. The wound healed well, and no inconvenience resulted.

The tumor was injected from the spermatic artery previous to dissection. It proved to be a single thick walled cyst, developed in the layers of the tunica albuginea, and by which the gland structure itself had been displaced downwards. (Fig. 6).

FIG. 6.

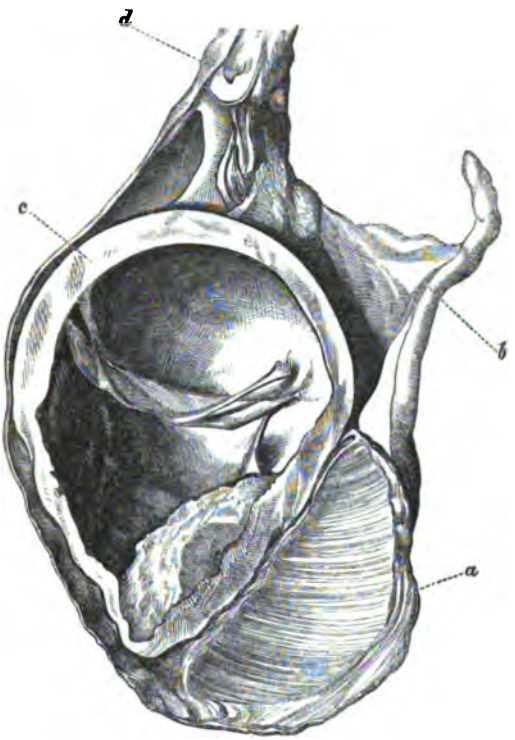

Cyst of the natural size.
a. The testis.
b. The vas deferens.
c. The cyst, with its lining membrane partially detached, and a solid vascular mass of granulations in its lower part.
d. The cord.

The latter, in a healthy condition, but somewhat paler than

natural, was found exactly in the position which, during life, it had been presumed to occupy. The vas deferens ran over the back of the cyst, but was not structurally connected with it. The walls of the cyst, in all places very thick and rigid, consisted of condensed fibrous tissue, with here and there a few spiculæ of bone. The investing layer of tunica albuginea, common to the cyst and the displaced gland, could easily be traced, as well as the thicker layer which invested the gland only, and separated it from the former. The contents of the cyst were a greyish-brown fluid and flakes of lymph. It had internally an organised false membrane, which, in the drawing, is represented as partially detached; and at its lower part was a growth of solid but softish granulations, into the lower part of which the injection had freely entered. The veins of the cord were somewhat varicose, but otherwise the parts composing that structure were healthy.

It might be questioned whether, in this case, the cyst had not arisen from a puncture of the testis in the operation for hydrocele said to have been performed six years before. Supposing an interstitial effusion of blood into the tunica albuginea to have resulted from such a puncture, it is easy to suppose that the organisation into a cyst might have ensued thereon. The specimen, although a very rare one, is by no means unique. It resembles certain others which have been described by writers under the ill chosen name of hydrocele of the testis.

Mr. HUTCHINSON, *4th of March*, 1856.

---

3. *Stricture of the Urethra. Great Hypertrophy and Sacculation of Bladder in a man æt.* 42.

C. B. æt. 42, was admitted into the Marylebone Infirmary in October, 1855, under the care of Mr. Henry Thompson. He complained of the usual symptoms of severe stricture, and after two or three trials, a No. 1 catheter was introduced into the bladder, and firmly grasped. It was tied in for twenty-four hours, and a larger introduced. By degrees dilatation was carried up to No. 10. His urine, meantime, was largely purulent and albuminous; but at the end of November, dila-

tation having ceased, it became worse, and he was unable to empty his bladder. Accordingly it was necessary to do this for him by catheter three times a day. Symptoms of cystitis had appeared, and the urine became increasingly purulent and fœtid. Ultimately he sank exhausted on the 15th of December.

Post-mortem examination twenty-four hours after death.—Genito-urinary organs removed entire. Remains of the stricture were seen at the junction between prostatic and membranous portions. Enlarged lacunæ and two small abscesses in the prostate. Walls of bladder greatly hypertrophied; cavity small; mucous lining exhibits crimson injection throughout. An opening exists at the middle of the posterior wall capable of admitting a goose quill, which leads into a sac, from which issued two ounces of thick and glutinous pus. Its walls are one-fifth of an inch in thickness: those of the bladder are five-eighths of an inch thick. The latter are easily separated into three layers. The outer is made up of interlacing bands: a dense middle layer of transverse or circularly disposed fibres, three-eighths of an inch in thickness, is distinctly marked off from the third and inner, which consists of a thin layer of interlacing bands and mucous membrane. On examining the middle layer under the microscope, every part of it is seen to consist of well marked and almost unmixed organic muscular fibres, bound together with curling filaments of elastic tissue. Both kidneys are much enlarged, and contain abscesses. The ureters are convoluted, and about the size of the middle finger throughout.

I have repeatedly observed, on examining the minute structure of the ordinary hypertrophied bladder in elderly subjects, such as we ordinarily meet with, that the muscular fibres are much obscured by the development of a large quantity of ordinary white fibrous tissue, which seems in these cases to exist in a much larger proportion to the muscular element than in the normal state. This case is a remarkable exception to that general observation. May it not be possible that the cause is to be found in connexion with the comparative youth of the patient? It is not common to meet with this degree of hypertrophy and sacculation during middle age.

Mr. Henry Thompson, 18*th of December*, 1855.

4. *Polypoid Growth from the Verumontanum.*

A man, æt. 54, died at the Marylebone Infirmary, 12th of January, 1856, in a comatose condition from pneumonia, twelve hours after admission.

At the *post-mortem* examination, there was discovered a small polypoid growth, continuous at its base with the apex of the verumontanum, lying in the urethra, which it appeared to fill, and reaching to the neck of the bladder (Fig. 7A.). It was about five-eighths of an inch in length, soft in consistence, and composed of the elements of fibro-cellular tissue, with a few organic muscular fibres intermingling at its base. In some

FIG. 7.

The engraving represents the growth from the Verumontanum, *in situ*, at A.
Crystals obtained from the tumor are figured at B.
The forms marked *a. a.* were the most numerous.

parts were seen numerous fibro-plastic cells with well marked nuclei, lying intermixed with the tissues. Among these structures, especially towards the centre of the growth, were some minute crystal-like bodies, having very much the appearance of uric acid, yellowish in tint and rhomboidal in form, with a few octahedra (Fig. 7 B.). They were, however, insoluble in potash and ammonia, and dissolved in acetic acid slowly,

with some effervescence. They were, therefore, probably crystals of an earthy carbonate. The tumor was covered with mucous membrane, and columnar and spheroidal epithelium. It is worthy of remark that the constituents of this growth (the crystals excepted) very nearly correspond with those forming polypoid tumors of other parts of the body; those, for example, of the nasal passages, antrum, and pharynx. In these, both M. Lebert and Mr. Paget* have particularly remarked the presence of fusiform nucleated cells, to which they have given the name of "fibro-plastic," intermingled with the fibro-cellular elementa.

On making inquiry of this man's relatives, the only point elicited having any bearing on his condition was, that he was in the habit of passing water with greater frequency than usual.

There is no other specimen of this condition in the human subject in the museums of any of the Metropolitan Hospitals. In the College of Surgeons is a similar growth from the verumontanum of an ox put up by John Hunter; and there are in other museums two or three specimens of small polypoid formations from the mucous membrane of the urethra *anterior to the prostate;* but these growths, in any form, are exceedingly rare. Mr. HENRY THOMPSON, *5th of February*, 1856.

---

5. *Tumor of the Prostate Gland.*

The patient from whom this specimen was removed was an old man, æt. 62, who was admitted into St. George's Hospital on the 18th of January, 1854, on account of diarrhœa, accompanied by pain in the abdomen, from which he had suffered for some time past. He also stated that he had had some difficulty in passing his water for a considerable time; and that occasionally it dribbled away from him. The urine, on examination, was found slightly albuminous, and rather turbid from the presence of pus. He had also been suffering from cough and shortness of breath. He was emaciated, and his aspect remarkably sallow and patchy, with injected cheeks, having much the features of a patient labouring under renal disease.

* *See* Paget's "Lectures on Surgical Pathology," vol. ii., pp. 103, 120, and 212.

Some difficulty having arisen on the introduction of the catheter through the neck of the bladder, it was supposed that the prostate gland was enlarged. Fever of a low typhoid form set in, of which the patient died eleven days after his admission.

On the *post-mortem* examination it was found that, at the neck of the bladder, there projected into its cavity a firm tumor, which at first sight appeared to be a hypertrophied lobe of the prostate gland. It was about the size of a small walnut, with a contracted root at its connexion with the back part of the neck of the bladder, and of a solid consistence. On cutting into it there was found, occupying its centre, a small tumor of a circular form, about the size of a hazel-nut, contained in a thick capsule of fibrous tissue, from which the tumor was easily turned out. This smaller tumor was very firm in texture, its structure consisting of cæcal pouches filled with epithelium, connected to each other and surrounded by a fine filamentous tissue. The bladder was hypertrophied and densely fasciculated, containing a large quantity of purulent urine. The ureters were dilated, as also were the pelves and infundibula of both kidneys. The kidneys were softened, very vascular, and disseminated throughout with numerous small abscesses.

These tumors, in their structure closely resembling that of the normal gland in or near which they arise, are of very considerable interest from the close analogy they bear to some of the forms of mammary glandular tumor. It is not improbable, from the great resemblance they bear to an hypertrophied lobe of the prostate gland, especially when of large size, that they are occasionally mistaken for that disease, a circumstance which is very likely to occur unless a very accurate examination is made of the diseased part. In two examinations which I have myself made of the prostate gland, in which it had been reported that one of the lateral lobes in each case had been hypertrophied, I found that this enlargement was due, in each case, to the development of a glandular tumor in the external capsule of the gland, which in its growth had projected into the cavity of the bladder. It would appear that these tumors may be developed in any part of the gland. In the case recorded by Mr. Shaw, in the Proceedings of this Society for

1848–49, p. 83, a tumor of a structure precisely similar to the present case, was developed in the centre of the left lobe of the gland. In the case above mentioned the tumor most probably was developed in the outlying tissue of the gland, and thus, during its growth, projected into the cavity of the bladder, where it appeared as a pedunculated tumor. A similar case has been recorded by Mr. Paget, in his work on "Tumors," p. 9. The case also, recorded by Mr. Fergusson in the "Proceedings of the Pathological Society" for 1848, p. 83, in which two small tumors were removed, together with a stone, in the operation for lithotomy, was probably one of prostatic glandular tumors, bearing the same relation to the neck of the bladder as that in the case above mentioned.

Mr. Henry Gray, 20*th of November*, 1855.

---

6. *Enlargement of the Prostate due to Fibrous Tumors. Diseased and Sacculated Bladder.*

J. P. æt. 74, admitted to the St. Marylebone Infirmary 27th of October, 1855, under the care of Mr. Henry Thompson.

For two or three years he has suffered with the ordinary symptoms of chronic cystitis. There is much irritability of bladder, no retention or incontinence. No 10 catheter is passed with perfect ease. Bladder slowly empties itself of pus and mucus after urine is drawn off. No calculus. Urine thick, opaque, yellowish, mixed with much pus, slightly acid on several occasions. Albumen considerable. No renal casts or crystals.

A very slight degree of enlargement of the prostate gland is recognisable from the rectum. Patient suffers very little pain, but is extremely weak, and appears to be gradually sinking. Death occurred on the 7th of November.

Post-mortem examination six hours after death.—Bladder and part of urethra removed entire. The former is elongated, and projects upwards behind the pubic symphysis: the walls are thicker than natural. Projecting into the cavity at its neck, is a lobulated tumor about the size of a small walnut, of yellowish colour and smooth aspect, contrasting strongly with the crimson

hue and corrugated surface of the lining membrane of the bladder (Plate XIII. Fig. 1.). The cavity was contracted, and corresponded with about two-thirds only of the organ removed. The upper third proves to be a sac opening by a very small orifice into the bladder proper; and an opening made into it gave exit to about an ounce of pus and mucus. The tumor springs from the prostate, which, though not enlarged towards the rectum, bulges into the urethra considerably, and also into the vesical cavity.

Both kidneys are diseased, and contain several small collections of pus, besides some ordinary cysts.

On cutting into the left side of the prostate (marked "left" in the drawing), the section of a rounded body embedded in the gland is seen. This body is four-tenths of an inch in diameter, is isolated from the surrounding tissues, separable from them in places with a blunt probe, but in others closely adherent, or united by prolongations of tissue common to both. It is lighter in colour and, apparently, denser in structure than the adjacent parts.

Several other bodies of a similar character are found, corresponding with the protuberances seen in the prostate before making sections of it. Three of the largest of these are dissected out (Plate XIII. Fig. 2 *a aa*.). The mucous membrane was first divided over them, and turned aside; then a few longitudinally disposed fibres, which in places peeled off from the rounded bodies like a capsule, but which at other points appeared to run into their substance, and to be continuous with it. One of these bodies, corresponding with a protuberance on the right side of the gland marked (A) in both drawings, is isolated in the preparation, and bands of fibres appear to unite it with the fibrous constituents of the gland behind. Small portions of tissue, detached from any part of the bodies of which section has been made, exhibit under the microscope the elements of white fibrous and organic muscular tissue closely packed in bands. Acetic acid develops a number of the rod-shaped nuclei lying longitudinally among the fibres. No yellow elastic fibres are found.

An isolated mass of the true glandular substance of the

DESCRIPTION OF PLATE XIII.

The figure illustrates Mr. Henry Thompson's case of Fibrous Tumor in the Prostate Gland and Sacculated Bladder. p. 253.

Fig. 1. Section through the bladder and prostate; "right" and "left" are added to their sides respectively, for the clearer understanding of the relative position of the parts.

A. Indicates a projection formed by one of the masses described below.

Fig. 2. The prostate dissected to show the rounded bodies embedded in hypertrophied fibrous tissue.

A. Indicates one of these bodies, corresponding with a protuberance on the right side of the gland, denoted in Fig. 1 by the same letter.

Two of the smaller ones are indicated by the letters *a a a*.

Fig 1

A

Right

Left

Fig 2

a

A

a

Right

Left

prostate gland may be seen in one of the sections,—that on the right side. It is obvious to the naked eye by exhibiting a yellower tint than the surrounding parts. Under the microscope it presents the ordinary glandular elements, as well as some of the minute "concretions" so called, often seen in the prostates of elderly people. None of these structures are found in the rounded bodies before described.

A large proportion of the bulk of the organ is made up of a whitish fibrous-looking tissue, which intervenes between masses of the gland structure, almost surrounding and isolating them. This tissue, which consists chiefly of the white fibrous tissue intermixed with organic muscular fibre, exists in the normal condition of the prostate gland in considerable quantity, but appears in some forms of the enlarged prostate to be unduly developed. The rounded bodies are made up of the same elements, and are more distinctly connected with this tissue than with the glandular parts, and may be, therefore, considered good examples of the ordinary fibrous tumors of the prostate. In this specimen some are embedded in the mass of the organ; others protrude beyond its periphery, into or towards the cavity of the bladder. They do not partake of the characters of the proper glandular structure, nor do they appear to have any close relations with it.

I may observe that in this, as well as in other specimens of enlarged prostate which I have examined, the increase in size, commonly designated hypertrophy, is due far more to the extraordinary development of the natural fibrous elements, than to that of the true glandular structure of the organ; although it is unquestionable that increase of the latter, particularly in the form of independent growths, is sometimes met with. A tendency to the increased production of the fibrous tissues seems, however, to be the common solution of the pathological state of enlarged prostate, whether it results in that form of aggregation which we call tumor, or in that condition more commonly met with, in which the entire fibrous structures of the organ are augmented to an unnatural extent.

Mr. Henry Thompson, *4th of December*, 1855.

---

7. *Intra-Glandular Tumor of the Prostate.*

On opening the bladder of a man, æt. 62, a nipple-shaped process was seen obstructing the internal opening. On dissecting out the prostate gland from its connexions, this substance appeared to be situated at so great a distance from the bulk of the organ, as to suggest that it was an outlying tumor, and not a direct outgrowth from the gland. It was situated fully an inch from the inter-lobular notch of the gland; but, on making a section, it proved to be connected with the median portion of the prostate, and to contain a portion of true gland tissue, isolated by a capsule, which gland tissue contained numerous examples of the so-called "concretions" almost universally found in adult prostates.

The weight of the organ is seven drachms, fifteen grains; about double that of the healthy gland. A fine section made by Valentin's knife exhibits the gland tissue, the enveloping capsule in section, ducts containing nuclei, and concretions embedded in its substance.

Mr. Henry Thompson, 6*th of May*, 1856.

---

8. *Villous Disease of the Bladder.*

A single woman, a milliner, æt. 34, died in the Middlesex Hospital in February, 1856. She had been an inmate of the Hospital during the previous twelve months under the care of Dr. Stewart. Three years before her death she was seized somewhat suddenly with pain in passing water: this was accompanied by some aching in the loins, and the urine was noticed to contain blood in large quantities. She recovered from this attack, but before her admission into the Hospital she had several others of various duration, which apparently yielded to the treatment employed, so that in the intervals between the attacks she was tolerably well, and able to follow her occupation. At length, however, these symptoms increasing in severity, the urine constantly containing a quantity of mucus, and frequently blood, she became an in-patient. During the first few months after her admission, there were frequent intervals during which

DESCRIPTION OF PLATE XIV.

The figures illustrate Mr. Sibley's case of Villous Cancer of the Bladder, p. 256.

Fig. 1. A group of villi from the chorion of an impregnated uterus at the twelfth week. Magnified 25 diameters.

Figs. 2 to 5 are from the case of villous disease of the bladder.

Fig. 2. The bifid extremity of a villous process.

Fig. 3. The extremity of a villous process. Many of the cells and interspaces are filled with oil globules.

Fig. 4. A pedunculated mass of villous growth; the villi sprouting out in club-shaped masses from the surface.

Figs. 2, 3, 4, magnified 250 diameters.

Fig. 5. The cells of which the villi are composed, obtained by tearing down a villous process with a needle. Magnified 350 diameters.

Fig 1

Fig 5

Fig 3

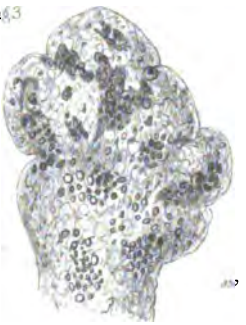

Fig 2

Fig 4.

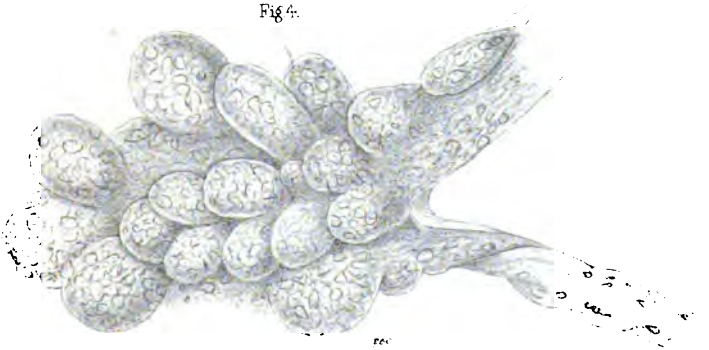

she was comparatively free from suffering. At length, four months before her death, the hæmorrhage from the bladder became almost constant; she began to lose flesh, and, after extreme suffering, she sank under the disease.

Post-mortem examination.—The coats of the bladder are much thickened, in some places being half an inch in thickness. The mucous membrane is of a dark slate colour, and, although thick, is slightly softer than natural. The bladder contains a villous growth of a bright red colour, and which, under water, presents the bulk of a goose's egg. This large growth is attached to the front of the bladder, two smaller but similar growths being situated one on each side of the larger one. In naked eye characters these growths bear great similarity to the chorion; and owing to their extreme delicacy of structure, they can only be properly seen when placed under water. The microscopical characters of these growths (Plate XIV.) are described at p. 214 of this volume.

The ureters are dilated. The kidneys are larger than natural, and contain numerous small abscesses in their cortical substances. These abscesses are arranged in a direction corresponding to the urinary tubes. The other organs of the body are healthy. Mr. SIBLEY, 19*th of February*, 1856.

---

9. *Calculus in the Female Bladder impeding Parturition, removed by operation.*

A woman, æt. 21, had suffered from infancy from irritability of the bladder, but not to an extent sufficient to require medical assistance. She married, and became pregnant. At her confinement the practitioner in attendance found a large tumor projecting into the anterior wall of the vagina, and impeding delivery to such an extent that it became necessary to open the head of the child.

On after examination this tumor proved to be a calculus in the bladder. A fortnight after delivery she was sent up to London, and placed under Mr. Erichsen's care.

At this time she was suffering extreme pain and irritation in the bladder, greatly increased by any examination. The

vagina was hot and tender, and the patient was unable to hold her water for more than half an hour at a time. She earnestly begged to be relieved of the stone.

In deliberating upon the mode of operation, it was considered that the stone was too large and the bladder too irritable to admit of lithotrity; that the size of the calculus would prevent its extraction through the urethra; and that the supra-pubis operation was too hazardous in the patient's enfeebled state. The vesico-vaginal operation, as being the simplest, was accordingly determined upon, and was performed on the 7th of November, just three weeks after confinement.

The calculus was readily extracted by the scoop. It was oval and flattened, weighed five ounces and a half, measured eight inches in its long, and six inches in its short circumference, and was one inch and five-eighths thick. It was composed of uric acid encircled by phosphates. The patient went on pretty well till the eighth day, when she rather suddenly died.

On examination it was found that the parts concerned in the operation were quite healthy; no inflammation about the vagina, bladder, or pelvis. The kidneys were found extensively diseased. The right one was converted into a cyst about the size of an orange, the whole of its secreting substance being absorbed; and the left one was studded with a number of abscesses; the calices and infundibula containing pus and being inflamed. The ureters were dilated to the size of the forefinger, and contained some phosphatic matters, and were crossed by bridle strictures at several points.

Mr. Erichsen, *20th of November*, 1855.

---

10. *Calculous Matter removed from a Boy, æt.* 10, *by the Operation of Lithotrity.*

H. S. a pale emaciated boy, æt. 10, who had suffered more or less from the symptoms of stone for a period of three years, was admitted into Hospital the 25th of September, 1855. He was peculiarly sensitive to pain. His urine was alkaline, but free from albumen. A stone, apparently of considerable size, was easily detected on sounding. A No. 8 instrument passed

readily, but not one of larger size. As it was determined to perform lithotrity, the urethra was gradually dilated by the passage of an instrument from day to day, until it easily admitted an instrument, No. 10, the size of the lithotrite selected.

12th of October. The operation of lithotrity was performed in the usual manner, and the stone was seized and crushed three times. Difficulty was experienced in passing the large curved portion of the lithotrite through the anterior part of the urethra, and a little bleeding from it ensued. As the opening of the prepuce was rather contracted, it was slit with a pair of scissors. The patient bore the operation badly, complaining much of pain. Fragments of stone passed next day, and three portions impacted in the navicular fossa of the urethra were removed by Mr. Corner, the House-Surgeon, with the scoop end of an ordinary director. In the course of the following week particles of stone passed with the urine, and two which lodged in the canal required removal.

19th. The lithotrite was again used, and the stone crushed. The instrument was passed with difficulty through the orifice of the urethra. Several minute portions were passed during the next few days, and one lodged in the middle of the spongy portion of the canal was extracted.

In consequence of the contraction at the orifice of the urethra and the pain experienced in the passage of the instrument, chloroform was given, and a smaller lithotrite (No 9.) was used in the next operation, which was performed on the 1st of November, and again on the 8th. Several fragments passed after these operations; and after the second, two portions becoming impacted in the urethra, chloroform was administered, and the stones extracted. The operation was followed by slight cystitis. Lithotrity, under chloroform, was repeated on the 22nd, and was followed by the passage of several fragments with the urine, and by the impaction of others, which were extracted from the urethra with some trouble.

6th of December. The patient was again operated on as before; and afterwards a catheter scoop was introduced into the bladder, and a considerable amount of detritus passed into it

with the rush of urine. This instrument was used three times in this operation; and on the last occasion, owing to the bladder being empty, the mucous membrane was caught between its blades. This was followed by slight bleeding, and symptoms of acute cystitis, which subsided under treatment in about two days.

In the afternoon of the 8th, a fragment lodged in the spongy portion of the urethra. Mr. Corner gave chloroform, and succeeded after some difficulty in extracting the stone. This, which was the largest piece removed from the bladder, appeared to be the nucleus of the calculus. No further fragments were passed.

The boy gradually regained his health. His urine became acid and natural, and on sounding him on three occasions at intervals, I could detect no stone. A slight stricture which existed in the spongy portion of the urethra, where most of the fragments lodged, readily yielded to dilatation, and the patient was discharged cured on the 22nd of January, this year.

The detritus which was collected weighed one hundred and forty grains; so that, making allowance for loss of particles entangled in the lithotrites and in the voiding of urine, we may estimate the original weight of the calculus at about three drachms. The boy was under treatment, dating from the first operation, and excluding the preparatory measures, three months; and the lithotrite was used six times. In the four last operations chloroform was exhibited. The detritus shows that the calculus was a mixed one, and consisted of oxalate of lime, lithate of ammonia, and the phosphates.

Mr. Blizard Curling, *4th of March*, 1856.

---

11. *A Lithic Acid Calculus, which was removed by Dilatation from the Bladder of a Lady, æt. about* 40.

This specimen measured, in its largest circumference, five inches; in its smallest, three inches and a half; and it weighed ten grains less than an ounce. No incontinence of urine had followed the operation. Dr. Crisp noticed another fact of

practical importance in connexion with this case, *viz.*:—that the patient's father had been subject to calculus.

Dr. Crisp, 15*th of April*, 1856.

---

12. *Abnormal Ureters from a Girl æt.* 10.

On the left side is a double ureter, one part of which issues from the upper, and the other from the lower end of the pelvis of the kidney. Each is rather less than the normal size, and unites with its fellow about an inch from the bladder, into which they open as one tube in the usual situation. On the right side, there is a normal, but undersized, ureter issuing from the lower end of the renal pelvis and opening singly into the bladder as usual.* At the upper end of the kidney is a cyst-like cavity of about the size of a walnut, with tough fibrous walls, and distinguished externally from the normal kidney-structure by a slight constriction. A thin layer of the cortical substance may, however, be traced some way over its walls. The interior is lined by a smooth membrane, and has no communication with the true pelvis of the kidney, but here and there are seen several saccular depressions like remains of calyces. Issuing from it is a fibrous tube or duct, of the average diameter of a large goose-quill, sacculated in some parts with slight alternating constrictions. Its cavity freely communicates with that of the cyst, and is lined by a villous-looking membrane arranged in longitudinal folds. Passing towards the bladder, parallel, and internal to the normal ureter, and invested by a similar sheath of sub-peritoneal fascia, this tube opens into the bladder close to the exit of the urethra by the side of the uvula vesicæ. Towards the lower end are two or three distinct valvular arrangements of the lining membrane, strengthened by fibrous tissue, and disposed so as to resist upward flow. The largest and most distinct of these is

* On further examination of this case, I find that in the healthy kidney also, the pelvis is represented by two distinct mucous cavities, each of which is continued into its corresponding division of the ureter, and which are separated from each other by a large pyramid of the tubular structure. This arrangement supports the inference drawn from the appearances in the *cyst* of the opposite kidney as to the origin of the abnormality.

about an inch and a half from the lower end; a large saccular dilatation intervening. The opening into the neck of the bladder is small, and guarded also by a valve.

The cyst seems to have been a secluded part of the renal cavity, the secreting substance of which has become atrophied by pressure of its contents, and the tube to have been an aberrant ureter, with a provision against regurgitation, to which, from the position of its entrance into the bladder, it has been usually subject. The result shows that this provision, however, has been ineffectual in preventing atrophy.

Mr. JOHN WOOD, 19*th of February*, 1856.

---

13. *Stricture of the Ureter, with Extensive Absorption and Dilatation of the Kidney.*

A man was admitted into St. George's Hospital with fracture of the lower articulating extremity of the tibia. The case was involved in much obscurity, as the fracture could not be accurately distinguished. He had been enabled to walk until the ninth day after the accident, when shivering came on, followed by much constitutional excitement, and he died. The day previous to his death, he for the first time felt an inability to void his urine, which was drawn off by a catheter. On examination of the body after death, it was discovered that one of the kidneys had become extensively dilated, its cortical and tubular portion entirely absorbed, with the exception of the fibrous septa intervening between the separate lobules of this organ, which gave rise to the appearance of separate cysts, all of which communicate directly or indirectly with the pelvis, which is also greatly dilated.

On attempting to pass a probe down the ureter, it was found to be almost impervious just where it joins the pelvis, hardly admitting the passage of a bristle. The opposite kidney and the bladder were quite healthy. The fracture was found not to extend into the joint, and no pus had formed in the articular cavity.

This specimen was presented to the Museum of St. George's Hospital by Sir Benjamin Brodie.

Mr. HENRY GRAY, 6*th of May*, 1856.

14. *Impacted Calculus with Sacculated Kidney.*

Dr. Peacock exhibited a specimen of impacted calculus with sacculated kidney, removed from a patient of his, a female, æt. 20, who died of phthisis, of upwards of three years duration, at the Hospital for Diseases of the Chest, Victoria Park. The patient was admitted into the Hospital on the 2nd of November, and then presented evidences of extensive disease with cavities in the left lung. After having resided in the Hospital for about three weeks, she began to improve, and advanced steadily, gaining six pounds in weight in nine weeks, till the 30th of January, when she was suddenly seized with symptoms of pneumonia, and died in twenty-eight hours.

On examination after death, the condition of the lungs corresponded with the opinion formed during life. The left lung contained large cavities, lined by false membrane and undergoing contraction, together with the cicatrices of healed cavities. There was also a small cavity in the apex of the left lung, and interspersed tubercle in other parts. At the lower part of the left lung, there was slight red hepatization and very extensive pneumonic consolidation of the lower part of the right; in each case lapsing above into simple engorgement. There was no intestinal or other disease. The left kidney was found to be converted into a large multilocular sac; the parietes of some of the sacculi being entirely membranous and very thin, and the renal structure being everywhere almost entirely atrophied. The cause of this expansion of the pelvis and calyces of the kidney was found to exist in a calculus which was impacted in the pelvis, and must have apparently nearly, if not quite, closed the entrance into the ureter. The calculus presented the usual dark colour and scabrous surface of the oxalate of lime deposits. It consisted of a body and three projecting extremities which protruded into the expanded calyces. At the end of one of these projections there was a small mass of phosphatic deposit. It weighed one drachm and three-quarters avoirdupois when dried. The sacculi of the kidney were distended with a dark-coloured thin fluid. The ureter was throughout pervious. The right kidney was large and vascular, weighing six ounces and

a half avoirdupois. The existence of the disease in the kidney had not been suspected during life; but, on inquiry afterwards, it was ascertained that the patient had occasionally complained of pain in the left iliac region, extending down to the groin. Five years before she had an abscess in the left groin, which was opened, and soon healed. The urine was examined soon after her admission into the Hospital, and was found to be quite healthy. Dr. PEACOCK, 18*th of February*, 1856.

---

15. *Specimen of a Single Kidney found in the body, of a horse-shoe shape.*

The kidney weighed twenty ounces. It was placed across the lower lumbar vertebræ; the lower and convex margin being opposite the brim of the pelvis. It had two ureters, and three arterial branches were supplied to it which were given off spontaneously from the aorta. No indication was seen on section that it had been originally formed by the fusion of two distinct kidneys. The pelves, with which the ureters were connected, did not communicate. The structure of this kidney was diseased. Its cortical portion was thinned, and its surface very highly granular, the capsule being adherent.

It was removed by Dr. Ogle from the body of a patient of Dr. B. Jones, in St. George's Hospital, æt. 56, who was admitted in May, 1854, with bronchitis, dropsy, and albuminuria, having been ill for four months, and having had anasarca of the legs for one week only. The specific gravity of the urine varied from 1015 to 1010.

He went out of the Hospital relieved, and was readmitted in in January, 1856, with dyspnœa, palpitation, and general dropsy. The specific gravity of the urine was 1024, and it contained much albumen and a few casts.

A diminution in the amount of urine secreted took place and drowsiness came on. He was treated by purgatives, vapour baths, and diuretics. He died comatose February 17th. Case related by Dr. John Ogle.

Dr. B. JONES, 19*th of February*, 1856.

---

16. *Atrophied Kidneys.*

Specimen B.—The right kidney was exhibited from a female patient æt. 47, who died in the Somerset Asylum, under Dr. Boyd's care, in a state of acute mania of one year's duration.

Post-mortem examination showed pneumonia in its second stage, and fluid in the brain and spinal canal from chronic arachnitis. The kidney presented to the Society was considerably atrophied, weighed only one ounce, while the corresponding one weighed eight ounces and a half. The normal structure of the gland appeared quite wasted, and numerous sharp spicula of calculi occupied its structure; a fluid, which under the microscope showed crystals of cholesterine, filled a cavity the size of a bean.

Specimen A.—The second kidney presented was also from a patient in the same institution, æt. 44, who died after twenty-four hours' illness from inflammation of the pulmonary organs. No disease of the urinary organs was observed during life.

The *post-mortem* revealed extensive deposit of recent lymph on the pleura and pneumonia in its third stage. The dura mater adhered to the skull; the cerebral ventricles and spinal canal were filled with fluid. The right kidney weighed three ounces and a half, and, with the ureter, was filled with a putty-like, yellowish, thick fluid. Mr. Obre, *4th of March*, 1856.

Report on these Specimens. — *Specimen* B. — The kidney is considerably smaller than natural; its substance is in great measure destroyed, and occupied by cavities which vary from an inch to half an inch in diameter. The cavities are completely filled with an opaque white material, which is of uniform character throughout, being soft, and like fine moistened plaster of Paris. Under the microscope this material consists of granules, disintegrated cells, and some cholesterine. The granules are exceedingly numerous, varying in size, but for the most part globular and exceedingly minute. The cells are about the size of pus corpuscles; they are irregular in shape, generally broken or deficient in one part of their circumference, and containing

in their interior more or less granular matter. The amount of cholesterine varies in different parts, but it presents its usual characters.

Hydrochloric acid, without causing the entire disappearance of any visible element, renders everything in the field more transparent, and gives rise to the escape of bubbles of gas. Sulphuric æther apparently dissolves some portion of the material. Hence this soft substance is composed of a considerable amount of earthy material, and a moderate quantity of oily matter, the remainder being, probably, albuminous.

This substance appears to us to be the remains of some remotely formed product of disease, and that this was either tubercle or pus.

Specimen A.—This kidney is very much reduced in size, measuring only about two inches in length. On section it is impossible to distinguish any of the normal structures, there being no distinction of medullary and cortical substance, and no appearance of the prolongations of the pelvis. The part which from its position appears to have been the secreting structure of the organ, presents several cysts from the size of a marble downwards. The largest one has a tolerably smooth lining membrane, and its wall is studded with irregular plates of earthy matter, some of which project from it, and become easily detached. Two or three of these cysts have their parietes completely converted into hollow spheres of earthy material. The thickness of these ossified walls varies from about a line downwards. Their outer surface is tuberculated and intimately connected with the surrounding soft textures: the inner surface is tolerably smooth. The portion of ureter left attached to the kidney is pervious; but the pelvis is found to be completely filled by a calculus about as large as a horse bean. The exterior of the calculus is rough, and is connected with a quantity of sabulous matter deposited on the mucous surface. The mucous membrane of the pelvis appears to have contracted closely around the calculus, so that its cavity is obliterated. The infundibula and calyces are not recognizable. Under the microscope, the cortex of the kidneys is found to present

blood-vessels, and the remains of Malpighian bodies and tubes. The blood-vessels are disproportionally large and numerous, which is most probably due to atrophy of the intervening structures, including the capillaries connected with them, causing the larger vessels to approach one another. The Malpighian bodies are reduced in size, have thick capsules, and their included capillary tufts are indistinct; here and there tubes are visible, and, in some parts, rows of small microscopic cysts connected with them. The parietes of the cysts consist of a dense fibroid material and of earthy deposit in various proportions. The earthy deposit exists under various forms, which probably represent different stages in its formation.

1. It exhibits, in many parts, minute granules and globules, which present, to transmitted light, a black opaque appearance.

2. In other places these have coalesced so as to form transparent refractive masses of irregular shape.

3. In many places the earthy deposit presents numerous and distinct lacunæ, with canaliculi as in healthy bone; but we do not detect the existence either of Haversian canals or of concentric lamellæ.

The chief interest in this specimen, we think, lies in the ossification of the parietes of cysts in the kidney.

The explanation of the appearances presented by this specimen is probably the following:—

A calculus was formed and became impacted at the commencement of the ureter. To this succeeded dilatation of the pelvis, but chiefly of the infundibula and calyces, as usually occurs in such cases. The secreting structure having been at length destroyed by the long-continued and increasing pressure of the fluid excreted into the cavity of the organ, the dilatation ceased, and to this succeeded those changes which slowly brought about the condition of organ above described, *viz.:* the contraction of the dilated pelvis around the calculus so as to completely obliterate its cavity, and the contraction also of the dilated calyces and the alteration in their lining membrane, in virtue of which they become converted into bony cysts.

Dr. Bristowe and Mr. Gray, 18*th of March*, 1856.

17. *Large Cancerous Growth of the Kidney in a Child.*

This enormous growth of the kidney, weighing thirty-one pounds, occurred in a boy, æt. 8, who was admitted into the Middlesex Hospital about a twelvemonth ago, under the care of Dr. Hawkins, who has kindly permitted me to bring the case before the Society.

The history of the case is briefly as follows:—the child's abdomen, soon after birth, became rather larger than natural; it continued to increase in size very gradually until six months before he was admitted into the Hospital, but it grew very rapidly afterwards. On admission, the abdomen was much enlarged and crossed by large tortuous veins; the enlargement existed especially on the left side, and was produced by a tumor about six inches in diameter; it was slightly moveable, semi-elastic in some parts, and not painful on being handled; the intestines were felt over the edge of it on the right side. Four months after admission it is noted that the child walked down to the garden, but felt so ill that he was carried back. He occasionally complained of great pain in the abdomen. The tumor gradually increased so much in size, that he was soon unable to leave his bed; but he lingered on for months. His appetite was generally good, and the bowels regular; but he became gradually very thin, and died from exhaustion about ten months after admission.

Post-mortem examination.—A photographic portrait of the boy (which is represented in outline at Fig. 1. Plate XV.) was taken after death, by my friend Mr. Heisch, and it gives a good idea of the size of the tumor. The left leg was œdematous; the superficial abdominal veins were much enlarged. On opening the abdomen, the parietes were found to adhere to the enormous tumor which filled this cavity; the adhesions were firm and extended over the greater part of the tumor. The abdominal viscera were much displaced, the liver, spleen, and stomach, were pushed upwards into the thorax, the lower ribs on both sides being much raised and expanded. The sigmoid flexure of the colon crossed in front of the tumor, and was adherent to it, but there was no obstruction to the passage of fæcal matters.

DESCRIPTION OF PLATE XV.

Figures 1 to 6 illustrate Dr. Van der Byl's case of Cancerous Growth of the Kidney in a child, weighing One Hundred and Thirty-one pounds, p. 268.

Fig. 1. Outline sketch taken from a photographic portrait of the child, obtained after death. It shows the enormous size of the growth, the enlarged veins crossing it, the œdema of the left leg, &c.

Fig. 2. Juice obtained from the cut surface, near the centre of the growth, where it presented a gelatinous yellowish appearance; large cells containing granules, smaller cells and fibre-cells are seen.

Fig. 3. Juice from a projection at the upper part of the tumor, viscid and semi-transparent; it contained large cells with several nuclei, caudate cells, &c. Treated with acetic acid the cells became more transparent and the large nuclei are distinctly seen.

Fig. 4. Juice obtained from flattened glandular masses situated on the outside of the tumor.

Fig. 5. Broken-up, sloughing portion from the centre of the tumor.

Fig. 6. Dark grumous fluid contained within the tumor, consisting of deformed blood-corpuscles, oil-globules, &c.

Figures 7 and 8 illustrates Mr. R. Taylor's observations on the Structural Changes of the Lens in Cataract, p. 330.

Fig. 7. Fibres from the superficies of a healthy lens.

Fig. 8. Cells from the cortical layer of the lens in cataract, variously altered.

Figures 9 and 10 illustrate Dr. Bristowe's report on Mr. B. Child's case of Tumor of the Femur, p. 361.

Fig. 9. Fibroid tissue from the tumor, magnified 220 diameters.

Fig. 10. Varieties of myeloid cells, magnified 420 diameters.

Figures 11 to 14 illustrate Dr. Bristowe's report on Mr. Simon's case of Tumor of the Humerus, p. 351.

Fig. 11. Fibroid network, magnified 220 diameters.

Fig. 12. Tissue in process of degeneration.

Fig. 13. Varieties of myeloid cells.
These two figures enlarged 420 diameters.

Fig. 14. Diseased muscular fibre, magnified 220 diameters.

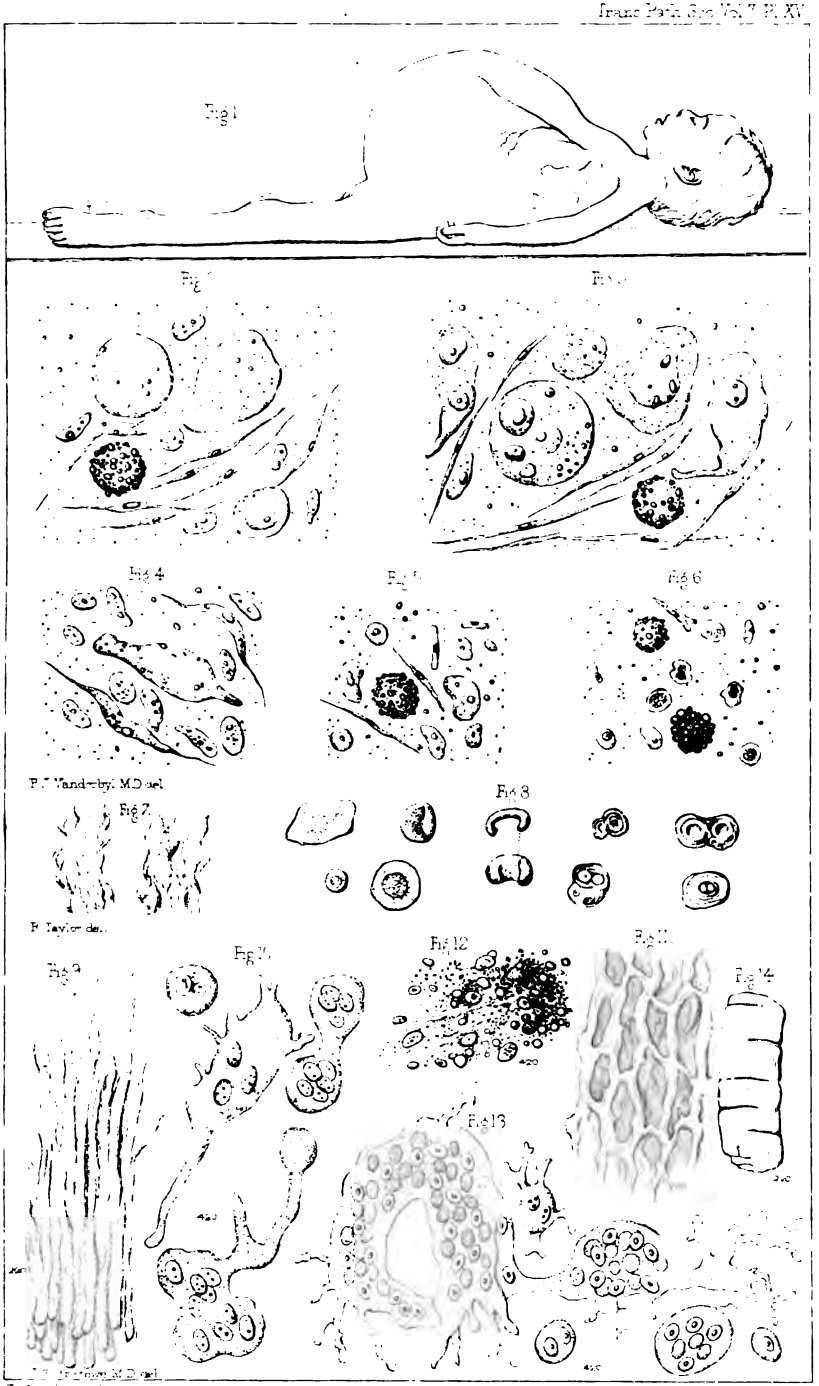

Tuffen West sculp.

The anterior aspect of the tumor was found to consist of the concave portion of the left kidney, which was enormously enlarged; the renal pelvis was directed forwards and outwards, and measured seven inches in length, and five inches in breadth, but although so much enlarged, was not much altered in appearance. The ureter was of the natural size, and yielded some clear urine when pressure was made over the distended pelvis. A soft mass, the size of an egg, protruded from the lower part of the renal pelvis, but the kidney-tissue surrounding the pelvis appeared tolerably sound, and, in a vertical direction, measured twelve inches.

Beyond the limits of the healthy renal tissue, the kidney substance seemed converted into a thick fibrous layer which quite surrounded the growth. The entire growth, when removed, weighed thirty-one pounds, and measured thirty-two inches in circumference transversely, and thirty-six inches in circumference vertically. It was closely covered by peritoneum, and on the anterior and upper part of the tumor were several flattened masses of somewhat rounded outline; but these were easily separated from the main growth, and were probably only enlarged glands. On section, about eight pints of a dark, grumous, viscid fluid escaped, containing numerous yellowish, shreddy, sloughing masses. About one-third of the tumor being removed by a vertical cut, made so as to leave the pelvis entire, the exposed surface presented anteriorly, near the pelvis, a margin of renal tissue, about one-third of an inch thick, and this could be traced all round the tumor, but the true kidney-tissue gradually became converted into a fibrous layer at about four or five inches distance from the pelvis. The interior of the tumor presented a soft, gelatinous, medullary substance of a yellowish colour, with some patches of semi-transparent material; and it was traversed by fibrous bands. Some portions were hanging in shreds and sloughs in all directions; but the breaking up seemed furthest advanced at the part most distant from the pelvis, where it had, indeed, reached the distended fibrous layer which bounded the growth. At the upper part of the tumor was a protuberance apparently in the early stage; it presented a semi-transparent, somewhat

gelatinous, pale yellowish, medullary appearance, and was evidently of recent origin. The right kidney weighed seven ounces, but exhibited no trace of the disease; it was rather pale and flabby. The other viscera were all free from cancer and tolerably healthy.

Microscopical examination.—The juice taken from different parts of the tumor exhibited large cells containing from one to three nuclei, spindle-shaped cells, &c. (*See* Plate XV. Fig. 2, and the accompanying description).

Dr. Van der Byl, *6th of May*, 1856.

---

18. *Diseased Supra-renal Bodies.*

The patient, a man, æt. 28, had died in Purton Workhouse, almost immediately after admission, and apparently in consequence of exhaustion induced by a short journey. He was fat and muscular. During his illness he had not been under observation until within three days of his death. On the *post-mortem* table all the bystanders were struck with the remarkable brownness of the skin. Both supra-renal capsules were found completely atrophied and reduced to fibroid tissue, in the middle of which were some calcareous concretions. *No trace of healthy structure was discoverable.* The case seemed fully to bear out the views of Dr. Addison in respect to the connexion between destructive disease of the supra-renal capsules and bronzing of the skin.

Mr. Hutchinson for Mr. Bakewell, *6th of January*, 1856.

Dr. Wilks' report on this specimen.—The organs are shrunken and smaller than healthy ones. About half of their substance is occupied by cretaceous material; this being deposited principally as a large mass in each organ. The softer parts consist of fibrous tissue and fat. No particular structure could be made out, the most important fact being, that no trace of healthy tissue could be discoverable in any part.

Dr. Wilks, *15th of January*, 1856.

---

19. *Procidentia Uteri of Large Size.*

The diseased mass, which was taken from the body of a female, æt. 70, who had died from the effects of the essential oil of almonds, swallowed either by accident or design, must, from its size, as well as thickened and corrugated structure, have been of long duration, and irreducible. It formed a large pyriform tumor, depending from the vulva seven or eight inches between the thighs; the inverted vagina being converted into a dense tegumentary structure, and forming a complete bag, into which, as seen from the pelvis, the uterus, Fallopian tubes, ovaries, and greater portion of the bladder, entered, a small part only of the latter viscus being visible.

Upon handling the tumor, and pressing it upwards towards the vulva, several ounces of fluid passed into the pelvic cavity; whilst some urine passed through the meatus. The course of the urethral canal was altered, and a catheter had to be directed downwards and backwards to reach the bladder. The os uteri was completely invested by the dense structure once a portion of the vagina, and could only be reached by cutting through the sac at its most depending part, where a small puckering indicated its situation.

Mr. Potts, *6th of November*, 1855.

---

20. *Congenital Absence of the Uterus and its Appendages.*

This preparation was taken from a woman, æt. 33, who died of anæmia in the Sussex County Hospital. She had always had delicate health, and looked pale. She had never menstruated, but had been liable to hæmorrhage from the nose at tolerably regular intervals. During the last two years of her life these hæmorrhages had been of more regular monthly recurrence, and within the few months preceding her death, most unequivocally so. Till within the last few months of her life she had never been known to express any doubts about her being regularly formed like other women. She had appeared to have the usual feelings of her sex, for she was engaged to be married,

and it was only the distant residence and indifferent means of the object of her affections, which had prevented their being married some years before.

At the usual age of puberty her form underwent all the normal changes. The breasts were well-developed: the diameter of the pelvis, from one anterior superior spinous process to the other, was eleven inches and a half; the width, from one acromion to the other, fourteen inches; being full womanly proportions for her height of five feet and a half.

On examination of the body the skull was found singularly thin; the arachnoid was adherent in some points about the under surface of the middle cerebral lobes, and there were very numerous and firm old filamentous adhesions about the base. A few tubercles were seen in the neighbourhood of the arachnoid adhesions.

The brain altogether, that is the cerebrum, cerebellum, pons, and medulla, weighed eighteen thousand eight hundred and sixty grains. The cerebellum, by itself, weighed one thousand four hundred grains, the proportion between the two being as thirteen to one about, the cerebellum being also to the eye below the normal size.

One or two tubercles were found in the liver and spleen, and a few in the lungs, and a cicatrix of an old ulcer in the ileum. The blood showed fewer of the ordinary blood discs than usual, but there was no increase of the white cells. No recent changes were found sufficient to explain the cause of her death at this particular period.

No trace of the uterus could be found in its ordinary position. The peritoneum passed at once smoothly, without interruption, from the back of the bladder to the rectum. There was no appearance of thickening, nor results of old inflammation hereabouts.

On removing the parts and instituting the most careful examination, no trace of the uterus and its appendages could be discovered, only a crescentic fold near the end of the vagina suggested the idea that this might be a rudimentary os uteri. No appearance of the ovaries could be found; a small mass, apparently of a glandular structure, was noticed in the left wall

of the vagina, with which, rather than with the uterus, its position seemed to connect it.

The vagina itself was a *cul de sac*, capable of admitting little more than the last joint of the forefinger. It was raised in folds like the parts in their normal condition. But everything was on the minutest scale, and the most prominent object was the orifice of the urethra, which was exactly one inch distant from the closed extremity of the *cul de sac*.

As the preparation has been put up, the resemblance to an os and cervix uteri is much more apparent than it was in the recent specimen.

Dr. QUAIN for Dr. ORMEROD, *4th of December*, 1855.

---

21. *Ovarian Tumor weighing one-hundred and six pounds. Great Elongation of the Cervix Uteri and Vagina.*

A. H. a single woman, æt. 31, whose general health had been good, has had an ovarian tumor seven years, especially appreciable four years ago. It did not engage much of her attention till within the last two years, when, gradually increasing in size, it became so inconvenient that she sought for relief in the Hospital for Women in Soho Square, then in St. Mary's Hospital, and finally became a patient at the St. Pancras Royal Dispensary, under the care of my colleague, Dr. Smiles. She attributed the origin of the tumor to a strain when lifting a heavy weight seven years ago. Latterly its dimensions were enormous, being accompanied with general anasarca during the last five months. Notwithstanding its inconvenient bulk and an œdematous condition of the limbs, she continued moving about to within a fortnight of her death, when she became bedridden and utterly helpless, and died on the 28th of November.

Autopsy twenty-seven hours after death.—The entire body much swelled from infiltration of serum, with the exception of the arms and face, which were emaciated. The body lay on its left side, the weight and size of the tumor having completely prevented dorsal decubitus. Rigor mortis complete.

On turning the body over on its back, and supporting the

abdominal tumor, it presented a remarkable appearance from its very great prominence; it uniformly projected from the entire abdominal cavity, but produced at the same time, deformity of the thorax, the lower and anterior part of which was tilted forwards. The measurement of the tumor externally, from the ensiform cartilage to the pubes, was thirty-five inches and a half; and the girth of the body and tumor together round the loins, fifty-four inches. A slough was present over the left trochanter, the decubitus being confined to that side during life.

The abdominal walls were much infiltrated with serum, which oozed out on cutting through them to reach the mesian line of the tumor. The tumor was adherent to the peritoneum in various parts laterally and anteriorly. These adhesions could be broken down with tolerable facility, however, as they partook of the character of condensed areolar tissue. They were more persistent anteriorly, requiring careful dissection to detach the tumor at this part; posteriorly and inferiorly strong bands of cellular tissue had to be cut through to isolate the mass. At the margins of the pelvis these were very thick and strong, and acted as supports; but on division the tumor became free. All the viscera were displaced upwards, the stomach and greater part of the bowels occupying a portion of the left side of the thorax; the liver was dislocated towards the left side, and occupied a central position beneath the heart; it was very small in size, of a dark green colour externally, extending but a couple of lines into its substance, which was apparently quite healthy. On chemical examination I found it to contain no sugar. The gall bladder was very much distended, partly with gas, partly with bile. The stomach, from long compression, was somewhat contracted in size, and constricted at its middle portion, giving it a bilobular form. The intestines were natural as far as the descending colon and rectum, which were diminished in calibre into a tube about three-quarters of an inch in diameter. The sigmoid flexure was obliterated; but the rectum pursued its usual course, and passed under the base of the tumor, a portion of which nearly filled the pelvis. The cæcum was adherent superiorly to the apex of the tumor, apparently

from old inflammation. The kidneys were quite loose, the left more so than the right. Both ureters were slightly embedded in the substance of the tumor on either side laterally, and much dilated and filled with urine, as was seen in the specimen, the right kidney being at the same time allowed to remain attached to it. The spleen was enlarged to double its size, and quite healthy. The bladder is seen at the lower part of the tumor anteriorly, but flattened upon it, and contains several ounces of urine.

The left side of the chest held about two pints of serum. The lung here was completely collapsed, did not crepitate in the slightest degree, and was in a state of carnification, resembling the spleen in colour. It had not performed its function, most probably, for some months preceding death. The right lung was small, entirely adherent to the pleura, crepitated everywhere, was healthy in structure, its posterior and left aspects engorged from hypostatic congestion; and at its apex it was slightly affected with interlobular emphysema. The heart was very small indeed, but normal in every respect, excepting a fatty degeneration of its tissues. It was situated beneath the upper bone of the sternum, and encroached on the right side.

The outlet of the thorax was very much expanded to meet the pressure of this enormous tumor; and the crests of both ilii were expanded outwards to assist in its support, measuring from one anterior superior spinous process to the other, eleven inches and a half.

The tumor was finally removed by placing a ligature around its pedicle, which included the rectum, vagina, and urethra, all of which were shown in the specimen. The tumor itself weighs one hundred and six pounds, and appears to have involved the left ovary, as the right ovary, much flattened and its Fallopian tube may be distinctly seen on its left aspect, the enlarged left ovary having passed behind and to the right of the uterus, which lies completely on the anterior part of the tumor towards its left side, having been dragged into this position by means of its ligament, which has become incorporated into the tumor. Its cervix is considerably elongated, to the extent of several inches, as is also the vagina; and its left Fallopian tube is

stretched out and spread over a large portion of the left side of the tumor. The enlarged left ovary consists apparently of two tumors firmly joined together, containing fluid, a description of its contents and dissection being deferred until after its exhibition in its natural state before the Society.

This tumor is most probably the largest ever removed entire from the dead body. Larger tumors have undoubtedly existed, and as many as one hundred and twenty, and even one hundred and forty pounds of liquid are recorded to have been withdrawn from one sac. My friend, Mr. Baker Brown states, in his work on "Diseases of Women," that he has withdrawn ninety-three pints of fluid at one tapping. This is equivalent by weight to a hundred and sixteen pounds.

As might be expected from the enlargement of the tumor, the greater part of the abdominal viscera, together with the diaphragm, were pushed into the thorax; the left side especially, as pleuritic adhesions in the right prevented it in that side—and the left lung completely lost its function. From the interference thus caused to the performance of the most ordinary functions of life, universal emaciation was produced, which eventually ended in dissolution. Dr. GIBB, *4th of December*, 1855.

Report on this Specimen.—The large tumor consists, as regards its bulk, almost entirely of a diseased mass originating in the left ovary. In its general outline it is nearly circular, but a small portion of it at the lower part having been situated in the pelvis, and this portion being much smaller than the mass above, the whole may be said to have a slightly pyriform appearance.

An idea of the enormous size of the tumor may be obtained from the fact of its weight being one hundred and six pounds, and from the following being its measurement :—

Circumference, vertically, over side and top .	68 in.
Do. do. do. not including the pelvic portion	63 „
Do. vertically, over anterior and posterior surfaces	55 „

Diameter, vertically	22½ in.
Do. transversely	20 „
Do. antero-posteriorly	10½ „

The whole tumor is one continuous mass; but as viewed *anteriorly*, it is divided into two portions, of nearly equal size, by a distinct sulcus running nearly vertically at its upper two thirds, and then inclining outwards and to the right, to the point where the abdominal and pelvic parts of the tumor unite. These portions may be termed right and left. The right portion is very firm and resisting; its surface is somewhat uneven from various slight elevations, none of which are larger in diameter than a walnut, and none of which project more than very slightly (the one-sixteenth to one-eighth of an inch) above the general level. Its colour varies much in different parts, some patches being red or purplish, others of a yellowish grey. Many large vessels ramify over its surface. The left portion is longer vertically than the right one, as it includes the pelvic part of the tumor. Fluctuation is distinctly felt at every part of it, but its parietes can be felt to be much thicker superiorly than inferiorly; and they are thinnest of all at the pelvic part; its surface is almost perfectly smooth, is of a more uniform light colour than the right portion, and is much less vascular than it.

On examining the posterior surface of the tumor, the same general division into a right or solid, and left or fluctuating portion is observable; but the solid portion is less transversely in proportion to the fluctuating portion, than it is anteriorly; and it is now found that the left or fluctuating section is a huge cyst, which originates, as it were, from the side and posterior part of the right or solid part. The solid mass is singularly reflected from the anterior part over the top of the tumor, thus forming a kind of cap for the top of the large cyst; and this cap is so continued downwards behind the upper part of the cyst, as to form a flap of a triangular shape, the dependent portion of which can readily be dissected off, so as to leave it only attached by its base at the very top of the cyst. The triangular flap measures at its base and each of its sides, just eight inches; at its base, where it covers the top of the cyst,

it is one inch and a half in thickness; at its dependent point, only one-quarter of an inch thick. The whole of the posterior surface of the tumor is more congested than the anterior, but here (as was the case anteriorly) the solid portion of the mass is somewhat more uneven on its surface than is the cyst portion.

The large cyst, consisting of what has been termed the left portion of the tumor, and the whole of the pelvic part, is found to contain a nearly homogeneous puriform fluid, containing, however, a few small flaky masses. The quantity amounted to forty-four pints.

Besides this large cyst, only three or four other small ones are found embedded in the solid part of the tumor. The largest of these contain about two drachms of a yellowish-red serous looking fluid. None of them appear to be proliferous.

The pelvic part of the tumor (the walls of which were thinner than those of any other part of the cyst) appears to have almost completely filled the cavity in which it was situated. The rectum is found to be pushed very much to the left of its natural position; it is united by moderately firm adhesions to the ovarian tumor. The bladder is more firmly adherent, but is situated considerably to the right of the median line.

The most singular alterations, however, both in form and position, are those which have occurred to the organs of generation, all of which are very firmly adherent to the tumor. The vagina is considerably elongated, and measures six inches and a half in length. It inclines very much towards the left side, and at its extremity no cervix uteri is perceptible, but only a small aperture, which is found to lead into the cavity of the uterus. The organ is, like the vagina, firmly adherent to the anterior surface of the tumor, and, like it, is exceedingly elongated, so that it measures seven inches and a half in length. The elongation is almost entirely due to the stretching of the cervix. Owing to this elongation and its inclination towards the left, its fundus is placed not far from the left border of the tumor, at somewhat more than one third of the distance from its base. The fundus uteri itself presents a very remarkable appearance; its right half or cornu is a small oval-shaped prominent mass on the surface of the large tumor, and not at all

unlike an enlarged ovary. Its left half is thinned, flattened, and elongated, and so much incorporated with the substance of the tumor as not to be, at first sight, recognised. From the extremity of this half of the uterus comes off the left Fallopian tube, enormously elongated, and expanded over a large extent of the tumor, which itself is, as already stated, the left ovary in a diseased condition. This left Fallopian tube measures twelve inches in length. The right Fallopian tube appears, owing to the elongation of this organ, to arise from the middle of the right side of the uterus. The right ovary is much flattened, so as to be only one-eighth of an inch in thickness, though in other dissections it measures two inches and a half by one inch and three-quarters.

The tumor (after the cyst has been emptied of its contents) when laid flat on the table, has a thickness, at its thickest part, of four inches and a quarter.

On microscopical examination of the substance of the tumor, the difference in the colour of its different parts is found to be almost exclusively due to differences in vascularity. Some of the paler portions contain comparatively few blood-vessels, while in some of the reddest parts the vascularity is extreme. The substance itself is composed of fibro-cellular tissue, with here and there minute cysts invisible to the naked eye, and formed, apparently, by the separation of the fibres from each other.

Subsequently to exhibiting the specimen to the Society, Dr. Gibb made a careful examination of the fluids, of which the following is the account:—

Pus.—The large cyst contained forty-four pints of yellowish-green watery pus, with a slightly fœtid odour; it was alkaline; specific gravity 1018; it contained sugar and albumen, the latter to the amount of 10 per cent. Under the microscope were seen broken up pus-corpuscles, granular matter, scales, and patches of epithelial membrane, compound granular corpuscles, and fat globules and crystals. The weight of the forty-four pints is fifty-five pounds, thus leaving the weight of the solid parts of the tumor to be fifty-one pounds.

Serum.—The amount did not exceed a couple of drachms, of a clear reddish colour, from slight admixture with blood, taken

from the small cyst. It was alkaline; heat and nitric acid threw down albumen. No sugar present. The microscope showed blood and fat-globules, transparent granular matter, with occasional long slender plates of cholesterine.

Urine.—The bladder contained several ounces of a muddy, opaque, fawnish-brown urine, slightly fœtid, neutral, specific gravity 1028. On standing some hours it became a clear dark yellow, and a heavy fawnish pink deposit subsided, which was partly soluble by heat. Heat and nitric acid both threw down a slight deposit of albumen, and partly dissolved the pinkish deposit. A mere trace of sugar was detected.

The microscope showed myriads of spherical bodies of urate of ammonia, formed from long standing of the urine in the bladder; occasional crystals of urate of soda, and large numbers of lozenge-shaped crystals of uric acid, in clusters and free, together with a few broken up mucous globules, and monads in abundance. The spherical bodies of urate of ammonia, when examined by reflected light, with a power of forty diameters, presented a light fawn colour. They were dark, but not black, by transmitted light. They were unaffected by heat or liquor ammoniæ; acetic acid dissolved a large proportion of them, and converted others from a round to a square form, taking the place of the uric acid, which, on becoming free, formed its characteristic crystal. Boiling alcohol dissolved one-half the bulk, and a portion was soluble in liquor sodæ. The lozenge shaped crystals of uric acid were completely dissolved by heat and liquor sodæ, and partly so by hydrochloric acid. The entire deposit was soluble in liquor potassæ.

Dr. HARE, *15th of December*, 1856.

---

22. *Multilocular Ovarian Tumor, with Intra-cystic Growths covered with Ciliated Epithelium.*

M. L. æt. 33, a patient of Dr. Gull's, admitted into Guy's Hospital, on the 12th of December, 1855. She was a married woman with a family; her last child was born dead fourteen months before. Previous to this time she had experienced some pain in the left iliac region, but at her confinement the pain

much increased and then she perceived a swelling in the part. During the last four months she had suffered much pain over the whole of the abdomen; the catamenia had ceased, and her general health had been much affected.

On admission to the Hospital, an undefined tumor was felt upon the left side of the abdomen, and there was much heat and tenderness, indicative of peritonitis. The skin became inflamed, an abscess formed, and on December 30th burst, discharging a considerable quantity of fœtid matter. The suppuration continued; vomiting was almost constant, and the patient gradually died, exhausted, on the 5th of February, 1856.

The *post-mortem* examination revealed an ovarian tumor about the size of a new-born child's head in the lower part of the abdomen upon the left side. It was firmly adherent to the parietes and surrounding parts, and upon its right side was a fæcal abscess which had discharged during life. A small hole was found in the cæcum, by which the intestine communicated with the abscess. No disease existed elsewhere, except some recent pneumonia at the base of one lung. A section of the tumor showed it to be made up of an infinite number of cysts, containing a very thick gelatinous-like material, and therefore was of that variety of ovarian dropsy known as the areolar or alveolar, and by some considered carcinomatous. The larger loculi upon its upper surface were the size of hen's eggs, but the lower ones were much smaller, so that a section of the inferior part of the tumor closely resembled colloid cancer. The interesting feature of the case, and which was the reason of its being brought before the Society, was the character of the epithelium which was found in most of the cysts. Their lining was composed, as is usually the case, of hexagonal pavement epithelium; but growing from the partitions between the cysts were some microscopic tufts, or villous processes, whose surface was covered with *ciliated epithelium*. The epithelium was nucleated, and resembled pretty much that of the Fallopian tubes.

The case may be associated with one of cystic disease of the testicle brought before the Society by Mr. Athol Johnson,* and which exhibited a similar ciliated epithelium in its interior,

* *See* p. 241.

and with a somewhat similar disease, quoted by that gentleman from Wedl's work on "Pathology." I may mention that while studying the structure of this tumor, I had an opportunity of examining another ovarian cyst of the well-marked proliferous kind; but I could find no epithelium having the character of the present one. Dr. WILKS, 19*th of February*, 1856.

VI.—DISEASES, ETC. OF THE OSSEOUS SYSTEM.

1. *Fracture of the Occipital Bone, with Bony Union.*

The patient from whom this specimen was taken, was a man, æt. 46, who was admitted into St. George's Hospital in March, 1856, under the care of Dr. Wilson, with extensive ulceration of the stomach, of which he died the following month. On his admission, he stated that three years since he fell from his horse on the back of his head, which caused an extensive lacerated wound of the scalp, and that he was delirious for some days after the accident.

On examination of the cranium, a very distinct line of fracture was detected on the left side of the skull. It commenced at the upper part of the occipital bone, on the left side, and passed almost perpendicularly downwards through the cerebral and cerebellar fossæ, becoming lost where the groove for the lateral sinus terminates in the jugular foramen. The upper half of this line of fracture was distinct externally in the form of a linear groove, complete bony union having taken place between the continuous fractured edges. On the inner surface corresponding to the same part, the bone was thickened, apparently from recent deposit, and more vascular than natural. The lower half of the line of fracture is not united, but a distinct fissure is left between the contiguous edges of the fractured part, the margins of the fissure being thinned and rounded, as if from absorption. A quantity of fibrous tissue was found in the recent state completely filling up this fissure. Just where the groove for the lateral sinus terminates in the jugular foramen, in the situation where the fissure above-

mentioned ends a series of inequalities are observed, as if the bone in this situation had been broken up, and subsequently united,—thus almost obliterating the groove for the sinus in this part. The posterior part of the petro-occipital suture was obliterated, and complete bony ankylosis has taken place between the articular surfaces of the atlas and occipital bone on this side. The left lateral sinus was obliterated near its termination.

The remaining *post-mortem* appearances observed in the cranium and other parts of the body are not detailed, as they have no relation to the fracture of the bone.

Mr. Henry Gray, *6th of May*, 1856.

---

2. *Necrosis of the Condyle, the Angle, and part of the Horizontal Ramus of the Lower Jaw, after Typhus Fever.*

A boy, æt. 14, came into Guy's, under my care, in September, 1854. He complained of great pain and swelling of the right side of the face and neck. He had been first ill with typhus fever, and next with small-pox. I found the right upper jaw and right half of the lower necrosed. The greater part of the right inferior maxilla was removed, and a few days afterwards the piece exhibited. This piece consists of the condyle, the angle and a part of the horizontal ramus which contains the posterior molar teeth, the pulp of the dens sapientiæ and the next molar. On its inside, the dental foramen and canal are seen.

This boy entirely recovered with comparatively trifling deformity, and when I last saw him, a few months since, considerable progress had been made by nature to repair the loss he had sustained.

The persistence of sensation in the skin of those parts supplied by the filaments of the dental nerve was, in this case, very remarkable; for, certainly, a very large piece of the trunk of the nerve must have been destroyed,—at least, all that part which once occupied the dental canal of the piece of bone removed. Mr. John Birkett, *15th of April*, 1856.

---

3. *Necrosis of the Symphysis and portions of the Horizontal Rami of the Lower Jaw, consequent upon Cancrum Oris. Reparation of the Loss thus sustained by the Development of New Bone.*

L. N. a delicate strumous child, was admitted into Guy's Hospital in October, 1851, and she was treated by me until September, 1852.

A large sloughing wound (cancrum oris) occupied the right angle of the mouth and neighbouring parts of the face. The sloughs came away, and at last the symphysis of the lower jaw, parts of the horizontal rami, and the two first molar teeth (Figs. 8 and 9.). The separation of the dead from the living

Fig. 8.

in/ Represents the ~~ex~~ternal aspect of the portion of jaw-bone.

Fig. 9.

ex/ The engraving represents the ~~in~~ternal aspect of the bone.

bone took place posterior to the dental foramina. The wound eventually healed, and with the assistance of a little plastic surgery very little deformity of the mouth was the result.

girl The ~~child~~ is now, April 1856, under my care in the Hospital. The horizontal rami of the lower jaw are firmly connected

together by an osseous growth, which occupies the site of the original portion of the lower jaw. The powers of mastication are very good, the deformity of the lower lip very slight, and, what is most remarkable, the sense of feeling about the skin is very nearly perfect. Under ordinary circumstances the saliva is retained within the mouth, but occasionally a few drops escape from the right commissure.

Mr. JOHN BIRKETT, *15th of April*, 1856.

---

4. *Case of Ankylosis at the Upper End of the Spinal Column.*

In this specimen, taken from a female, æt. 18, in King's College Dissecting Rooms, there is ankylosis, on both sides, between the occipital bone and the atlas, and between the axis and third cervical vertebra, the intervening atlo-axoid and remaining intervertebral joints being free from ankylosis.

The coalescence between the occipital condyles and the lateral masses of the atlas is perfect and symmetrical, presenting a smooth, polished, and tolerably even surface, free from irregularities and cicatrices. Between the anterior arch (which is normal in appearance) and the basilar process, is a somewhat rounded foramen, of the diameter of a goose-quill.

The anterior root of the transverse process of the atlas is absent on both sides, and the tip is smaller than in the normal condition.

The remaining root is attached to the posterior extremity of the lateral mass and to the posterior arch, as usual, is grooved anteriorly and superiorly by the vertebral artery, and presents, at the point of attachment, a small round foramen of the size of a crow-quill, on each side. Such a foramen is also present in the posterior root of a normal vertebra in my possession.

Between the posterior arch and the margin of the foramen magnum there is a laminated coalescence, more strongly marked on the left side, leaving in the centre an elongated interval, with smooth, thin borders. On each side, at the position of the entrance of the vertebral artery through the posterior

occipito-atlantal ligament, is a round, smooth opening, of the full diameter of that artery, and perfectly equal in size.

The left lateral mass of the atlas projects more inwards than that on the right, which, in its turn, projects more than normal downwards and outwards.

The coalescence between the bodies of the axis and third cervical vertebra has taken place only at the sides where the anterior roots of the transverse processes are implanted, the line of junction being marked by a faint transverse ridge on both sides anteriorly; but posteriorly, in the vertebral canal, a perfectly smooth unmarked surface is apparent on the right side. The centre of the articulation is occupied by cartilage of the usual thickness for about half an inch transversely, in which cartilage is quite evident, both above and below, a distinct lamination for the secondary epiphysis of the bodies of the respective vertebræ which ossify about the age of twenty. These are also very distinct between the bodies of the lower cervical vertebræ.

The transverse processes of the third vertebræ are not united to those of the axis, but present a very marked resemblance to them in shape, direction, and appearance; inasmuch as they do not present the usual groove above for the passage of the second cervical nerve, but are small, depressed, pointed, and thin, at the extremity, like those of the axis. The arterial foramina are perfectly normal in size and shape, but in both vertebræ have the upward, outward, and backward direction peculiar to the axis.

The articular processes and laminæ are entirely coalesced, leaving, externally, a faint, smooth, curved line at the site of the former, and a slight depression at the junction of the latter. The coalescence is without spiculæ and irregularities, and, in the interior of the spinal canal, presents a perfectly smooth, unmarked, even surface in the whole extent of the arch. A large intervertebral foramen is left on each side for the passage of the nerve. The spinous processes are also coalesced, their terminal tubercles only being free. The right spinous tubercle of the axis is displaced to the extent of about a quarter of an inch from its normal position, but the left

is directly above the corresponding one of the third vertebra.

The inferior articular surfaces of the atlas are covered with healthy cartilage, but are remarkably altered in form, so as to present an appearance closely resembling those of the normal occipital condyles. They are very convex in the lateral diameter, and narrower internally than externally. The superior articulating surfaces of the axis are deeply concave, and are continued upwards on the sides of the odontoid process, for more than half its length—that on the left being continued nearer the median line than the right one, which latter is also more deeply concave. The odontoid process itself is also much changed. Its anterior facet is much bevilled off above, and presents a doubly convex, healthy-looking, articular surface, which is continuous with the superior facet on the left side of the body of the vertebra. It tapers much to the point, and is wanting in the posterior nodule or projection. Its neck is obliterated on both sides, and its whole appearance is pyramidal.

There is marked *lordosis* of the whole of the cervical spine, its whole arrangement showing an evident early provision for performing the antero-posterior movement of the head, compensatory for that of the occipito-atloid movement.

The following peculiarities seem strongly to indicate that the origin of this deformity is intra-uterine.

1. The smooth and regular appearance of the surface at the coalesced parts, as if they were agglutinated while in a soft state, presenting no spiculæ nor marked cicatrices.

2. The absence of the anterior roots of the transverse processes of the atlas.

3. The symmetry of the foramen between the anterior arch of the atlas and the basilar process, pointing to a subsequent ossification (after birth) of the centre for the anterior arch.

4. The resemblance between the transverse processes of the agglutinated axis and third vertebra, pointing to a congenital assimilation in form and function.

5. The presence of the intervertebral fibro-cartilage between

the centres of the coalesced second and third vertebræ, as well as of the laminar epiphysial cartilages.

6. The complete fusion of the neural arches, articular processes, and lateral parts of the bodies, pointing to a congenital coalescence of the lateral primary ossific centres, only those for the bodies remaining distinct.

7. The remarkable alteration in the atlo-axoid articulations, showing a very early adaptation for the altered mechanical conditions.

8. The presence of *lordosis*, or backward curvature, to a much greater degree than is usually met with in curvatures resulting from disease after birth, and probably resulting, like the slight twist in the spinous process of the axis, from the position of the fœtus in utero, with its head thrown backwards.

9. The laminar ossification in the position of the posterior occipito-atloid ligament has been, probably, a subsequent non-inflammatory ossification resulting from a fixed position.

Mr. JOHN WOOD, 19*th of February*, 1856.

Report on this specimen.—1. In the fusion or ankylosis of the atlas to the occiput, the apposition of the corresponding surfaces, although very nearly exact, is not quite so: the atlas is slightly advanced forwards on the occiput, and that more on the right than on the left side, thereby causing a trifling, but yet a perceptible, rotation of one bone upon the other. That change of relation is, in our opinion, inconsistent with the opinion expressed by Mr. Wood, that the junction of the bones was owing to an irregularity in the development before birth. We consider that it must have been the effect of disease, followed by ankylosis.

2. In the adhesion of the axis to the third vertebra, the apposition of the corresponding surfaces is likewise nearly exact; but it is not quite so: the axis is perceptibly shifted sideways to the right of the third vertebra at the same that it is depressed on that side. That change of relation would indicate that, supposing disease preceded the union, the articular surfaces on the right side were more extensively destroyed than those on the left: and view is strengthened by looking to the posterior

aspect of the bodies, when it will be observed that the original line of separation between the two vertebræ remains visible on the left, but is concealed by what appears new bone on the right side. Moreover, the foramen for the transmission of the spinal nerve is larger on the left than on the right side, a difference which may be attributed to the same cause.

3. The closeness of union of the several anchylosed bones, whereby the original boundaries of the vertebræ have been confounded, affords no proof against the junction having taken place after disease. Numerous specimens might be brought forward to show this. We may refer to a paper in vol. xiii. of the "Transactions of the Royal Medical and Chirurgical Society," by Mr. Lawrence, where he particularly adverts to that appearance in ankylosis of the cervical vertebræ and occiput following disease.

4. A remarkable feature in Mr. Wood's specimen is the absence of signs of disease, or ankylosis, in the articulations between the atlas and axis; but his preparation is not singular. In the paper by Mr. Lawrence above quoted, a specimen (still preserved in the Museum of St. Bartholomew's Hospital) is described, in which ankylosis had taken place between the atlas and occiput, and between the axis and the third cervical vertebra, just as in Mr. Wood's case. In a communication received by one of us from Mr. Paget, to whom Mr. Wood's specimen was shown, he states, "In the specimen in our Museum (Series iv. No. 26) the union of the occipital bone and anterior half of the atlas is very similar to that which you showed me yesterday; but there is no union posteriorly; the articular processes of the first and second are not united; but they are not healthy, as in the specimen you showed me; they appear to have been ulcerated in a less degree than those of the occiput and atlas, and of the second and third, between which severally union has taken place. Altogether the similarity of the two specimens is very striking."

5. Although in the articulations between the atlas and axis no signs of previous disease are apparent, yet some remarkable changes in the forms of the bones must not be left unnoticed.

The inferior articular surfaces of the atlas have a rounded, somewhat globular shape, bearing a close resemblance to that of the condyles of the occipital bone: and the corresponding (superior) articular surfaces of the axis are concave, like those in the atlas which receive the condyles of the occipital bone. Here, then, is an obvious provision, for those nodding motions of the head, which must have been lost in consequence of the ankylosis between the occiput and atlas being performed by the movement of the atlas upon the axis: and it is to be remarked that the front part of the odontoid process has been singularly bevilled off in a slanting direction backwards, as if to favour that nodding motion. Again, in the axis, the upper lateral articular surfaces are prolonged upon the sides of the odontoid process (the left being directly continuous with the articular disc in front of the process, the right being less perfectly so); and in the atlas the articular surface on which the odontoid process plays, extends on each side, so as to surround the process with about three-fourths of a circle of articular surface. It is obvious that these changes are additional adaptations for combining the nodding motions just mentioned with the rotatory movements proper to the two bones. No traces of a transverse ligament are visible.

Mr. SHAW and Mr. GRAY, *4th of March*, 1856.

---

5. *Specimen of Scrofulous Necrosis and Caries of the two Last Dorsal and two Upper Lumbar Vertebræ, without Psoas Abscess, but with Abscess passing backwards and upwards, and opening externally opposite the Spinous Processes of the last Cervical, and First Dorsal Vertebræ.*

This specimen was removed from the body of a boy, æt. 12, a patient of Dr. J. S. Lavies. The boy was of a decidedly strumous diathesis, though said to have been strong and healthy up to six years of age, when he had the measles. After this he ailed continually and suffered from strumous abscesses in the foot, attended with exfoliations of bone. About six months before his death he fell upon his back, and after this complained

of severe pain in the spine. The spinal column became rapidly curved; posterior angular curvature formed, with prominence of three or four spinous processes in the lower dorsal and upper lumbar regions; and gradually the upper part of the spine fell forwards to an obtuse, or almost a right angle with the lower portion.

Six weeks before his death, when he first came under the care of Dr. Lavies, there was an external abscess in the upper dorsal region, having a tender spot on its surface. This soon gave way, and an ulcerated aperture, the size of a shilling, formed over the spinous processes of the seventh cervical, and two upper dorsal vertebræ, which were now seen projecting into the cavity of a large abscess, leading downwards towards the angular curvature. The discharge was at first profuse, afterwards frothy pus was seen to *well up* in the cavity of the abscess. The quantity of pus could be immediately increased by placing the patient in the horizontal position.

The boy remained day and night in a sitting posture, supported by pillows, and by his arms, with his hands resting on the bed so as to act as natural crutches or supports to the upper part of his spinal column. Any attempt to lie down produced difficulty of breathing and urgent symptoms. The power over his limbs remained unimpaired, neither was there any paralysis of the bladder or rectum.

The boy was in this state when first seen by Mr. Adams. He was extremely emaciated, and gradually sank.

At the *post-mortem* examination, the two last dorsal and the two upper lumbar vertebræ were found completely destroyed, and, for the most part, removed, portions only remaining in a necrosed condition, loosely connected with the surrounding tissues. Two of the arches of the vertebræ were also in a necrosed condition. They presented the ordinary dead-white appearance of dead bone, were separated from the soft tissues, and bathed in pus. From this circumstance the pus had found its way backwards amongst the spinal muscles; but its upward direction was not so easily to be accounted for. Possibly it might have been determined by position in the early stage.

There was no disposition to psoas abscess. There was no appearance of tubercular deposit in the cancellous tissue of the adjacent vertebræ. The dura mater of the spinal cord was coated with pus and lymph; and a small quantity of lymph existed between the arachnoid and dura mater. The cord itself was healthy, and had not suffered compression.

The lungs were studded with miliary tubercles; but the other organs were all tolerably healthy.

Mr. Adams, in reply to a question, stated that, from opportunities he had had of examining destructive disease of the spine in its early stage, at St. Thomas's Hospital, he believed that when the bones were primarily attacked, the disease assumed the character of necrosis rather than caries: but that when it commenced in ulceration of the intervertebral cartilage, destructive disease extended itself, both by caries and necrosis, as in the diseases of joints generally. In the present instance the large chasm had evidently been produced by a combination of all three processes; but necrosis had probably been the primary and predominant form.

Specimens illustrating the progress of destructive disease of the spine exhibited by Mr. Adams, were described in vols. iii. and v. of the Society's "Transactions."

Mr. W. Adams, 18*th of March*, 1856.

---

6. *A Specimen of Pelvis Oblique Ovata from a Female Subject.*

Of this deformity there are few recorded specimens in this country to be added to those originally enumerated by Naegele. The present specimen, though not extreme in its irregularity, illustrates somewhat the causes of the deformity, and their progress.

The left sacro-iliac joint is ankylosed, and the pubis pushed over to the right side, the right sacro-iliac joint being free from disease. The most marked deviations from symmetry in its diameters are as follows:—

At the brim.—A direct antero-posterior line cuts the left pubis, seven lines external to the symphysis. The distance from the sacral promontory to the pubic symphysis is four inches six

lines. The left oblique diameter is five inches four lines, and the right oblique diameter five lines less. From the sacral promontory to the left acetabulum measures three inches four lines; from the same point to the right acetabulum being six lines more.

At the outlet.—The distances between the ischial spines and tuberosities are about the female average, but that from the tip of the coccyx to the lower end of the symphysis pubis is considerably diminished, being only three inches two lines.

The external oblique measurements present, in a limited degree, the inequalities characterized by Naegele, *viz.:* from the left sciatic tuberosity to the right posterior superior iliac spine, seven inches two lines; from the right sciatic tuberosity to the left posterior superior iliac spine, being six lines more. From the last lumbar spine to the left anterior superior iliac spine measures six inches six lines; the distance from the same point to the right anterior superior iliac spine being five lines more.

The site of the ankylosed joint presents, anteriorly, a distinct raised line of cicatrix, differing in this respect from the character especially enunciated by Naegele, of complete cases of the deformity, which presented no such cicatrix. This, taken with the limited degree of the deformity, may be considered as indicating a later origin than the intra-uterine one advanced by most writers on the subject. There is, however, a marked arrest of development on the left or ankylosed side of the sacrum, which measures, from the centre of the promontory to the cicatrix, only two inches; while the distance from the same point to the right sacro-iliac joint, is ten lines, or nearly an inch more, both measured along the curve. Again, there is also a slight shortening of the iliac shaft from the sacro-iliac junction to the ilio-pectineal eminence on the left or ankylosed side, which measures along the curve two inches ten lines; while on the right side it measures three inches one line. We thus find the arrest of development to be much more marked in the sacrum than in the ilium. This seems to be always the case in this deformity, and may be accounted for by reference to the development of the sacrum. About the eighteenth

year is developed, on each auricular facet of that bone, an epiphysial plate of bone, placed opposite to the three upper sacral vertebræ which form the joint. Below this point, and on the lateral aspect of the two last sacral pieces, another epiphysis is developed on each side. These epiphyses, on being completely ossified and united to the body of the bone will, under normal conditions, go to increase its breadth. But if inflammatory disorganisation and consequent ossification of the joint occur before their formation, such epiphysial growth will be prevented, and the sacrum diminished in width on the ankylosed side. In the specimen, the width of the sacrum, opposite to the two last vertebræ, measured from the median line, is not diminished on the diseased side, showing that at this point the epiphysial formation has not been prevented by the disease. These considerations fix the period of the first occurrence of the disease before the eighteenth year, while the presence of the cicatrix, and the limited extent of the deformity, suggest a considerable previous advance of normal pelvic development, say, then, about the period of puberty.

In the more extreme cases given by Naegele (as in one where the sacrum on the diseased side measured only one inch four lines, and on the opposite side, two inches two lines, or twice as much), the ankylosis, no doubt, has taken place during fœtal development, and, as I conceive, at or before the sixth to the ninth month, when it would prevent the formation of the characteristic ossific points, three in number on each side, placed close to the sacral foramina, and which begin to appear at the above period. The sacral foramina in these cases are somewhat contracted on the diseased side of the pelvis, which retains more of the fœtal characters generally than are seen in the specimen under consideration. On the other hand, there are many specimens extant of ossification of the sacro-iliac joint on one or both sides, without any oblique deformity whatever. In these, the disease has evidently occurred after the complete development of the pelvis, and has not interfered with the normal mechanical conditions.

In his "Traité Complet de l'Art des Accouchements," M. Dubois mentions a theory of M. Gavarret, as to the cause of

the oblique deformity, founded exclusively upon the wedge-like action of the sacrum. He considers the horizontal outward force of the wedge to be the agent producing the transverse development of the pelvis, and the vertical force the only weight which is transmitted to the femurs. In applying this to the explanation of the oblique deformity, M. Gavarret supposes the sacrum to lose its wedge-like action by the ankylosis, and so the outward horizontal force is wanting on the diseased side, and there is no resistance to the inward pressure of the head of the femur, which sustains the whole weight of that side, falling vertically upon it. In this theory, M. Gavarret has made an evident mistake in supposing, in the first place, that the femurs do not support the whole weight of the body in the normal condition. The outward transverse force which he illustrates, is really resisted by the posterior sacro-iliac ligaments (which are the chief supports of the sacrum between the ilia), so that this force is, as it were, emphasized in the iliac tuberosities, and transmitted to the femurs through the iliac lever (Fig. 10. I. K.). Secondly, as was remarked by Dr. Matthews Duncan, Lecturer on Midwifery, in Edinburgh, and author of several valuable monographs on the mechanics of the pelvis and pregnancy, M. Gavarret, in the pathology of his subject, overlooks the fact that since ankylosis on one side destroys the wedge-like action on both sides, the transverse force on both sides is annihilated; but the outward enlargement of the side not ankylosed, is absolutely increased in oblique pelvis.

Dr. Duncan, denying altogether the wedge-like or keystone action of the sacrum, considers that bone to be sustained only by the posterior sacro-iliac ligaments, acting on the posterior end of the iliac beam, against the inward pressure of the femurs at the anterior extremity, and upon the sacrum as a fulcrum. To the outward pressure at the acetabulum, caused by this mechanical arrangement, he ascribes the transverse development of the pelvic diameters, and adduces, as a proof of its action against the opposing pressure of the femurs, the bend of the linea innominata. To the loss of this outward force on the ankylosed side, he attributes the want of outward

development of that side of the oblique pelvis, and its increased effect on the opposite side.

Dr. Duncan's arguments, I am bound to say, do not shake my faith in the old doctrine of the sacrum acting as a keystone under certain conditions. In his own theory, he has not, I think, given due importance to the presence, at the cotyloid end of his iliac beam, of a tie or counter-prop; the pubic arch, which, notwithstanding the interposition of the cotyloid cartilage and epiphysis, in early life, between it and the ilium, must necessarily modify the action of the iliac beam to a great extent, which cannot therefore be considered independently of it, especially in any outward pressure. The bend which he considers to take place in the cotyloid arm of the iliac beam will, if the bone be examined in a transverse section parallel to the line of pressure, be seen to be more apparent than real, and that, though the inner surface of that beam be concave, the external surface opposite to it is concave also, and that therefore the beam must be considered as a straight one, at least from the acetabulum to the sacral fulcrum, at which point a bend takes place in the posterior arm of the lever, but in an opposite sense, *viz.:* outwards.

One of the most suggestive facts in the consideration of the causes of oblique pelvis, is that alluded to by Dubois in the work before cited, that ankylosis of the sutures of one side of the skull produces a like obliquity to this of the pelvis. To overlook this broad hint is, I think, fatal to any theory on this subject.

Development and growth of bones may be said generally to take place in two ways. 1. Interstitially, or throughout the whole substance of the osseous structure. 2. By surface-growth, and by epiphysial, or double surface-growth. The latter mode is most marked in its influence at the extremities of long bones. Applied to the development of bones arranged in a circle or globe, it assumes a very great importance in producing the enlargement of the diameters of the circle or globe. The interstitial growth will, under these circumstances, take place in layers coinciding with the planes of radii from the centre of the figure (Figs. 10 and 11 A*h*, A H,) the

growth being greater at the extrados than at the intrados of

Fig. 10.

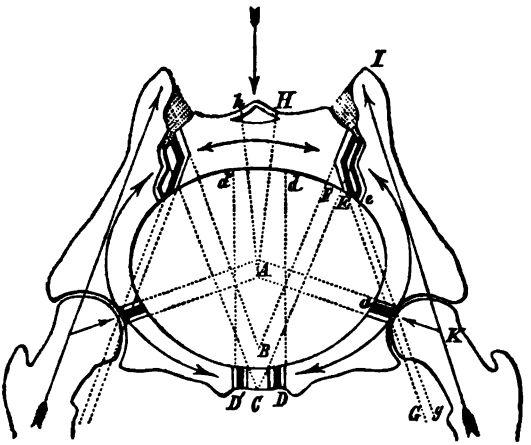

THE HEALTHY PELVIS.

the arch, on account of the greater mass of developing osseous

Fig. 11.

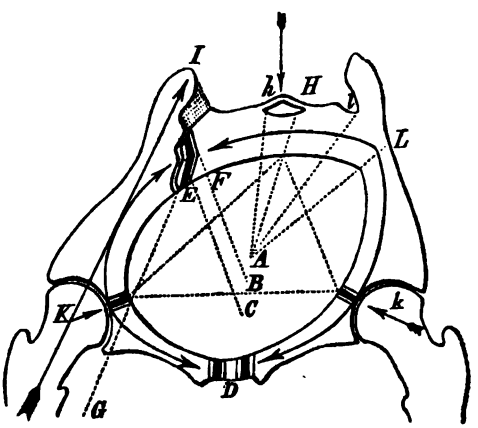

THE OBLIQUE OVATE PELVIS.

matter placed there already. This kind of increase will give a

certain amount of circular expansion, but will not account for the very rapid change and development which takes place during childhood in the skull, and at the period of puberty, in the pelvis.

After this time, epiphyses begin to form at the extremities of the bony arches forming the pelvic circle, and the influence of the double surface-growth begins to be marked by the rapidity of expansion of its diameter. At the sacro-iliac joints, however, the epiphyses are comparatively late in forming, nor does one form at any period upon that part of the ilium forming these joints. In its place, however, there is one on each side at the cotyloid centre of the lateral arches (Fig. 10. A*a*), which, from its position, provides more especially for the enlargement of the antero-posterior diameters of the pelvis, and for those of the acetabulum itself; from its earlier appearance continues a little longer the fœtal preponderance of the conjugate diameters, and, from its greater size in the male subject than in the female, keeps up the tendency to antero-posterior capacity in the former sex, and provides for a larger thigh-bone.

On referring to Fig. 10, it will be seen that of the three joints which break the continuity of the pelvic circle, the epiphysial and surface-growth of the pubic joint, laid on in lines (D*d*, D′*d*′) nearly parallel to the antero-posterior median plane, will have the greatest effect in widening the transverse diameters, and that the surface-growth of its two epiphyses will nearly equal that of the two sacro-iliac together, the latter having each but one epiphyses.

This importance of the pubic joint is significant when taken with its relation to the organs of generation, and to the more frequent occurrence of the pubic epiphyses in the female than in the male, according to Beclàrd.

It will also be remarked that the surfaces of the two sacro-iliac joints, as they are seen on a transverse section in the line of pressure, are placed, posteriorly, in planes, which converge, not to the centre of the pelvic circle (A), but to a point at or anterior to the pubic symphysis (C), while, for rather more than the anterior half of the auricular facets, the planes of

these surfaces are divergent, and directed more or less towards the centres of the acetabula, as in the line E G *e g*.

Deposit of bone taking place in parallel layers on the surfaces and their epiphyses, there is a constant tendency to advance the centre of the circle, of which the sacrum is a segment (as from B to C), and to increase the openness of its curve.

This expanding action will be evidently rendered still more effective by the progressive lamination upon the anterior divergent planes of the auricular facets. By virtue of the two additional surfaces on the iliac facets, this obliquely acting enlargement of the sacral portion of the pelvic circle will by so much preponderate over the more directly acting pubic increase, and give to the posterior transverse diameters of the pelvis the general advantage which we see them to possess.

It will also be seen in this scheme, that the presence of *free* surfaces, as well as epiphyses at the pubic and sacro-iliac joints, give them a preponderance over the cotyloid increase, which leads to the permanent superiority of the transverse over the conjugate diameters; a preponderance which will be increased by the direction of the cotyloid planes of growth towards the centre of the pelvic circle at A, and not to a longer radius.

To this mode of growth I cannot but attribute the chief place in the causation of pelvic development, in preference to the ingenious, but somewhat too mechanical and exclusive theories I have alluded to.

In applying these views to the explanation of the deformity in question, it is easy to see that, by the sacro-iliac ankylosis, the growth at that point henceforward is interstitial only in the planes of the radii, A L, *a l* Fig. 11. and a great agent of expansion on that side of the pelvis is wanting. The want of balance which results gives the first and an ever increasing tendency to oblique deformity. When it occurs on one side only, the growth of the segment, E L, *k*, Fig. 11, is limited to interstitial expansion. When on both sides, the whole of the posterior segment between the acetabula is in the same cramped condition.

Finally, another, and, perhaps, a more powerful element of disturbance of equilibrium comes into play. In Fig. 10 it will

be observed that each of the three arches forming the pelvic circle (indicated by the curved double-headed darts), *viz.*:—the sacral, and the two ilio-pubic, support, on their respective columns, the three forces operating upon the pelvis in the erect posture,—the weight of the trunk upon the sacral culm, and the pressure of the femora on the ilio-pubic culms. In the line of the greatest pressure, *viz.*: from the spine to the femors, occur the sacro-iliac joints, which are supported by the sacro-iliac ligaments, where support is most needed, at the haunches of the cotylo-sacral arch, where it would have a tendency, under great pressure at the culm, to open outwards and rise upwards, as we see in artificial constructions of this nature. In the normal condition these forces are in perfect equilibrium.

When ankylosis of one of the sacro-iliac joints is effected, however, the conditions of equilibrium are destroyed, and we have but two arches (Fig. 11.), the sacral and ilio-pubic of the diseased side having coalesced into one arch, which is placed at a great mechanical disadvantage in sustaining two of the pressures, both applied, unfavourably, at the haunches (H and *k*), and with only the weak resistance of an ankylosis to counteract the tendency of the culm at L to rise and open upwards, the usual consequence of overloading an arch at the haunches with insufficient counter pressure at the culm. The acetabulum of the diseased side is thus brought more under and nearer to the sacral culm or promontory; the pubic symphysis pushed over to the opposite side; the point of ankylosis at L *l* more and more bent; and the ankylosed ilio-pubic segment more and more flattened; while the opposite ilio-pubic segment is rendered more concave, and the leg pushed further from the line of gravity of the body; so that the leg of the ankylosed side bears habitually more than its share of the support of the trunk, and the progress of the deformity is increased.

Mr. JOHN WOOD, *6th of May*, 1856.

7. *Impacted Fracture of the Cervix Femoris ununited by Bone. Longitudinal Fracture through the great Trochanter and Upper part of the Shaft, with Bony union.*

The fracture of the neck is close to the inter-trochanteric line posteriorly, and clearly outside the insertion of the capsular ligament: anteriorly it is just at the line of insertion of the capsular ligament. The neck is driven into the longitudinal fracture to the extent of half the diameter of the trochanter major. The union, notwithstanding, seems to have been ligamentous only, as it was moveable slightly, even in the recent state. No bony exudation whatever is apparent on the fractured end of the cervix.

The posterior half of the great trochanter, the whole of the lesser, and about two inches of the posterior surface of the shaft, are broken from the rest of the bone by a longitudinal fracture, which has united by bone, though not firmly, nor to the whole extent of the fractured surfaces. A copious exudation of bony matter has taken place on the shaft side of the fracture anteriorly. A much smaller exudation is apparent posteriorly upon the detached portions of the trochanters and shaft. A small portion of the upper border of the great trochanter has been separated, but become reunited by bone to the detached half of the trochanter.

The cervix femoris is placed at right angles to the shaft. Around the margin of the articular surface is a pretty copious deposit of bone, forming a distinct rim overhanging the neck. On the upper part of the head is a large patch of porcelainous deposit. At the point of attachment of the ligamentum teres is also an osteophyte.

The cervix femoris of the opposite side is placed at the normal angle (120°). It exhibits no osteophytes, and but a little porcelainous deposit.

This arthritic change, then, has probably taken place principally subsequent to the fracture. And notwithstanding the want of firm bony union, it has gone to a much greater extent on the detached head of the femur than on the uninjured one. The inflammation set up by the fracture has probably been the

exciting cause. But this has not been effective enough to contribute a proper share to the union of the fractured surfaces.

Mr. JOHN WOOD, 19*th of February*, 1856.

---

8. *Section of an Impacted Fracture of the Neck of the Thigh-bone, from a subject diseased with Mollities Ossium.*

The outline of the fracture is very distinct. The lower margin of the neck passes completely across the atrophied cancellous tissue of the great trochanter, and rests at its middle upon the lesser trochanter. The cervix is consequently much shortened, and placed at right angles with the shaft.

The fracture is completely united by bone, but below the great trochanter posteriorly is an elongated foramen leading into the medullary cavity below the fractured neck. In the recent state this was closed by fibrous membrane. A similar opening passes through the external layer of bone at the base of the great trochanter externally, and communicates with the site of the embedded cervix. These, most probably, are gaps left unfilled by ossific deposit during the union of the fracture.

Most of the bones in this subject presented fractures in different stages of reparation.

Mr. JOHN WOOD, 4*th of March*, 1856.

---

9. *Excision of the Head of the Femur, for Disease of the Hip-joint.*

Mr. Shaw exhibited the upper head of the right femur, which he had removed, on the 28th of February, from a lad with hip-disease: also a cast showing the appearance of the joint previously to the operation.

R. B. æt. 17, was admitted into the Middlesex Hospital as a physician's patient on the 12th of July, 1855, for supposed rheumatism and fever. Three weeks afterwards he was transferred to the care of Mr. Shaw, as affected with disease of the right hip-joint. The pain in the hip and down the limb, especially in

the knee, was of the severest kind; and it was accompanied with occasional paroxysms of spasms about the hip. In spite of numerous remedies, including a course of calomel and opium, his suffering continued unabated for about three weeks, at the end of which time he had become greatly emaciated. Early in September the pain rather suddenly diminished; when on examination it was found that the head of the femur had been dislocated on the dorsum of the ilium. That occurrence had been probably favoured by the patient constantly lying on the sound side, with the affected hip and side of the pelvis drawn up, and the limb crossing the other about the middle: owing to that position, the head of the femur would be partially withdrawn from the cavity of the acetabulum; and it was conjectured that the dislocation had taken place in one of the paroxysms of spasm. But the boy could not remember any particular fit when it might have occurred. The marked alleviation of pain subsequent to the dislocation, was supposed to be owing to the cessation of the attrition between the diseased surfaces, and to the relief to the tension of the parts.

During the course of the disease there had been an absence of general swelling about the hip. After the dislocation it was the same; and the skin and subjacent parts were drawn with considerable tension over the projecting head and trochanter, more particularly over the latter. Towards the middle of September there was a swelling which threatened the formation of an abscess at the inner and posterior part of the upper third of the thigh; but in the course of a short time that disappeared. In the end of November, a gutta percha splint having been applied, he was able to get about on crutches. About Christmas, when arrangements had been made for his discharge, inflammation, followed by suppuration and ulceration, took place in the neighbourhood of the trochanter major; excited, as it appeared, by the pressure and friction of the projecting trochanter upon the skin and fascia drawn tensely over it, in walking. In the middle of February a piece of necrosed bone was extracted from the trochanter. On the 28th of the

month, it having been decided in consultation that the case was a proper one for excision of the upper end of the femur, the operation was performed. During its progress some difficulty was experienced in thrusting the part to be removed out of the wound previously to sawing, in consequence of fibrous union having taken place between the cervix of the femur and the margin of the acetabulum. As far as could be seen, or could be felt by the finger, the surface of the acetabulum appeared to have been deprived of its cartilage; but there was an absence of pulpy lymph, or softening, like caries; the bone, although bare, was dense, and seemingly sound in structure. The parts of the femur removed were the head, cervix, and trochanter major.

Of these, the head alone had undergone any manifest change. At the site of the round ligament, it had lost some of its rotundity; and its structure was softened at that part, so as to yield to compression. Near the cervix there was an indentation, apparently caused by pressure of the head, as it lay out of the socket, against the edge of the acetabulum. The surface generally had been denuded of its cartilage: which had been replaced by fibrous membrane, thick and rough in some places, thin in others, and in intimate union throughout with the bone beneath.

For some days after the operation, the patient had fever; which precluded the application of a splint; and the limb was laid with the knee bent over a pillow. The wound suppurated favourably, and gradually closed. At the end of three weeks, attempts to elongate the limb, which was five inches shorter than the other, were commenced. Much of that shortness depending on encurvation of the spine, and consequent elevation of the right side of the pelvis, he was made to lie on his left side for three hours daily (divided into short periods) with pillows placed under the ilium; the effect of that position was to stretch the parts on the concavity of the curve, and so to straighten the column. Subsequently, a weight, hanging over the end of the bed, was attached to the ankle, so as to elongate the limb. In eight weeks, the wound being cicatrized, except a narrow sinus leading to the acetabulum, from which about

a couple of drachms of matter escaped daily, he was allowed to get upon crutches.

June 6th.—For some weeks past the wound has been quite healed. With a crutch and stick he walks several hours daily. He can rest for a few seconds, without pain, on the right limb alone; and can throw it about with freedom in different directions. A marked improvement has taken place in the curvature of the spine, and the two sides of the pelvis are nearly level. The right limb is not more than two inches shorter than the left. To-day he was measured for a high-heeled boot. Mr. Shaw, 18*th of March*, 1856.

---

10. *Compound Fracture of the Thigh, with Laceration of the Main Vessels, produced by a Ramrod discharged from a Cannon.*

The man was admitted into St. George's Hospital, on the 5th of November, with the following history. The patient, æt. 35, was loading, for the amusement of some children, a cannon, the length of which was twenty inches, with a bore of three-quarters of an inch, and just as he was ramming down two ounces of powder which he had put into the cannon, a boy with a lighted squib ran by; the man, being afraid of the sparks, endeavoured to get out of the way, but before he could do so, a spark set fire to the priming, and the cannon went off, driving the ramrod through his thigh. He was at once knocked over; and, by the account of the friends who brought him, lost, within a short time, a very large quantity of blood.

On examination, it was found that the ramrod had passed through the thigh; entering the front, at the lower third of the bone, it had made its way out at the back part higher up, so that the direction of the wound was oblique upwards and backwards. Both wounds presented a round shape; the one in front being about the size of a florin, and that at the back the size of a shilling. The bone was completely shattered, several fragments being loose and scattered among the muscular fibres. The soft parts around were extensively lacerated and infiltrated with blood, some of which was still oozing out

of the wounds, and there appeared to be some effusion into the knee. It was impossible to ascertain the exact state of the vessels; the parts below the injury were not cold, but from the large quantities of blood which had been lost, and the proximity of the main vessels to the bone at the seat of injury, it appeared probable that they, too, had been implicated.

Amputation was decided upon; the integuments being but little injured, and the muscles very much torn. Mr. Prescott Hewett performed the circular operation; and so completely was the bone shattered and splintered that the saw was not necessary for the removal of the limb, which was taken off at its upper third; the jagged extremity of the bone was subsequently smoothed by the sawing off of a small piece of bone.

A dissection of the parts which had been removed, showed that the thigh-bone, at its middle third, was completely split up into fragments, the largest of which were not more than two inches in length, the muscles in the neighbourhood were extensively lacerated and infiltrated with blood; this infiltration was traced under the *vasti* muscles down to the synovial *cul de sac*, but no blood was found in the knee-joint itself, the cavity of which presented a healthy appearance. Lodged in the muscles at the back of the thigh was found the screw end of the ramrod, about two inches long, which had been snapped off by coming into contact with the bone: this piece of the screw was filled, in its whole length, with pulverised bone. On passing a probe down the femoral vein, a rent of half an inch in length was detected in that part of the vessel corresponding to the canal of the *adductor magnus*, and a careful examination of the artery showed also, in the corresponding part of this vessel, a small hole, just large enough to admit the blunt extremity of a small probe; the openings in the vessels were blocked up by coagulated blood. These lacerations in the femoral vessels were evidently produced by the splintering of the bone; they corresponded exactly to the spot where these trunks come into contact with the bone, as they are passing from the femoral to the popliteal region, and the ramrod, in its course, had passed right through the centre of the bone.

Mr. Prescott Hewett brought forward this specimen to

show the great difference in the appearance of the parts, and especially the extensive shattering and splintering of the bone, which were apt to occur in gun-shot wounds—appearances differing widely from those usually presented in our civil hospitals, in cases of compound fracture of the thigh.

Mr. Prescott Hewett, *6th of November*, 1855.

---

11. *Necrosis symmetrically affecting both Condyles of the Femur, and communicating with the Knee-joint.*

In this specimen the central portion of each condyle of the femur, including the articular surface, had suffered necrosis; and a transverse section exhibited in the inner condyle a sequestrum rather less than an inch in its transverse, and rather more than an inch in its vertical diameter, extending from, and including the joint surface of the condyle, into the cancellous texture of the articular extremity of the bone. In the outer condyle was a sequestrum similar in form and appearance, but somewhat less in size. These sequestra (Fig. 12.) were

Fig. 12.



a. A sequestrum in the outer condyle of the femur.
b. A sequestrum in the inner condyle.

each in a similarly advanced stage of separation; and so

nearly was this process complete that the greatest care was required to prevent their dislodgement in making the section.

Between the living and the dead bone a groove had formed, which, on the articular surface of each condyle, had a circular or ring-like form; and from this it extended into the cancellous structure of the bone in the form of a thimble. Each sequestrum was about the shape and size of a large thimble. The only connexion between the living and the dead bone, was by a few very small portions of cancellous tissue; and these appeared to be necrosed,—judging from their whitish colour, the empty condition of their cancelli, and general appearance in the dried condition of the bone,—but still they were continuous with living bone, and served to connect the living and the dead; the groove, rendered incomplete only by the small fragments of bone above described, was very irregular in width; the widest portion corresponding to the upper part of each sequestrum.

The appearances presented by the osseous tissue on either side of the groove were very different. The cancellous texture of the healthy bone in the immediate neighbourhood of the groove was slightly condensed, or more compact than in other parts. This appeared to be the result of a reparative effort limiting and circumscribing the necrosis. In the central portion of the expanded extremity of the bone, about an inch above the notch, were two patches of dark discoloration, in which the cancellous structure appeared to be somewhat softened, and the cancelli widened, as if indicating a threatened condition of necrosis or destructive disease in these situations. The cancellous texture of the necrosed bone presented appearances precisely the reverse of those described in the healthy bone. In the circumferential portion of each sequestrum, the cancelli were very obviously widened or opened out (Fig. 12), and the septa thinner than in a healthy condition. The groove was evidently formed by the complete removal of these osseous septa. From the circumference towards the centre of each sequestrum—excepting its free joint-surface—the cancelli gradually diminished in size; and inferiorly, in the neighbourhood of the joint-surface of the

sequestrum, its cancellous texture appeared to be even closer and more compact than normal.

The general appearance of the cancellous tissue on either side of the groove above described, seemed to favour the idea that the groove was formed at the expense of the dead bone, and that, as a necessary consequence, a diminution in the size of the sequestra was taking place simultaneously with the formation of the groove; it was certain that the sequestra were smaller than the spaces represented by the cavities to which they belonged, and which were bounded by the healthy bone in a somewhat indurated condition. The increased density of the sequestra in the neighbourhood of their joint-surfaces was remarkable, and might have resulted from an increased vascular activity in this situation in the early stage of the necrosis prior to the loss of the articular cartilage and the formation of the groove. In the dried condition of the bone, the cancellous tissue of the sequestra was seen to be empty, or free from the oil and fatty matter which occupied the cancelli of the healthy portion of the bone. The sequestra, therefore, presented a dead-white colour and dry appearance, which contrasted with the yellow colour of the healthy bone, the cancelli of which were filled with fatty matter.

In addition to the appearances above described, and exhibited on the transverse section of the bone, it may be observed that a small portion of the free extremity of each condyle, on either side of the corresponding sequestrum, appeared to be passing into a state of necrosis, if not necrosed, judging from the dry, dead appearance, and empty condition of the cancelli in these small lip-like processes of bone. The nutrition of these portions of bone must have been considerably interfered with by the necrosis of the large central portion of each condyle. This appearance is indicated in the accompanying wood-cut by a darker colour of these portions.

When the lower extremity of the femur was viewed from its joint-aspect, in the central portion of each condyle was seen a circular sequestrum; that in the inner condyle measuring seven-eighths of an inch in diameter, and that in the outer condyle measuring six-eighths of an inch. Each sequestrum

was seen to be bounded by a deep and well-formed groove; slender osseous connexions between the living and dead bone existing only in a few places. The articular surface of each sequestrum was not only smooth, as if the bone had been long deprived of its articular cartilage, but it was also enamelled, or eburnated, in some parts; an appearance which I have not previously met with in any portion of necrosed bone, but which indicated that the disease had existed a great length of time, that the cartilage had been removed from the head of the tibia, and that some motion of the joint had been permitted.

The whole of the articular cartilage had long disappeared from both condyles, but there was no appearance of caries in any part of the joint-surfaces of the condyles, which were, on the contrary, indurated, superficially irregular, and slightly nodulated, somewhat resembling the condition commonly met with in chronic rheumatic arthritis. The general appearances, therefore, were very different from those so frequently seen in scrofulous disease of the knee-joint, in which caries and necrosis of the exposed articular surfaces of femur, or of tibia, have taken place.

The only appearance of a reparative process, beyond the formation of the deep groove surrounding the necrosed portions of the condyles, was in the formation of a small quantity of new periosteal bone on the outer surface of each condyle; and this only extended to the formation of a thin and somewhat irregular layer of new tissue; and though indicating a reparative, rather than a destructive process, could scarcely be regarded as part of any compensative effort of nature to replace the loss of osseous substance occasioned by the necrosis, such as constantly takes place in the shafts of long bones. Rather, it may be supposed that the irritation necessarily accompanying the necrosis and coexisting joint-disease, produced a certain amount of periostitis over the outer surface of the condyles, which resulted in the superficial deposit described.

No history of this valuable specimen could be obtained, and therefore it may be considered a matter of doubt by some whether the disease was a primary affection of the bone which had extended to, and caused the destruction of, the joint; or

whether the bone-disease was consecutive to destruction of the cartilages and soft textures of the joint. From the general appearance of the specimen, I am inclined to adopt the former view, which is favoured by the absence of caries, and by the condition of the denuded osseous surfaces of the condyles of the femur above described. Mr. W. ADAMS, *6th of May*, 1856.

---

12. *Deposit of Crystalline Urate of Soda in the Cavity of the Knee-joints.*

W. W. æt. 48, was admitted into St. George's Hospital, 23rd of November, 1855, under my care. He was a painter and glazier in good circumstances, and had suffered more or less from gout for eighteen years. He never had colic, and, with the above exception, enjoyed good health. During the week preceding his admission, he was much exposed to damp; when admitted his face was pale, his tongue brownish, skin warm, pulse quick, bowels costive, urine of average quantity, and containing a small, but decided, quantity of albumen. The heart's action was feeble; there was no decided murmur. The right hand was red and swollen; his feet were slightly œdematous. There were chalk stones in the outer canthus of the ear; and many of the small joints of the hands and feet were thickened.

One week after his admission the urine was again examined and found to be albuminous, with a few blood globules; but no casts of the tubes could be found.

The acute attack gradually subsided in a fortnight, and he was about to leave the house when a fresh inflammation of the hands and feet came on, with great prostration of strength. In a few days violent epileptic convulsions followed. The slightest motion immediately brought on a fit. The pupils were contracted, the skin clammy, with excessive tremor of the limbs; and in this state, four weeks from his admission, he died.

On *post-mortem* examination, both knee-joints were carefully opened. They contained two or three drachms of thick synovia; and in each cavity there was a flake of fibrine about an inch and a half long, shreddy, with whitish specks visible to the naked eye. On examination under the microscope, small acicular crystals

were seen mixed with fibrinous matter; and when a drop of dilute hydrochloric or acetic acid was added, the whole surface of the fibrin in a few minutes became covered with uric acid crystals. The moist fibrinous clot from both the joints gave crystals having the form of uric acid; and when the fibrin was treated with nitric acid, there was distinct chemical evidence of this acid. In the cartilages of the knee-joint there was a very small surface free from the deposit of urate of soda. Both great toes at their tarso-metatarsal articulations contained the same deposit on their articulating surfaces.

The spleen was large and soft; the kidneys granular; the cortex much diminished. There were some small deposits of red sand in the mammary processes visible to the naked eye. There was a slight excess of subarachnoidean fluid. The costal cartilages were much ossified. The left lung was much congested and adherent. In the right pleural cavity there was much dark fluid, and the lung was congested.

I have observed a similar deposit of urate of soda in the cavity of the joint in other severe cases of chronic gout; and from the amount of crystalline uric acid which was seen when dilute acid was added to the fibrin wet with synovia, I have little doubt but that some urate of soda was dissolved in the alkaline synovial fluid in this case.

Dr. Bence Jones, 1*st of January*, 1856.

---

13. *Ankylosis of the Knee-joint in an aged Male subject.*

In this specimen there is bony ankylosis of the femoral condyles to the tuberosities of the tibia, after partial displacement of the internal tuberosity backwards. There is a small aperture through the ankylosed portions in the position of the intercondyloid notch. Many spicula of newly formed bone and osteophytes project around.

On the articular surface of the displaced tuberosity is a piece of dead bone lying in the centre of a small abscess, with no external communication. The patella is united to the femur by fibrous tissue only. There was much inflammatory deposit in the soft parts. Mr. John Wood, *7th of March*, 1856.

---

14. *Softened Ankylosis of the Knee-joint.*

E. W. æt. 53. a married healthy-looking woman, twenty-seven years ago fell upon her left knee. No inconvenience followed for one month, but then the joint began to swell and cause pain. These symptoms becoming worse, she was admitted into Guy's Hospital, under the care of the late Mr. Aston Key, with what was called hydrops articuli.

The joint was then punctured with a trochar and canula, and a large quantity of synovia drawn off. Suppuration is said to have followed this operation; and after one year and a half's stay in the Hospital, she left for the Margate Infirmary, which she quitted in another year and a half with a stiff but useful limb.

For the twenty-two years following the limb had been to her a useful member; the only inconvenience experienced being that arising from a stiff joint. Some slight degree of mobility, however, is said to have existed.

Two years ago she received an injury to the knee from the butting of a calf. Inflammation and suppuration followed, succeeded by disintegration of the joint. In this condition she was admitted into Guy's under Mr. Hilton, who amputated the limb on the 24th of January.

On making a vertical section of the joint in the recent specimen, the surfaces of the tibia and femur were evidently excessively vascular. No signs of cartilage were visible, and the bones and muscles were found much degenerated.

The patella was firmly ankylosed with bony material to the femur; and the surfaces of the tibia and femur were intimately adapted to one another, the spicula of bone upon one surface corresponding most correctly (suture like) with the depressions upon the other.

These appearances, together with the fact that for twenty-two years perfect use of the stiffened limb had been enjoyed, render the opinion that osseous ankylosis had taken place more than probable. At any rate, that the new product enjoyed less power of resistance to the inflammatory action is well demonstrated, as the blow proved quite sufficient to induce its degeneration or decay.

Mr. Bryant, 19*th of February*, 1856.

15. *The Parts involved in an Excision of the Knee-joint, showing Abscesses in the Head of the Tibia.*

These had been taken from a case in which, in an excision of the joint, the femur had, on section, been found so much diseased as to necessitate amputation. The patient, a boy, æt. 9, of delicate aspect, had been the subject of chronic disease of the right knee for four years. The first symptom had been aching pain, which slowly increased, and was, after some months, followed by swelling. For a year past the knee had been bent at an acute angle, with partial dislocation of the tibia outwards and backwards. No severe pain had ever been experienced, but there had been occasionally startings of the limb during sleep. Until within a month of the operation, no abscess had ever broken externally. When placed under Mr. Hutchinson's care, the history given was, that for the last six months the joint had been getting much worse, and that the boy's health was failing. The parents were then willing that the limb should be removed; a measure which, when recommended by another surgeon a year ago, they had refused. Believing the case a suitable one, Mr. Hutchinson advised an excision of the joint. In the performance of that operation the following condition of parts was found :—The articular cartilages were removed in every part; and the opposed surfaces of bone, except where united by adhesions, were in a state of caries. There was a deep ulcer extending into the patella, the cavity of which would have contained a filbert. In the left side of the head of the tibia was a cavity, into which, for a depth of half an inch, the first joint of the finger entered easily. The condyles of the femur having been sawn away, two patches of yellowish material infiltrated into its cancellous tissue were seen; and also the cavity of an ill-circumscribed collection of pus. A second slice of the bone having been removed, a nearly similar description of things was still found, a small abscess, lined by tough lymph, and capable of holding a small nut, having been opened. It was thus made evident that, unless by shortening the limb to an extent which would make it useless, it would be impracticable to cut away all the diseased

bone. Amputation was accordingly decided upon and performed.

The pathological interest of the specimens consisted in their showing several distinct abscesses in the bone; and in the circumstance that the existence of these had not been rendered probable by the severe pain usual to such disease.

Mr. HUTCHINSON, 19*th of February*, 1856.

---

16. *A Cast showing a rupture of the Ligamentum Patellæ subsequent to Fracture of the Patella.*

The patient from whom the cast was taken is now under the care of Mr. De Morgan, in the Middlesex Hospital. He is a sailor, æt. 23, slightly made, but tolerably muscular. In August, 1854, he fell on to the quarter deck of his ship, and fractured the left patella transversely. For this accident he was eleven weeks under treatment in the Naval Hospital at Therapia, during which time there appears to have been some inflammation about the knee, as a cicatrix now remains on the outer side of the joint, near the lower end of the patella, caused by the opening of an abscess in that situation. He made a good recovery, and was able to walk tolerably well till the 1st of November last, when he slipped on a stone and fell, feeling at the time something snap, as he describes it, in his knee. Being quite unable to walk, he was carried into the Middlesex Hospital.

The condition of the knee in the extended position is as follows:—

First, there is the upper and larger fragment of the patella; then a depression of about an inch, corresponding to the ligamentous union of the former fracture; then the lower fragment, which has rather a sharp inferior edge, followed by a complete gap where the ligamentum patellæ should be situated. On comparing the two fragments of the patella on the left side, with the sound one on the right, it appears that there is an increase of length in this bone, which seems to be due to an encroachment of osseous matter on to the ligament, as the lower extremity, instead of being pointed or round, is broad and abruptly truncated. It is not improbable that this change has been going on

in the ligament since the time of the first accident; and the rupture has now taken place at the point to which the ossification had advanced.

In connexion with this case I may refer to two remarkable cases of rupture of the ligaments of both patellæ, related by Mr. Shaw in vol. v. of the Society's "Transactions," but I do not know of any other instance in which, on the patient's meeting with a second accident, the ligamentum patellæ has given way instead of the new ligamentous union between the fragments of the bone, as not unfrequently occurs.

Mr. W. H. Flower, *4th of December*, 1855.

---

17. *Crude Tubercle in the Tibia.*

T. H. æt. 21, of strumous temperament, a banker's clerk, first felt pain in the upper part of the right leg, below, and to the side of the knee, eighteen months ago. In this situation an abscess gradually formed, which was opened four months after the first occurrence of pain. Since then the leg has not been used. Swelling around the knee-joint now set in, but no positive sign of articular disease could be detected. The discharge from the abscess continued. Startings of the limb at night were now complained of, and about seven months ago bare and softened bone was first detected by the probe through the opening below the knee. Abscesses formed in the lower part of the thigh, which were opened, and discharged freely; but no bone came away. The general health gradually became undermined, hectic set in, and on the 10th of October amputation of the thigh was performed.

Dissections of the bones and joints.—On sawing through the upper part of the tibia, the cancellous tissue of the upper end of the shaft is found to contain a large deposit of tubercle about two inches long by half an inch broad; from this a small tract of infiltrated tubercle runs up through the head of the bone till it reaches the spine. Throughout the substance of the external tuberosity tuberculous masses, about the size of pins' heads, are profusely scattered.

On examining the posterior part of the bone, it was found

that there was an outgrowth of cancellous bone beyond the compact region, which looked as if it were contained between two layers of soft bone. The cartilage covering the inner tuberosity of the tibia is nearly sound. That incrusting the external tuberosity is softened and pulpy towards the middle, and is partly detached from the subjacent bone. The semilunar cartilages are softened; the synovial membrane is thickened and vascular. The spine of the tibia is bare and rough. The patella and femor are healthy. Soft structures outside joint are infiltrated with much plastic matter.

Microscopical examination.—The affected bone is generally of a light yellowish colour, contrasting strongly with the deep pink of the surrounding congested cancellous tissue. It is soft, and from the interstices of its cancelli, which are expanded, masses of tuberculous matter can be readily picked out. This, when examined under the microscope, presented,—1. The debris of cells. 2. Multitudes of small cells of about half the diameter of pus corpuscles. Their outline varied much, some being polyhedral, triangular, or oblong; some perfectly round. Many had a well marked outline through greater part of their circumference, but appeared broken in the rest. The perfect cells had a clear, well-defined outline. Their contents being finely granular. Mr. Erichsen, 16*th of October*, 1855.

Report on this specimen.—Mr. Gray reported that the general description of the specimen, as given by Mr. Erichsen in his paper, as well as the microscopic account of the structure of the deposit, corresponded in every respect with what had been observed by him; the specimen represented a well marked example of tubercular infiltration in the substance of the cancellous tissue of the shaft of the tibia; the structure of the deposit presented a marked contrast with pus, to which it was supposed to bear a great resemblance, presenting all the elements peculiar to tubercular deposit.

Mr. Gray, 9*th of November*, 1855.

18. *Cysto-myeloid Tumor of the Upper Head of the Tibia.*

A. W. æt. 12, was first seen by Mr. Shaw, 6th of March, for a swelling below the right knee. At Christmas she had slightly injured that leg while swinging. Early in February, she began to complain of some uneasiness in it; but the medical attendant of the asylum of which she was an inmate being unable to find any cause for it, she was allowed to go about as before. As the pain continued, the leg was examined more than once: but it was not till the 25th of February that, at the head of the tibia, to the inside of the tubercle, a small rounded swelling, of the same size as that process, was discovered apparently protruding from the bone. When Mr. Shaw visited her, not only was there lobulated enlargement of the head of the tibia, inwardly and outwardly, but a considerable mass of tumor projected into the popliteal space. On the 11th of March, the President of the Society saw her in consultation; and it was agreed to amputate the limb above the knee, without delay. She was admitted into the Middlesex Hospital under Mr. Shaw; and the operation was performed on the 13th of March.

Description of the tumor.—The specimen showed an irregularly lobulated tumor surrounding, and growing out of, the upper head of the tibia. The section presented a pale yellowish colour, mixed here and there with opaque white. Interspersed in the tumor, which had a firmness like that of healthy kidney, but of greater toughness, were a few cavities or cells, of a compressed shape, varying in size from that of a kidney-bean to a small field-bean, and filled with a clear amber-coloured fluid. One of these cysts was opened in making the section of the head of the tibia; and, in a circumscribed part, the interior was occupied by a morbid structure continuous with that lobe of the tumor which had been observed, before the operation, in front of the bone. In no part of the tumor did the cut surface exude any juice on pressure. On dissecting the muscles, tendons, and fasciæ from off the tumor, it was remarked that, however closely the morbid structure invested the head of the tibia, as if growing from its interior and from the periosteum,

none of these parts showed any disposition to adhere to its external surface; and the head of the fibula had been pushed to some distance out of its socket, by the interposition of a lobe of the tumor.

Microscopical report, furnished by Mr. Sibley and Mr. Flower.—The microscopical examination of the tumor was made almost immediately after its removal, and at this time the walls of the cells exhibited a transparency and delicacy of outline, which was rapidly lost, the whole becoming opaque and granular. As the cysts presented nothing unusual in their characters, attention was particularly directed to the solid portion of the tumor; the microscopical elements of which exhibited considerable variations in different parts; though these differences were the result more of their degree of development, than of a difference in the nature of these elements.

The less firm portions consisted almost entirely of bodies resembling free nuclei, packed closely together in a granular matrix; and with these nuclei fusiform cells were associated, but in different proportions in different parts of the tumor. The latter resembled very closely the cells of recent lymph; they were elongated and sometimes even attenuated into a fibre; their contents were granular, with generally one, but sometimes more than one nucleus, which was oval, sometimes oat-shaped, and contained one or two spherical nucleoli. Some of these fusiform cells, which were larger, appeared to form a transition towards the myeloid cells, presently to be described.

The free nuclei were mostly more or less oval in shape, but some were nearly spherical, and others much elongated; the greater number of them were tolerably uniform in size, being somewhat larger than pus corpuscles; though some were considerably smaller, and others attained three or four times that size. They almost invariably contained nucleoli, usually one or two, but in some of the larger ones as many as ten or twelve could be counted.

In some portions of the tumor were seen groups consisting of from two to twelve of these nuclei embedded in the granular

matrix, and surrounded by a cell-wall: these resembled the polynucleated cells found in marrow and bone; and which are described as forming the bulk of the tumors denominated "myeloid" by Mr. Paget: though in the case under examination they were but sparingly distributed, many sections having been made in which none were discovered. In some cases, groups of these nuclei were seen held together by granular substance, but apparently not surrounded by a cell-wall.

The hard portions of the tumor appeared to be undergoing a process of ossification very similar to that which is observed in fœtal cartilage; the matrix appeared to be the seat of calcareous deposition, and thus the nuclei becoming surrounded by osseous matter, constituted imperfect lacunæ. In no portions of the recently formed bone, was any tendency to the development of canaliculi observed.*

Mr. SHAW, 18*th of March*, 1856.

Report on this specimen.—The results of the microscopic examination of different parts of the tumor and the affected bone, agree so closely with those just described, that it is unnecessary to repeat the description. The greater part of the growth consists of fibro-plastic elements only, but the presence of myeloid cells in certain positions is most certain. In some of the softer and more discoloured portions of the growth, seen in close connection with the outer layers of the bone, these myeloid cells may be found in great perfection and in tolerable abundance, and in certain other parts of it at some distance from the bone itself, they may also be discovered very sparingly interspersed amongst the elongated and mononucleated cells of fibro-plastic structure. In the whiter and firmer parts of the tumor, however, which constitute by far its greater portion, and which grows to a considerable distance from the bone, a careful search does not

* July 1, 1856. A. W. was discharged to-day. From a portion of the end of the bone having become necrosed, there has been delay in the healing of the stump. Her health has continued uninterruptedly good since the operation. On a careful examination, no sign of a return of the disease could be detected in the stump, or elsewhere. Sept. 10th, she continues in good health.

discover any of the many nucleated bodies or characteristic cells.

Whilst, therefore, our examination has been, in respect to the cell elements of the tumor fully corroborative of the previous description, we yet differ from the gentleman by whom the specimen was brought before the Society, as to the name which ought to be given to it; inasmuch as the myeloid cells are very few indeed in comparison with the fibro-plastic ones; as they do not exist at all in the great bulk of the growth; and as they are met with almost solely in those parts which have been formed in close connexion with bone structure, they seem of not sufficient relative importance to be allowed to confer a name upon the tumor. Instead of the term Cysto-myeloid, we are of opinion that the name Fibro-plastic, with cysts and myeloid structure, would much more accurately designate it.

With regard to the part in which the tumor has originated, it is not in its present condition possible to form an accurate opinion. The outer layer of the bone is destroyed and split up, the cancellous tissue is much indurated in parts, and in others soft and spongy, as if from infiltration of the morbid deposit within it; in some parts the periosteum has been lifted away from the bone by considerable portions of the tumor, which have grown beneath it, and in others there are distinct growths from its outer surface. The present state of the specimen would suggest, therefore, that the diseased formation commenced coincidently external to the periosteum, beneath the periosteum, and within the bone itself.

Mr. Henry Gray and Mr. Hutchinson.

---

19. *Parts removed in an Excision of the Elbow-joint.*

A. H. æt. 47, an emaciated and very cachectic woman, was admitted on the 26th of January, at the Metropolitan Free Hospital. The right elbow was very greatly swollen; there was fluctuation on each side the tendon of the biceps; and on the inner side the skin was threatening to give way. She stated that the disease had commenced spontaneously as a "contraction

and stiffness" of the joint about seven months before. Two months later swelling began, and from that time she had suffered great and increasing pain. For the last two months the pain had been of a gnawing character, so severe that her nights had been almost sleepless.

The treatment pursued had consisted chiefly in repeated blistering. It had afforded no relief, and amputation had been advised by the surgeon last consulted.

The abscess on the inner side of the biceps was opened freely, and an opiate and tonic treatment ordered. A probe could be passed into the joint, but did not discover any bare bone.

On the 8th of February, the pain having rather increased than otherwise, and her strength plainly giving way, it was determined to excise the joint. The patient having been put under chlorform, a more careful examination was made. No grating could be produced by moving it; nor did the probe, which, at a depth of about two inches and a half, evidently entered the joint, detect any carious bone. The swelling was very great, and surrounded the whole articulation, so as to entirely conceal all prominences. There was also much œdema of the fore-arm and hand. The ⊢ shaped incision was practised, and the articular extremities of the three bones sawn away. The joint was found to contain a small quantity of pus and much loose flocculent lymph. The depth of inflamed tissues which had to be cut through, was in no place less than from an inch and a half to two inches. Several small collections of matter extending into the joint were opened. Not much blood was lost, and no vessels required ligature. Two sutures having been applied at the extremities of the incision, the limb was laid in a pillow in the semi-flexed position.

No material effects followed the shock of the operation; and, during the next fortnight, the woman was remarkably comfortable, the gnawing pain from which she had suffered being entirely absent from the day of the operation. She took food well, and had good nights.*

The specimen brought before the Society consisted of the

* The result of this case will be communicated to the Society at a future Meeting.

three bones in a recent state. The chief disease was in the greater sigmoid cavity of the ulna. The edge of the cartilage of this part was everywhere eroded by commencing ulceration; and in the middle of the cavity a narrow band extended across the joint, from which the cartilage had been entirely removed. At the inner extremity of this was a patch about the size of a fourpenny bit, in which the ulcerative process had extended into the bone for the depth of about a quarter of an inch. The bone itself was not softened. The head of the radius appeared healthy in every respect, its cartilage being sound, and adhering firmly. The articular surface of the humerus was everywhere invested by its cartilage; but the latter was easily detached, and evidently did not adhere to the bone so well as in a state of health. At the edges of the cartilage in several places were narrow irregular margins of ulceration. The synovial membrane was everywhere much thickened and very vascular.

Comments.—The disease exemplified by this specimen appeared to be the commencement of a late stage of articular disorganisation. The inflammation had, doubtless, been originally synovial, and of the form which occasions dryness of that membrane rather than increase of secretion. In this the ligaments and the surrounding soft parts had next been involved; and lastly suppuration having ensued, the ulcerative removal of the articular cartilages was just commencing. There was no reason whatever for connecting the diseased action with any strumous predisposition; it was rather one of those destructive forms of inflammation to which, without any tuberculous taint, the feeble and cachectic are liable. The diagnosis of ulceration of cartilage had been confidently formed from the character of the pain suffered, and the severe constitutional disturbance, although no grating could be produced between the ends of the bones. The operation was undertaken in the belief that, from the patient's very feeble health, there was little chance of arrest of the disease, and that if delay were allowed, until by continued suffering the strength had been further undermined, the probability of a favourable result would be greatly diminished.

Mr. HUTCHINSON, 19*th of February*, 1856.

---

20. *Pendulous Ossific Growths in the Elbow-joint.*

These are two oval masses of true bone, one about the size of a pea, and the other half as large again. They are suspended by slender pedicles of synovial membrane from the upper part of the olecranon fossa. On section they present a cancellated structure, and had their origin, apparently, in the synovial fat of the fossa, and external to the lining membrane. They did not interfere with the motion of the joint.

Mr. JOHN WOOD, *4th of March*, 1856.

VII.—DISEASES, ETC. OF THE ORGANS OF SPECIAL SENSE.

1. *Large Malignant Tumor growing from the Orbit.*

G. P. æt. 10, admitted into the Metropolitan Free Hospital under the care of Mr. G. Borlase Childs, in the beginning of March, 1856. His disease was a fungating growth of enormous size, projecting from the right orbit. Externally the mass, which nearly equalled the head in dimensions, was divided by shallow depressions into lobules, and its surface was everywhere covered by a layer of greyish slough. The upper lid was continuous with its superior surface, being adherent to it, and dragged forwards. The lower lid was not involved, and when the mass, which hung over the cheek, was lifted up, it might be exposed together with the remains of the collapsed eyeball, which latter was partially embedded in the under surface of the base of the tumor. There was considerable œdema of the right temple, and several large tortuous veins passed from it on to the base of the growth. At first sight it might have been supposed that the tumor had a diffused base of attachment all round the orbit; but on careful examination it did not appear that the swelling of the temple, eyebrow, &c., was other than simple œdema, and the ease with which the mass might be lifted upon its pedicle, seemed to show that its base involved

only the upper lid, and the structures in the upper half of the orbit. There were no enlarged glands in the neck, nor any signs of thoracic or abdominal disease. To the touch the mass was moderately firm and tough, but not hard. The boy was miserably thin and cachectic, pale to a degree, and so feeble that he could scarcely walk. He had not suffered from any head symptoms beyond occasional fainting, which was accounted for by his extreme anæmia.

The disease had existed for six months, and had progressed very rapidly. In October last, whilst under care in another Hospital, the following notes of the case had been taken by Mr. Hutchinson. "5th of October, 1855.—He is a fair-complexioned, remarkably intelligent boy, an only son, and of a family in which there is no history of malignant diseases having ever occurred. He states that he was in perfect health until a month ago, when in a scuffle with some other boys he was knocked down and severely struck over the right eye. So much swelling followed, that on the next day he was taken by his mother to a surgeon, who ordered fomentations. A week later the surgeon stated 'he was afraid something was forming,' and advised a consultation with Mr. Critchett, of the Royal Ophthalmic Hospital. The tumour now very rapidly increased, everting the upper lid, and covering over the eye. At present the mass is as large as a child's fist, and is covered by the everted lining of the upper lid; the eyeball, which is quite sound, and has free motion, is considerably pushed forwards, and concealed from sight by the overhanging growth. The tumor is tense and rounded, but not hard, and there is a false sense of fluctuation in several parts. No material pain has attended its growth, but the boy is feverish, restless, and rapidly losing flesh." An operation having been declined, in the belief that the disease would certainly return, the boy left the Hospital about six weeks after admission.

At the time of the boy's application to Mr. Childs, the inconvenience caused by the great size of the growth, its fœtid discharge and liability to frequent hæmorrhages, was such as to make it extremely desirable to attempt something, even for the purpose of obtaining a relief, which could only be temporary.

The mere weight and size of the tumor were such as to prevent the boy from obtaining rest in any position for long together. There did not seem any reason to apprehend that the entire mass could not be got away; and the main risk appeared to be lest the boy, in his exsanguined condition, might not be able to bear the loss of blood which would necessarily be incurred. No doubt was felt as to the malignant nature of the disease; but after full consideration, it was determined, nevertheless, for the sake of getting rid of its inconvenience, to attempt its excision.

The operation was performed on the 3rd of March. The incisions included the whole of the upper lid and part of the integument of the temple; the tumor, the eyeball, and the entire contents of the orbit being removed. During the removal, rather profuse hæmorrhage, chiefly of venous blood, took place. The actual cautery was freely applied afterwards, and the orbit having been stuffed with lint, a bandage and compress were placed over the part. No further trouble on account of bleeding occurred. At the conclusion of the operation the boy was very faint, but a brandy enema having been given, he rallied well, and in the course of a few hours was in a comfortable condition.

On dissection of the excised mass, it was found to have very indefinite boundaries, and in the upper lid especially, the margin where the structure of the growth itself ended was with difficulty distinguished from the adjacent cellular tissue, which was in a condition of solid œdema. It was, however, quite clear that the whole of the growth had been removed, the incisions having passed through healthy tissues at some distance from its limits. The eyeball itself was nowise involved, but was collapsed from pressure. The muscles, cellular tissue, fat, &c., of the lower and back part of the orbit were quite healthy, the growth having evidently commenced in the upper lid, and extended but little into the orbit. On section, the surface of the tumor was seen to be marked into large lobes by curved bands of white fibrous tissue; its aspect was opaque, and of different shades of greyish yellow and white. Its texture was everywhere of a considerable degree of toughness; although soft, and readily yielding to pressure, it was elastic, and did not break down under the finger. It yielded no creamy juice, and

DESCRIPTION OF PLATE XVI.

Figures 1 and 2 illustrate Mr. Hutchinson's report on Mr. Borlase Childs's case of Malignant Tumor of the Orbit, p. 324.

Fig. 1. Microscopic characters of the tumor as seen with a magnifying power of 400 diameters.

Fig. 2. The same elements on the addition of acetic acid.

Figures 3 and 4 illustrate the microscopic appearances in Dr. Ogle's case of Amaurosis, p. 334.

Fig. 3. Shows the microscopical appearances of portions of the optic nerve, all the nerve tubes being destroyed.

Fig. 4. Shows the microscopical appearances of portions of the optic tract the nerve tubes being partly destroyed; in some cases containing much granular fat and oil globules; in other cases nothing but a uniform cylinder existed without any traces of the original anatomical characters. Magnified 300 diameters.

Figures 5 to 8 illustrate Mr. Sibley's case of Multiple Fibrous Tumors, p. 340.

Fig. 5. Portion from the tumor in the thigh.

Fig. 6. Portion from the tumor near the kidney.

Fig. 7. Portion from one of the tumors in the liver.

Fig. 8. Nuclei from the same.

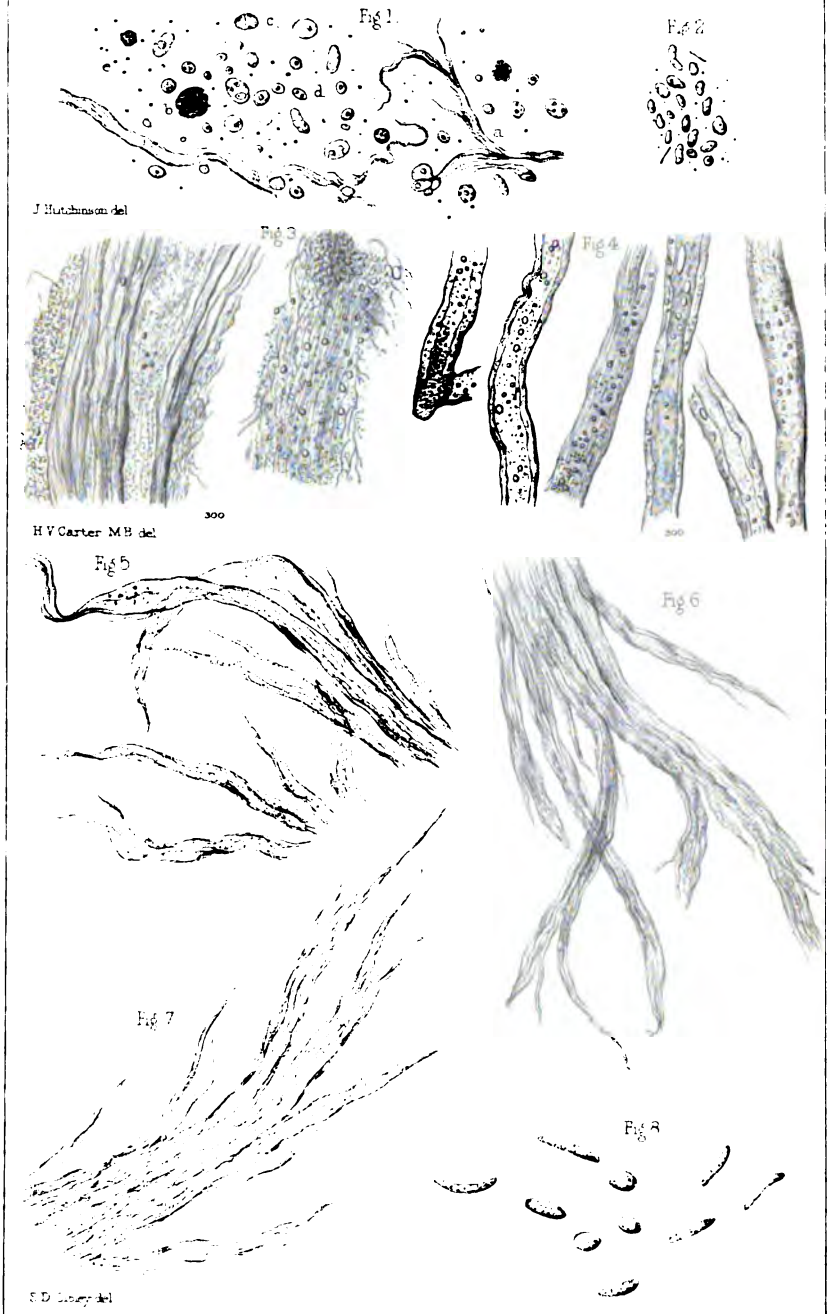

Jeffers West sculp

W West imp

pressure obtained an almost clear serum, as if from structures in a state of œdema. After a somewhat prolonged examination with the microscope, Mr. Hutchinson was able to discover only the elements of a fibroid or fibro-nucleated growth. No cells in size much beyond that of a pus corpuscle were seen, nor any possessing more than one nucleus. Its elements were,

1. Well-formed areolar tissue in waved bands (Plate XVI. Fig. 1 *a*.).

2. Granular bodies of dark appearance, not possessing any visible nucleus, and usually having their cell wall more or less broken (*b*), few in number.

3. Mononucleated cells of dim granular aspect, and about the size of pus corpuscles (*c*), very abundant.

4. Free nuclei, very abundant (*d*).

5. Minute spherules of fat or oil (*e*).

6. Granular matter.

Treated with strong acetic acid, the cells and nuclei shrivelled and assumed the appearances shown in Plate XVI. Fig. 2.

The progress of the case was for three weeks after the operation most satisfactory. The orbit rapidly filled with healthy granulations, and the boy regained his strength and flesh in a remarkable degree. At the end of that period, however, the wound being then not quite healed, there were evidences of a return of the disease over the inner angle of the orbit. It was quite painless, and although it grew rapidly, yet the boy continued for some time longer to gain flesh. In the course of about three months, however, it had attained a bulk almost equal to that which it had prior to the operation, and was again covered with a layer of slough, and liable to frequent bleedings. The glands in the neck had also enlarged, and had become adherent to the skin. At this juncture, all further interference being out of the question, the boy left the Hospital. Death took place about six weeks after he left the Hospital. An autopsy was not permitted.

Mr. HUTCHINSON, for Mr. G. B. CHILDS, 18*th of March*, 1856.

Report on this specimen.—The tumor* exhibited by Mr.

* The specimen was examined three weeks after its removal, and it had been kept in the meantime in weak spirits and water.

Hutchinson for Mr. Borlase Childs, was a large and somewhat lobulated mass. It presented throughout its entire substance a milk-white colour. It yielded but little creamy juice, and, indeed, that which was obtained by scraping the cut surface, appeared to be less a real juice than a collection of minute fragments of disintegrated tissue. Its consistence varied in different parts. In some it was tolerably firm and dense; in others, it was soft and almost pulpy; but in the greater part of its extent it had much of the tough yet flabby character of a collapsed lung.

Under the microscope, it presented several elements, the proportions of which varied in different parts:—

1. *Nuclei.*—These bodies were round, ovoid, or somewhat irregular in form, and between $\frac{1}{3000}$th and $\frac{1}{4000}$th of an inch in diameter. They contained nucleoli, but were not themselves (except in rare instances) contained within cells.

2. *Fibro-plastic cells.*—These were fusiform and much elongated, and contained long oval nuclei.

3. *Fibroid tissue.*—The structures included under this term presented considerable varieties of character. In some parts of the tumor there was distinct white fibrous tissue, in some elastic fibres, and in many places a delicate fibroid network, not very unlike that produced by the coagulation of fibrin. The greater part of the fibroid matrix, however, consisted of that kind of tissue which is commonly seen in scirrhus; that is to say, of a fibroid structure consisting of dense glistening trabeculæ, variously arranged, and giving off fibres in all directions.

4. *Oil.*—This was present in the form of globules, the size of which varied from $\frac{1}{2000}$th or $\frac{1}{3000}$th of an inch in diameter downwards.

In the firmest portions of the tumor, the fibroid tissue was in excess, and the nuclei could be seen occupying round, or ovoid, or fusiform spaces between the fibres. In those portions, the consistence of which was of intermediate character, the fibroid tissue was tolerably abundant, but it was more or less concealed by the nuclei, which were very numerous—in one place arranged in more or less definite masses—in another diffused with some appearance of uniformity through the tissues. In the softest portions of the tumor, the cells and spaces between

them were studded more or less thickly with oil, so that the pulpiness appeared to be the result of degeneration. The fibro-plastic cells, clustered more or less together, were found here and there, and evidently formed a part of the fibroid element of the growth, but they were not found in equal numbers in all parts, and in some there was evidently an absence of them.

On considering the microscopic and the naked eye characters of the above tumor, I cannot resist coming to the conclusion that it was decidedly malignant. And I come to this conclusion because, on comparing all the forms of tumor with which I am acquainted, it appears to me that the microscopical structure of this growth accorded less closely with that of tumors which I have had every reason to regard as innocent, than with that of tumors which I have known, or have had strong grounds for believing, to be malignant. Nuclei, such as were observed in this case, constitute, according to my experience, the form of cell-growth which is most common in rapidly growing cancerous tumors, if not the form which is most characteristic. And their arrangement, in relation to the fibrous matrix, was in conformity with this view. In the denser portions of the tumor, the nuclei were arranged in much the same way that one finds them arranged in scirrhus; and in the softer parts, in much the same way that one finds in encephaloid. At the same time, there were some peculiarities in the growth under consideration which serve to distinguish it in some respects from well-marked scirrhus, on the one hand, and form well-marked encephaloid on the other. It was decidedly not so firm as scirrhus usually is, and it was undoubtedly nothing like so pulpy and soft as we commonly find encephaloid to be; neither did it yield any satisfactory amount of creamy juice. Still peculiarities of this sort, depending partly on the tissue in which the growths originate, and partly on the relative proportion of their fibroid and cellular elements, are so commonly observed in malignant tumors that they cannot, at least in the face of more positive evidence, be admitted as arguments of much weight against the cancerous nature of tumors in which they may be found to exist.

Dr. Bristowe, *6th of May*, 1856.

2. *On the Cortical and Nuclear Cataracts of Adults.*

The preparations which I exhibit are of cataracts extracted from patients from forty to seventy-seven years of age. They were all of the usual description occurring in such subjects, and admitting of the operation of extraction. The majority were of the variety termed cortical cataract, in which the opacity commences in the superficies of the lens; a few, were nuclear cataracts,—that is to say, the opacity had been observed to commence in the nucleus, and the superficies was but little affected at the time of operation. The eyes from which they were extracted were in other respects healthy.

Before making a few remarks upon the appearances observed, I would call the attention of the Society to two points in the microscopical anatomy of the healthy lens, because it is only by constant reference to the healthy structures that we can properly appreciate the changes affected by disease.

And first I would advert to the existence in the superficial layers of a quantity of very delicate wavy fibres, closely resembling the white fibrous tissue in other localities, but much finer (Plate XV. Fig 7.). They are found partly involving and surrounding the proper cells of the lens, and partly overlying the tubes in the form of a fine web or expansion. They are not alluded to in the ordinary English works on the anatomy of the lens, though they are, perhaps, what are meant by several foreign authors, whose descriptions are somewhat discordant.

Secondly, I have frequently observed an appearance which seemed to offer strong, if not conclusive, evidence as to the tubular nature of what are commonly called the lens-fibres, which is still denied by some anatomists. It is as follows:—On first examining a thin plane of fibres from the superficies of the lens, it seems impossible to decide, by looking at their torn extremities, whether they are solid or hollow. But when they have remained for some little time on the slide, a number of pellucid globules will be found to have collected around the torn ends, and, by careful watching, these may be seen slowly to increase in size. If the covering-glass be manipulated so as to direct a current of water past them, they will be seen to

elongate into a pyriform shape, until they are washed off by the force of the stream; or if they be exposed to the action of dilute muriatic acid, they instantly coagulate into solid, granular masses. The conclusion appears to be legitimate, that these globules are composed of a viscid albuminous fluid, pressed from the hollow interior by the collapse of the walls of the tubes, or by the pressure of the glass with which they are covered.

Since making this observation, I find that the same appearance has been recently described by M. Robin, and that he interprets it in a similar manner.

In cortical cataract the superficial layers of the lens are converted into a soft, grey, semi-fluid pulp, part of which mixes readily with the fluid in which it is placed for examination, so as to render it turbid. The tubes that have escaped disintegration, separate from each other, and break into short fragments with the slightest touch of the needle; thus contrasting strongly with the tubes of the healthy lens, which are tough and elastic, and cohere so that it requires some dissection to separate them from each other. In the specimens of nuclear cataract which I have examined, indications of a similar change in the superficial layers have always been present, though in a much less advanced stage; and by watching the progress of such cataracts in cases where extraction has been delayed, it may be seen that time alone is required to complete the change.

A still more remarkable change of consistence takes place in the nucleus, and that, so far as I have observed, in the cortical as well as the nuclear variety of cataract.

In the healthy lens, the nucleus is well known to increase in density with advancing years; but I have never found it, even in very old people, to have a greater consistence than that of strong jelly; and, however highly coloured it may be, it is clear, sparkling, and transparent.

In cataract, when fully developed, the nucleus becomes exceedingly hard and dry. As a rough test of the consistence, I generally divide it by pressing the dissecting needle (the finest sewing needle that is made) through it. Considerable force is required to effect the division—in one instance, in a

cataract from a man, æt. 77, so much so, that the needle, which was very slightly rusted, actually broke. The divided surfaces present the appearance of a fracture rather than of a cut, being rough, dry, and crumbling. I have not been able to observe that the degree of hardness was in any measure influenced by the age of the patient; it was well marked in a lens which I recently extracted from a patient, æt. 41; it has rather seemed to be proportioned to the duration and state of advancement of the cataract, though on this point I speak with great hesitation. But however this may be, it appears to be one of the most curious phenomena of the disease, that there can be such an absence of moisture in a structure which is constantly enveloped in a nearly fluid medium.

On examining the soft grey pulp, of which the outer part of a cataract is composed, with the microscope, we find a quantity of fine molecular matter, partly floating free, partly aggregated in masses, and partly adhering to the exterior of the tubes, so as to render them more or less opaque. Whether any of it is contained within the tubes, I have not been able to determine. This appears to be the result of the coagulation of the albuminous fluid in which all the lens-tissues are immersed. It is exactly similar to what is produced in albumen from other sources, *e.g.* the white of an egg, when it is coagulated under the microscope by a weak acid; and it can be perfectly imitated in the healthy lens by a similar process.

More or less change is also found in the large cells of the superficies of the lens—the "globuli lentis" as they are called (Plate XV. Fig. 8.). Many of them are rendered opaque by fine granular matter in their interior. This also is probably owing to the coagulation of their contents, and can be imitated in the cells of the healthy lens by the addition of dilute muriatic acid. Other cells are altered in shape—bent, twisted, and crumpled in various directions, in a manner which I have not observed in the healthy lens. They are generally yellow in colour; and the tinge is deepest in those which are most altered from the normal forms.

In every specimen which I have hitherto examined, I have also noticed a number of cells of very irregular and eccentric shapes, which it is difficult to describe in general terms, as

scarcely two of them are alike. Some have a number of concentric markings; others appear as if they consisted of several cells compressed and crumpled together, and surrounded by a common cell-wall; others have several nuclei; and many are so irregular as to defy description. Their walls are generally highly refractive and appear to be thick and hard, resisting the action of dilute acids for a long time, and maintaining their characteristic appearance long after the rest of the preparation has become indistinct. I have hitherto failed to discover such cells in the healthy lens, but at present would merely call the attention of the Society to them, as I may be mistaken in considering them as characteristic of disease.

The tubes of the cortex are, as has been already said, studded with, and more or less obscured by, minute granules. The principal evidence of their softening is derived from the facility with which they break into short fragments. Those that remain entire generally retain the smoothness and regularity of their outline; but I have occasionally found a few of them bulging and irregular, as if yielding to the slight pressure of the covering-glass.

In one or two instances I have observed tubes, whose extremities appeared to be split up into a number of fibrils. I have suspected that this might be a fallacy, occasioned, perhaps, by their being overlaid by some of the fibrils already described as existing in the superficial layers; but I have recently seen that the same appearance has been noticed by M. Robin, and described by him as fibrillation of the tubes. This is a point which may, perhaps, be cleared up by the observations of some members of the Society.

The tubes of the nucleus are hard and brittle. Their cohesion is gone, and they separate from each other on the slightest touch. They are loaded with a fine granular deposit, and nothing can be more irregular than their outline, disfigured, in some places, by little tubercles and nodules, and in others nearly divided by deep clefts and fissures. Their broken extremities are rough and jagged, and there are numerous transverse markings like little cracks; in more than one instance, also, I have observed longitudinal markings, as if there was a tendency to

split into fibrils. Individual tubes sometimes appear tolerably transparent; but when collected in layers of two or three, their opacity is evident. Many of them are small and shrivelled, as if atrophied.

In none of the cases upon which the above remarks are founded, have I seen oil-globules, crystals of cholesterine, or other evidence of fatty degeneration. These have been found in abundance in fluid cataracts; I have myself seen cholesterine in large quantities in the remains of lenses destroyed and converted into cretaceous masses by slow disorganising disease; and I have no doubt that the same may be seen in any cataract of long-standing, in which vitality has long ceased. But I have not seen any evidence to favour the opinion that cataract, in its more ordinary forms, is dependent on, or in any measure connected with, fatty degeneration.

And it should not be forgotten that the healthy lens contains a considerable quantity of fatty matter as one of its normal constituents; and the cholesterine of this fatty matter has a strong tendency to separate by crystallization after death, or in imperfectly preserved microscopical preparations, as illustrated by one of the slides exhibited. Its appearance, therefore, in old disorganised lenses, which have long lost their vitality, may, perhaps, be considered in the light of a physical rather than of a pathological phenomenon.

Mr. Robert Taylor, *6th of November*, 1856.

---

3. *Atrophy of the Optic Nerves and Tracts of both sides and of the Optic Commissure. Total Blindness for Twelve or Fourteen Years.*

The specimen showed excessive atrophy of these parts, the optic nerves being more wasted and drier than the others; all of them being of a pale yellowish-red, semi-transparent colour, instead of being plump and white. The optic thalami, corpora quadragemina, and other parts of the brain presented nothing unusual in any way, but the arachnoid was here and there thickened. The patient from whom the preparation was removed, died of disease of the heart and kidneys, having been totally blind for above twelve years, and was aged fifty-six.

Microscopical characters.—These, which were very interesting, are as follows.—The optic nerves, portions of which in different places, and at various depths, were examined, showed nothing but very fine fibrous tissue, mixed with finely-granular blastematous material and occasional oily particles (Plate XVI. Fig. 3.). In some places the granular matter, much diminished by dilute acetic acid, existed almost alone. In the optic tracts, which were less atrophied than the other parts, numbers of true nerve tubes were to be seen; but the majority of these contained many free fatty globules within them and around them (Plate XVI. Fig. 4.). In some places all the special anatomical characteristics of the nerve tubes were lost, and they simply presented a uniform faintly granular appearance throughout their entire calibre, not showing any irregularity of outline or unusual markings.

The more perfect state of the optic tracts, as compared with the nerves themselves, may be accounted for by a greater supply of blood to these parts; but nothing remarkable was noticed about the capillaries, by aid of the microscope, in any of the parts examined. Dr. J. W. Ogle, 15*th of April*, 1856.

---

4. *Extraction from the Left Ear of a Boy, of greater part of the Petrosal Portion of the Temporal Bone, including the Meatus Auditorius Internus and Labyrinth, separated by Necrosis.*

A boy from the country, æt. 7, was admitted into the Middlesex Hospital on the 31st of July, 1855, under Mr. Shaw, for otorrhœa affecting both ears. The disease succeeded a severe attack of scarlet fever, which he had two years and a half ago. From the right ear the discharge of pus was not of great amount. The left external ear projected considerably beyond its proper level, and an irregular piece of bone, surrounded with fungous granulations, protruded from the meatus into the concha. He had paralysis of the muscles of the left side of the face; for a year he had been completely deaf in both ears.

On the 3rd of August, he was put under the influence of chloroform, when Mr. Shaw first extracted the piece of bone, which projected into the concha: this appeared to have been

the posterior border of the external meatus of the temporal bone. The cartilaginous tube having been ulcerated by the pressure of the loose fragment, the point of the little finger could now be passed inwards to some depth; when another, larger, piece of bone was felt rolling freely in the cavity. This was seized by the dressing forceps, and after it had slipped once or twice, owing to its hardness and smoothness, it was extracted by employing force and a twisting motion, so as to favour its coming in a proper direction. For a few seconds after the removal dark venous blood flowed rather freely. As a precaution he was kept in bed for a week: by degrees the discharge lessened, and the ulcer of the tube cicatrised. No untoward symptoms arose; and in the end of September, except from the paralysis of the face, the deafness, and a trifling discharge from both ears, he left the Hospital in good health.

Description of the specimen.—The density of structure, weight, and shape of the portion of bone last removed, at once showed that it formed nearly the whole of the pretrous portion of the temporal bone. It was of irregular cylindrical, or rhomboidal figure; it measured one inch in length; its average thickness, in various directions, was half an inch; it weighed twenty-two grains. On one side, nearly in its centre, was an opening and cavity, with well-defined borders and walls, which was recognised to be the meatus auditorius internus. The depth of the meatus from the margin to the thin perforated plate through which the auditory nerve penetrates into the labyrinth, was three-fifths of an inch; and as that is the full depth of the cavity in its normal state, it was thereby shown that the whole of the internal meatus was included in the specimen. At the bottom of the meatus could be seen the commencement of the canal for the portio-dura. On the side of the specimen in relation with the brain, the surface presented the cancellated appearance peculiar to the diploe: whence it was concluded that, in the detaching of the necrosed part, the process of separation had taken place in the diploe—that the cortical layer had retained its vitality, and remaining in contact with the dura mater, had served as a barrier to prevent disease from extending to the cerebrum. On turning the bone round to view it in

its opposite aspect, the side then exposed was seen to be the internal wall or boundary of the tympanic cavity; it was easy to distinguish the "promontory," having above it the "fenestra ovalis," and below it the "fenestra rotunda;" the two latter openings were broken and irregular, and through the enlarged holes thus produced the interior of the "vestibule," with its foveæ, the cochlea, modiolus, and lamina spiralis, somewhat injured, were seen. At the posterior part of the specimen portions of the semicircular canals, broken off near their junction with the vestibule, stood up distinctly into view.

Mr. SHAW, 16*th of October*, 1855.

VIII.—MISCELLANEOUS SPECIMENS, TUMORS, ENTOZOA, &c.

1. *Recurrent Tumor of the Orbit, followed by similar Growths on the other side of the Head, on the Dura Mater, and under the Costal Pleura.*

S. F. a delicate child, æt. 6, was admitted to University College Hospital, under the care of Mr. Quain, on the 29th of November, 1853. Her father and mother were then living, but they have since both died of consumption.

Four months previously she received a blow on the left eye, of which, however, little notice was taken. On the 12th of October the left eyeball was somewhat protruded, and the lids congested. The pupils were equal, and acted well. Sight was unaffected. A slight pricking sensation only was complained of at the outer canthus. About the 26th of November the child complained of pain on the left side of her head, and in the eyeball; after this the sight became impaired. On the 30th of November the left eyeball, with the swollen lid, formed a hemispherical protrusion; the lids could just be closed. Both the conjunctiva and cornea were dim. The child could distinguish light from darkness, but dreaded the light.

On the 3rd of December the eyeball was removed. The tumor, about the size of a walnut, was found to be roundish,

lobulated, firm, not very vascular. On section it was smooth, and yielded on pressure a small quantity of colourless fluid. It was nearly homogeneous; its colour was yellowish grey. The central portion was slightly whiter and more opaque than the rest; it exhibited but very little vascularity. In tearing out fine shreds with needles, the tissue was found to be tough, and not to show any tendency to break up in any particular direction. Under the microscope it exhibited a fibrillated appearance; there were to be seen numerous roundish and elongated cells. The cell-contents were finely shaded; they contained a nucleus with not a very distinct outline, varying in shape with the cell, and with a fine point as a nucleolus. There were also fusiform fibres and some fibro-cellular tissue.

A tumor recurred in the orbit, and was again removed. It was rather larger than the primary one, and was very intimately blended with the periosteum. The naked eye and microscopical characters agreed very closely with those of the previous growth.

The growth again returned, and in addition, a new one appeared on the right temple, which grew steadily until it implicated the right temporal and parietal bones, and part of the frontal. It measured seven inches vertically, and the same transversely, and at the thickest portion was about one inch and three-quarters thick. It was roundish, and divided into three lobes. The right auricle was seated nearly on the centre of the mass. On one occasion it bled slightly, but it exhibited very little disposition to ulcerate, and none to form a fungous protrusion.

The patient died a very lingering death, not suffering much. She became extremely emaciated. For several months before her death she had signs of partial consolidation of her lungs, and latterly of softening.

The general characters of this new growth, when examined *post-mortem*, were found to correspond very nearly to the earlier ones. This had a slightly yellowish-green tint: near the centre of it a part was whiter than the rest, and exhibited a striated

appearance. It was very intimately blended with the periosteum, and at one part infiltrated the skin.

Similar material, which was divided into two or three roundish lobules separated by deep fissures, filled up the left orbit. In the left frontal sinuses some of the same morbid material was found. In the middle fossa of the skull, attached to the inner aspect of the dura mater, was a small mass as large as a small walnut, which pressed on the middle lobe of the brain, and had pushed aside some of the grey matter, so as to expose the white. The bone under this presented a worm-eaten appearance. This exhibited all the characters of the growth exterior to the head.

Under the right pleura was a similar patch, three inches long by one inch and a half broad, lying against the vertebral end of the eighth, ninth, and tenth ribs, and the corresponding bodies of the vertebræ. The pleura and the bones were unaffected. This exhibited the same naked eye and microscopical characters found in the other portions.

The lungs, before they were sliced, felt very much as if they contained some hard, roundish, nodular masses; but on section the right lung was found to be partially consolidated, and to be infiltrated with what, to the naked eye, appeared most distinctly to be tubercle. There was infiltrated yellow tubercle and also some grey granulations. The left lung was in part impervious to air from collapse. Some serous fluid and recent and old adhesions existed in this pleura. It was also in part infiltrated with tubercular matter, and at the apex was a small cavity. There was nothing in either lung that bore any resemblance to the growths above described. The microscopical examination of the grey granulations quite confirmed the naked eye characters. The bronchial glands were large, but contained no morbid deposit.

The kidneys were remarkably pale, and very firm in texture. They were infiltrated with a granular albumenoid deposit.

The chief points of interest in the case are the recurrence of the tumors, their infiltrating character, the absence of "cancer cells" and the formation of similar growths in several situations.

Microscopically the growths appeared to be a combination of the fibro-plastic and the fibro-cellular.

The question may be asked how far any of the growths were secondary to the others? This is open to discussion. Mr. Quain, under whose care the child was, regarded them as distinct multiple growths. The case appears to resemble in many respects some cases described by Mackenzie, in his work on the "Diseases of the Eye," fourth edition, p. 91, under the name of chloroma. He speaks of it as originally a disease of the lachrymal gland. The physical characters of the tumors appear to agree very closely; and in Mackenzie's cases, as in this, the dura mater and the lining membrane of the nasal sinuses were involved. Dr. HILLIER, *6th of November*, 1855.

---

2. *Example of Multiple Fibrous Tumors.*

These cases were brought before the Society with a view of directing attention to that very singular class of tumors to which Mr. Paget has given the name malignant fibrous tumors. The group is characterised by the complete structural homology of the tumors to the tissues of the fœtus, if not to those of the adult, joined to the history and progress of cancer. In other words, the presence of a tumor, formed of areolar tissue in one part of the body, appears to be followed by the development of similar tumors in other parts, and in the various viscera; the original tumor may, moreover, recur after excision.

Case 1.—J. B. a robust and healthy-looking labourer, æt. 65, was admitted on the 4th of July, 1854, under the care of Mr. De Morgan, into the Middlesex Hospital. The patient had discovered a lump at the inner side of the left thigh two years before. Since then the tumor had increased slowly, but regularly, in size; he had suffered from pain, which was of a scalding character. When admitted, there was a tumor of the size of a fœtus-head closely connected with the lower end and inner side of the left femur; the tumor was very firm, and slightly elastic; the surface much nodulated, and the vessels in

the skin very much enlarged. He died a few days afterwards from the effect of chloroform, and an account of the case, as regards the action of the chloroform, was published in the "Medical Times and Gazette."*

Post-mortem examination.—The tumor at the inner side of the thigh cut almost like cartilage, and presented a slightly yellowish glistening section. On scraping, a small quantity of clear serum adhered to the knife; the microscope discovered only a few granules in this fluid. The fibrous structure was obvious to the unassisted eye, and was arranged in a somewhat radiating manner. In portions, however, the tissue was much convoluted, resembling in arrangement the fibrous tumors of the uterus. The part most distant from the femur was much softer, and in one place was completely broken down, leaving a cavity which was filled with about three ounces of blood. The femoral artery passed through the middle of the tumor.

In the lower part of the biceps of the left arm, there was a tumor about the size of a walnut, which, on section, was similar to the more dense portions of the tumor on the thigh.

On opening the body, a small but similar tumor was found on the inside of the fifth right rib. There were several large and irregular patches of cartilaginous thickening of the pleuræ. Beneath some of these patches the tissue of the lung was thickened and indurated, as if from the infiltration of similar material. In the substance of each lung there were two or three tumors, none of which were as large as a nut, but which, on section, presented a similar structure to the other tumors.

In the liver there were about twenty similar tumors, which varied in size up to that of a walnut. The liver structure was healthy.

Among the other viscera nothing particular was discovered, except that the heart was much dilated, and was in an extreme state of fatty degeneration. The kidneys were slightly granular, and contained a few cysts.

* Vol. ii. 1854, p. 86.

Microscopical appearances.—The tumors were examined by myself, and by my friend, Mr. John Z. Lawrence, who has alluded to the case in his essay on the "Diagnosis of Surgical Cancer." The tumor of the thigh was formed entirely of fibres, and of fibre-cells. The majority of the fibre-cells were seen splitting up into numerous fibrillæ, having the waved appearance of the white fibres of areolar tissue. Nuclei were seen in most portions of the tumor, and in some places were extremely numerous; a large number of these were spheroidal, some much elongated. A few elastic fibres were seen with the aid of acetic acid. The fibres first mentioned were arranged parallel to one another in bundles, the bundles interlaced freely (Plate XVI. Fig. 5.).

The tumors in the liver, arm, &c. were quite similar in structure, the only difference being, that in the liver there was less splitting up of the fibres, and the nuclei were more abundant.

Case 2.—G. M. æt. 52, was admitted into the Middlesex Hospital on the 12th of June, 1855, under the care of Dr. Stewart. The patient had been suffering from a pain in the right lumbar and renal region for about six weeks; the pain was of a shooting character, passing through to the hypochondrium. The liver was found to be enlarged and tender. Hæmaturia set in about a fortnight after his admission, and after a severe attack of bronchitis, he gradually sank and died on the 29th of July.

Post-mortem examination.—Body considerably emaciated, but not devoid of fat. At the second and third left costal cartilages there was an irregular elevation of the skin, caused by a hard tumor beneath, which was continuous with a tumor in the anterior mediastinum. This tumor surrounded the trachea, and was firmly adherent to the lung; in front it passed round, but did not destroy, the cartilages of the ribs mentioned. In size, it was rather larger than a closed fist. The section was very dense, even, and glistening; it cut like cartilage, and was quite juiceless.

The lungs were firmly adherent to the costal pleuræ on both

sides. On the surface of both, but especially on the right, there were numbers of flat tumors, varying from the size of a fourpenny-piece to that of a penny. In section they were similar to the tumor of the mediastinum. In the substance of the lungs there were several small tumors of a similar nature.

In the liver there was also a large number of tumors, varying from the size of a nut to that of an orange. They were all opaque, white, juiceless, and shining.

Connected with the external coat of the vena cava, just below the renal vein, there was a small tumor of similar nature.

The upper half of the right kidney appeared to have been converted into a tumor of similar nature, the surface next to the pelvis being broken down and ragged. Above, it could not be separated from the liver. In the lower half of the kidney the natural structure was obvious. Left kidney healthy.

About three inches above the ilio-cæcal valve was a spherical tumor half an inch in diameter, situated in the middle of a Peyer's patch, and covered with a thin layer of mucous membrane. About four inches above this was another tumor, which projected into the peritoneal cavity. They all presented the same appearance on section.

Microscopical appearances.—The structures of these tumors was nearly the same as those in the case last described. They were formed of fibres which ran parallel to one another in bundles; the bundles, however, interlaced (Plate XVI. Figs. 6. 7.). Moreover, many of the fibres were seen to be composed of fibrillæ, like those of waved or white areolar tissue. Many fibre-cells were also seen splitting up into fibrillæ. Abundant nuclei were seen after the addition of acetic acid (Fig. 8.), in other parts acetic acid appeared to destroy the fibrillæ last mentioned, and left only a number of granules, having a linear arrangement. The nuclei were, for the most part, elongated or oat-shaped, some, however, were spheroidal.

Case 3. — Although in the following case no microscopical examination was made, the description of the tumors by Dr.

Stewart (to whom I am indebted for the case) appears to prove conclusively their fibrous nature.

A weaver, æt. 47, died in the Glasgow Infirmary in December, 1837. For seven months before his death he had suffered from weight on the epigastrium, and from pain and loss of power in the left leg. Two months before his death anasarca and ascites set in; after suffering constant pain in the spine and protracted diarrhœa, he gradually sank. After death rows of tumors were found by the side of the thoracic aorta, a large number were seen near, but not connected with, the pancreas. These tumors were firm and glistening, the section much resembling cartilage. In connexion with the ribs there were several similar tumors, and a large one was connected with the lumbar vertebræ. There were also several small gristly tumors beneath the mucous coat of the stomach and of the ileum.

Several examples of the same disease have been recorded by M. Velpeau and Mr. Paget. A few meetings since, my friend Dr. Hillier exhibited a tumor of similar nature to the Society (p. 337).

Most pathologists have considered these tumors to be examples of cancer of an aberrant type, the chief arguments in favour of such a view being, firstly, their supposed structural resemblance to certain cancers; secondly, their multiplicity; and thirdly, their proneness to recur after removal.

As regards the first argument, it is certain that the structural element of cancer may approximate so far as not to be distinguishable from fibre cells; cancers of bone afford abundant illustration of this fact. But in these instances the resemblance to fibro-cells is seen in but few of the cells which compose the growth—the majority generally exhibit quite as much similarity to the cancer as to the fibre-cell; whereas in the tumors under consideration, there are no transitional cancer cells, they are unequivocal fibre-cells in different stages of development. Another and even more striking distinction is in the fact, that the secondary growths of the fibrous cancer, examined either by the naked eye or with the aid of the microscope, exhibit the ordinary appearances of cancer.

It may also be urged that certain soft portions of these fibroid tumors bear some resemblances to cancer. A more accurate ex-

amination will at once set this supposed similarity aside, for it is obvious that the soft portions are the same as the firmer, only in a state of disintegration; and the resemblance is nothing more than may be frequently seen in simple tumors.

With regard to the second argument in favour of the cancerous nature of these tumors, *viz.:* their multiplicity. The simple fact of a number of similar tumors existing in different parts of the body is, of course, no evidence of malignity; but the fact of these tumors being found in the liver and lungs is *primâ facie* evidence of a very strong character. It is a law almost universally followed by multiple simple tumors, that they occur only in those organs in which the tissue they similate exists naturally. For instance, fatty tumors are found only in fat tissue, neuroma only on nerves. Enchondroma may possibly be brought forward as an exception; as Mr. Paget records an instance of secondary cartilaginous tumors being found in the lungs; but here it is but fair to suppose that these tumors were formed in connexion with the cartilages of the bronchia. So again, as areolar tissue exists in all the viscera, it is not unreasonable to suppose that secondary fibrous tumors might grow in these organs.

The proneness to recurrence of these tumors after operation is, perhaps, the strongest argument in favour of the cancerous nature; but it is well known that many simple tumors partake of the same character, and that, therefore, this fact, unsupported by other evidence, cannot be regarded as proof of their cancerous nature.

The want, therefore, of the structural arrangement of cancer in these tumors, their complete homology to the natural tissues of the body, and the absence of anything like a perfect chain of cases, showing the transition from cancer to them, all lead to the conclusion that in spite of the similation of the characters of cancer, these tumors should be considered to be of a simple nature, and that between them and cancer there is still a broadly marked interval. The distinction, moreover, is not simply of degree, but indicates an essential difference of nature.

The close analogy of the malignant fibrous to the recurring fibroid tumor is worthy of note. Structurally, the difference

is only in the amount of development,—that is, the malignant fibrous is rather more advanced, and more closely resembles fibrous tissue. In regard to their course, Mr. Paget's and Dr. Hillier's cases afford examples of the local recurrence of the so-called malignant fibrous tumor.

Mr. SIBLEY, 18*th of December*, 1855.

---

3. *Tumor in connexion with the Scapula.*

This specimen was removed, by Mr. South, from a patient who was admitted into St. Thomas's Hospital on the 6th of November, 1855. He was a healthy robust man, æt. 30, and has, except during the last two years, enjoyed tolerably good health. About eight years ago, however, he had a syphilitic sore on the penis, attended with bubo; this was cured by mercurial treatment; and he has not, at any time since then, suffered from sore throat or secondary eruptions. His parents were healthy, and no constitutional tendency to morbid growths can be detected.

He states that about two years ago he was thrown upon his left shoulder with considerable violence. When taken up, his arm was powerless, but an examination of it by a surgeon detected nothing but severe bruising. He was ordered to keep his bed, which he did for a fortnight, with relief to his pain, but without recovering any use of his arm. At the end of about eight weeks he could support some slight weight with it, but was still unable to raise it from his side. He remained in this state for five or six months, when he went to France; whilst there he improved considerably in health, and began to gain some strength in his arm. Soon after his arrival there he complained of occasional pains about his left shoulder; these were diagnosed to be rheumatic, and removed by the administration of iodide of potassium and sarsa. At a later period of his stay in Paris, several small lumps formed at the upper part of the left side. One was situated over the left clavicle, another on the left side of the frontal bone. This was large, about the size of a walnut; it was hard and firm, but caused no inconvenience save from its unsightliness. Besides these, three or four smaller ones existed

on the same side of the thorax. "They got," he says, "gradually softer, and disappeared of their own accord."

He returned from Paris about three months ago. His general health was then very good; his arm was weak, but its strength was so far recovered as to enable him to resume his work.

Ten days after his return, however, violent pains about the left shoulder compelled him to discontinue. These were not relieved by the treatment formerly adopted; but about a fortnight after their onset were followed by a swelling in the infraspinal fossa. This increased rapidly in size, and the pains he suffered were so severe and constant as to deprive him entirely of rest. His general health was much affected (he had lost one stone in weight during the past month), and he wished earnestly for a removal of the growth.

When the patient was admitted, the tumor was tolerably well defined, and moved freely with the scapula. It did not project much above the surface. It was nodulated, and measured six inches and a half from above downwards, and eight inches from the axillary to the vertebral margin.

Mr. South determined on its removal, which was done four days after his admission. The patient was brought under the influence of chloroform, and the tumor having been exposed by the raising of a semilunar flap dissected outwards from the vertebral column, was removed by sawing through the neck of the scapula, just internal to the junction of the acromion with the spine of that bone. Some small distinct nodules, and varying from the size of a pea to that of a filbert, were found in some of the adjoining muscles, and were removed.*

Mr. Sydney Jones, *20th of November*, 1855.

Report on this specimen. — The tumor occupied the infraspinous fossa, and turning round the spinal costa of the scapula, encroached somewhat on the venter. Examinations showed

* The similarity which the deposit in this specimen bore to that in a case of diseased heart, laid before the Society the same evening, and to several like examples reported on in vol. iii. of the "Transactions," by Dr. Quain, led him to suggest that the specimens be simultaneously submitted for report.

that it was unconnected, except by contiguity, with the bone, which was perfectly healthy; that it did not spring from the periosteum, and that it did not originate as an independent tumor in the cellular tissue, but that it was an infiltration of several muscles arising from the scapula.

The infra-spinatus muscle was diseased in nearly the whole of its extent. The origins of the teres major and teres minor were slightly involved; the latter more so than the former. The origin of the rhomboideus major was affected to a considerable extent, the diseased condition extending for at least an inch beyond the margin of the scapula. The origin of the serratus magnus, and some of the contiguous fibres of the subscapularis, were also diseased. The tumor thus formed appeared to be of considerable size, but it did not really occupy much more space than had been occupied originally by the healthy muscles. It was irregular and nodulated on the surface; but these characters were, in some degree, masked by the muscular tissue being spread over and united to it. It rested on the bone in the greater part of its extent, and was moulded to its form,

The tumor was for the most part hard and dense, slightly elastic, of a dead white colour, and homogeneous, but presenting, on close inspection, a slightly reticulated appearance. It yielded no juice. The surrounding muscular tissue was directly continuous with its surface, as though arising from it, except in two or three situations, where the surface of the diseased mass had become softened and disintegrated, and the continuity between them consequently destroyed. The muscular tissue in the neighbourhood of the tumor contained a considerable number of isolated masses, of the same nature as the tumor, varying from the size of a Spanish nut downwards.

Microscopic examination.—(Plate X. Fig. 5 and 6.). In many parts of the tumor, muscular fibres were present in considerable abundance. In some parts they were few and indistinct; and in some they could not be detected at all. Many of these fibres had a perfectly healthy appearance; many of them, however, had lost, more or less completely, their striated character, and had become glistening, transparent, and structureless; others

were finely granular, but none were in a decidedly fatty condition.

The spaces between the fibres were occupied almost solely by cells. In mass their nuclei formed the most conspicuous element. These bodies were round or ovoid, about the size of pus-globules, and presented several small spots or nucleoli. On tearing the tissue up so as to separate its component parts, the cells became separated, and their forms and other characters displayed. The cells varied considerably in size and shape; some were round or ovoid, others were irregular, and presented one, two, or several tail-like processes, and frequently looked more like torn fragments of tissue than like cells. The cells usually contained one nucleus each, occasionally they contained two, and here and there a free nucleus was observed. The cells appeared to be of that kind to which the term fibro-plastic is applied. In some places, scattered among and within the cells, were numerous globules and molecules of oil; and in those situations in which the muscular tissue was undistinguishable, the cells had become fatty, and imperfect, and broken down, and, in great measure, concealed by the abundance of oily deposit about them.

The above tumor bore so considerable a resemblance in its naked-eye character to a specimen of so-called fibroid degeneration of the heart, exhibited on the same evening by Dr. Bence Jones, that we were requested to examine and compare them. A description of the heart it is unnecessary to give here; but we may state that certain portions of its diseased tissue precisely resembled, to the naked eye, the diseased muscles of the scapula; and that the resemblance extended to their microscopic characters (Plate X. Figs. 7 and 8.). Numerous muscular fibres were discovered passing through the fibroid deposits in the walls of the heart. Many of these were healthy, or studded only with a few strings of refractive molecules, but few were decidedly fatty. The intervals between the fibres were filled up by cells altogether similar in form, size, and arrangement to those described as existing in the scapular tumors. So similar, in fact, was the disease in both cases, that it was impossible to distinguish them under the microscope.

It appears to us, therefore, that the tumor in connexion with

the scapular and the fibroid masses in the walls of the heart, were identical in structure and of the same nature; that the important feature in both cases, was the infiltration of the muscular tissues by fibro-plastic elements; and that in neither case was the disease of a malignant character.

The question of malignancy is an important one as regards the scapular tumor, because the tumor was removed under the impression that it was malignant, and because after its removal more than one distinguished observer considered that that impression was borne out by microscopic examination. The reasons which have induced us to adopt an opposite opinion are the following:—

1. The cells were such as one finds in non-malignant fibro-plastic tissue; cells which, though they may exist in cancer, are certainly not characteristic of it.

2. The scapular tumor precisely resembled the fibroid deposit in the heart, as regards the form, size, and arrangement of the cells, and their relation to the muscular tissue; and, hence, there can be little doubt that the disease was in both cases of the same kind. Now, as respects the heart, the suspicion never crossed the mind of any one that that was the subject of cancer, and, indeed, there is no reason at all for any such suspicion, for the disease in it had not the anatomical characters of cancer, it was unconnected with similar disease in other organs, and it was of precisely the same character as that which has existed in several hearts that have been brought under the notice of the Society, and which has in all cases been unassociated with cancer elsewhere.

It is right here to allude to a case of cancerous infiltration of the heart, which will be found recorded by Dr. Bristowe in the present volume of the Society's Transactions, and which, in many respects, resembled Dr. Bence Jones's case; that is to say, the muscular tissue was infiltrated with a morbid deposit, and that deposit consisted of cells. The cells, however, were of a different kind to those in Dr. Bence Jones's case, and identical with the cells existing in malignant growths in several parts of the body.

3. The tumor appeared to have confined itself to the mus-

cular tissue. It had rendered the latter plump, it is true, but it had not risen above it, and it had not invaded surrounding tissue.

4. There is good reason to suppose that similar, though smaller tumors, had made their appearance and subsided prior to the time at which the operation was performed.

Dr. BRISTOWE and Mr. SYDNEY JONES.

---

4. *Myeloid Tumor of the Humerus.*

The following case was brought under the notice of the Society, chiefly because it serves to illustrate my report on Mr. Borlase Childs' specimen of myeloid tumor. It presents some features, however, of peculiar interest. In a report of it which has been published, the pathological description is very meagre.* The history I shall quote from the article alluded to, supplying one or two omissions.

A. M. a tall, thin, and pallid lad, æt. 18, was admitted into St. Thomas's Hospital, under Mr. Simon's care, on the 14th of June, on account of a large swelling in the upper third of the right arm. The tumor had a smooth rounded outline, and an oval shape. It commenced at the articular head, and extended downwards to about the insertion of the deltoid. The skin over it, excepting being crossed by an unusual number of veins, was healthy, and could be pinched up; but the intervening muscles closely adhered to the growth. To the touch, the tumor was in all parts elastic, and moderately firm; it was not tender. Spontaneous fracture of the humerus had taken place in the lower part of the diseased mass. Of this accident the patient was not aware, and did not at all know when it had occurred. By grasping the tumor itself, the head of the bone could be made to turn freely in the glenoid cavity; the outlines of all the parts of the scapula overhanging the articulation were clearly defined, and it was evident that the disease did not extend either beyond or into the joint. The boy stated that he had first perceived swelling six months ago, and there had been rather severe pain in the part almost the whole time.

* In the "Medical Times and Gazette," July 16th, 1853.

He knew of no injury, excepting having strained the arm in throwing a stone, which occasioned great temporary pain. This accident occurred a month or two before the appearance of swelling; but it is doubtful whether the pain it caused might not be due to the previous existence of disease in the part. He did not think that he had lost either flesh or strength since the tumor commenced to grow.

The arm was removed at the shoulder-joint on the 25th of June. There was nothing peculiar about the operation. The glenoid cavity was found to be perfectly healthy. In making the flap, numerous veins from the size of a goose quill downwards, filled and distended by a soft pulpy growth, were cut through; these were found to come from the tumor, and to be prolonged into the substance of the deltoid. As it was quite uncertain how far this diseased condition of the veins extended, no attempt was made to dissect the diseased veins out, and they were left in the flap. After the operation a considerable portion of the deltoid sloughed, and it was thought highly probable that the slough included all the diseased veins. With this exception the healing of the stump progressed favourably. The progress of the case was watched with great interest, for the existence of the disease in the veins caused much anxiety with regard to the ultimate success of the operation. However, no sign of the return of the disease manifested itself either in the stump or in the internal organs. On the contrary, the boy's health manifestly improved, and on the 1st of November, upwards of four months after the operation, he left the Hospital, apparently perfectly well.

The tumor was irregularly ovoid, and occupied very nearly the upper half of the shaft of the humerus. The surrounding muscles were pretty closely adherent to its surface; and the fasciculi of the deltoid appeared in many places separated by nodulated masses and knotted cords of different sizes. These cords were generally of a purple colour, though often variegated with white and red. A close examination proved them to be veins enlarged and distended with solid pulpy contents. The tissue of the muscles alluded to was for the most part, healthy; but certain portions of it were

indurated and pale, though retaining in other respects a healthy appearance. These changes in colour and consistence were most marked in the upper half of the deltoid; that portion of muscle in which were contained most of the diseased veins, and hence that in which such changes might have been anticipated.

The tumor measured about five inches in length, and three inches and a half in thickness. The epiphysis of the head of the bone, and the cartilage between it and the shaft, were healthy. Immediately below the cartilage the upper portion of the shaft entered the tumor, and was prolonged as an attenuated cone for nearly two inches into its axis. From different parts of this cone, but most abundantly from its apex, were given off bands and filaments of bony tissue, which were prolonged irregularly into the substance of the growth, and yet seemed to have some tendency to divide its softer tissues into lobules, the imperfect bony framework being completed by a kind of fibroid material. The lower fragment of the shaft ceased almost abruptly at its junction with the tumor. A few irregular bands of bony tissue were prolonged from it into the substance, and a few for a short distance upon the surface of the growth. The latter was the only situation in which there was any trace of a bony cyst.

The sectional surface presented a very peculiar aspect. It manifested in many situations an appearance of lobulation, produced in the way just described. It was very variegated; in some parts it was opaque and white, very like encephaloid, but firmer than it, and without creamy juice; in other parts it was firm and fibroid, with a semi-transparent glistening character. The fibroid material was in some places homogeneous, in others reticulated, and apparently studded with cavities of small size, some of the cavities containing a serous fluid; others a pulpy material, white, or purple, or red; others a substance like coagulum. Here and there was observed a deposit of a buff-coloured substance, which, without being pulpy, was soft, and like somewhat old fibrinous coagulum. In some situations the tissue had the appearance of being produced by a mass of vessels, the cut orifices of which varied from a quarter of an inch downwards, and which were filled with pulpy contents or blood. A few

nodules of the growth were prolonged into the upper part of the lower fragment of the humerus. Many of the veins filled with pulpy contents, situated in the deltoid, could be traced distinctly into the tumor; and the material distending them was manifestly of the same character as that which was observed in many parts of the interior of the tumor.

The following is the result of the microscopic examination:—

1. The bone tissue, taking part in the formation of the tumor, was healthy in structure.

2. The fibroid tissue consisted of a dense-looking fibroid material, somewhat reticulated, and exactly like that which is frequently developed in connexion with bone (Plate XV. Fig. 11.).

3. The material, like coagulated fibrine, presented an irregular and imperfect fibroid net-work, studded more or less copiously with oil, in the form of granules and globules of various sizes (Plate XV. Fig. 12.).

4. The encephaloid substance, and the pulpy material existing here and there in the tumor, were found to present, mixed up with fibres and blood-vessels, large numbers of myeloid cells. These cells varied remarkably in form and dimensions, and the majority presented one or more, and sometimes very numerous diverticula of different sizes and shapes, though usually more or less clavate and sometimes branched. The cells were, in consequence, frequently very much complicated, and sometimes two or more were clearly united by such processes. The cells contained more or less granular matter, and oval nucleolated nuclei. Some of the smaller cells contained only two or three such nuclei; many, however, presented large numbers of them, and in some instances there were certainly not less than eighty of these bodies in a single cell (Plate XV. Fig. 13.). The pulpy tissue distending the veins in the deltoid had precisely the same microscopical characters as that just described. The fibres of the indurated muscular tissue appeared under the microscope to be swelled up, transparent, and glassy, with scarce any sign of transverse striation, and without any deposit of oil or granular matter; but at irregular intervals there were observed transverse fissures or splits, extending more or less completely across the fibres (Plate XV. Fig. 14.). The idea that suggested itself

was that the fibres had become œdematous, swelled, and brittle, in consequence of the obstruction of the veins connected with them. With regard to the views I entertain as to the mode of growth of this and other myeloid tumors I need say nothing here, as I have given them at some length in my report on Mr. Borlase Child's case.

The points of special interest in the present case are 1. The extension of the growth into the veins. 2. The non-recurrence of the disease notwithstanding its extension into channels apparently peculiarly appropriate for speedily promoting such extension—a fact which strongly indicates the non-malignant character of the growth, and which tends, therefore, to confirm the current views on that point. 3. The size, complexity, and beauty of the myeloid cells, and the vast number of nuclei that they individually contained.

Dr. Bristowe, *4th of March*, 1856.

---

5. Specimen of Myeloid Tumor of the Head of the Tibia.

Mr. Hawkins writes—"Rather better than two months ago, I was requested by Mr. Edward Tegart, to see the lady from whom this limb was removed. The patient was æt. 22, and Mr. Tegart gave the following history of the case:—

"About eighteen months ago she began to have pain over the instep, which gradually extended upwards until it fixed in the head of the tibia, and then she perceived a swelling the size of a walnut, in that position, which continued to increase in size, and became slightly painful. About five months ago, when Mr. Tegart first saw her, the head of the tibia was considerably enlarged, but pretty uniform in shape. Twice or thrice there were inflammatory attacks of the tumor, with increase of pain and tenderness. By degrees the tumor became more irregular in size, and softer in some parts than others.

"About two months ago I first saw the patient; and, after trying the effects of remedies both external and internal without any benefit, and the tumor gradually increasing, decided to remove the limb above the knee; in which opinion Sir Benjamin Brodie, who saw the patient, at once coincided. The

operation (performed under chloroform) was on the 7th of April, by the posterior and anterior flap operation."

On examining the tumor, it appeared about the size of a cocoa-nut, and of an oblong form; the skin covering it being quite smooth and unaffected. On making a section through the bones in the neighbourhood of the knee-joint, the tumor was found to arise in the upper part of the head of the tibia, involving the whole of this portion of the bone, as well as the upper head of the shaft. The articular surface remained, consisting of a thin lamella of cartilage and bone, so that no part of the disease made its way into the cavity of the knee-joint. Its consistence was moderately firm, and to the touch presented an elastic feeling, with very obscure sense of fluctuation. The growth was invested externally by the expanded periosteum; in some parts by a thin layer of bone. The tumor consisted entirely of solid matter. There were no cysts. The circumference was of a slightly brownish-mottled tint; the adjacent portion of a lighter yellowish white tint. The central part, which had undergone advanced fatty degeneration, was of an amber-yellow colour.

Mr. Henry Gray, who has paid much attention to diseases of bone, kindly undertook the examination of the tumor; and he reports "that its structure (examined by the microscope) in many parts presented the usual appearances observed in myeloid tumors."

Mr. Charles Hawkins had little hesitation in classing this tumor with those lately so well described by Mr. Henry Gray, in a paper read before the Royal Medical and Chirurgical Society, on the 26th of February, as non-malignant. The history of this tumor was much as that described by Mr. Gray, *viz.* :—"occurring at an earlier period of life"—"growth much less rapid than malignant disease"—"the absence of malignant cachexia, and glandular lymphatic enlargement;"—"no tendency to ulcerate or protrude externally." Mr. CHARLES HAWKINS, *15th of April*, 1856.

---

6. *Large Malignant Tumor of the Thigh, for which Amputation was performed at the Hip-joint.*

M. A. G. a married woman of delicate constitution, æt. 40, was admitted into the London Hospital on the 4th of March, 1856, on account of a large tumor of the right thigh. She had enjoyed tolerable health for some years when, in August last, she noticed a small lump in the thigh. Various applications were made to it, but the swelling continued steadily to increase without pain. She stated that, about a fortnight before her admission into the Hospital, the surgeon in attendance on her plunged a grooved needle into the tumor, and drew off about a cup-full of blood.

On examination, I found a tumor of great size occupying the upper part of the thigh, chiefly in front and towards the outside, and extending nearly as high as the groin. The superficial veins over it were enlarged. The tumor had an elastic fluctuating feel, was tender, and the seat of some pain. On introducing a trocar at its outer part, about thirty ounces of bloody fluid flowed freely. The first twenty ounces were quite dark-coloured, but the last ten which escaped were of a bright colour; both coagulated on standing.

The tumor felt less tense and uneasy after the puncture, but it soon regained its former size; and during the three following days it rapidly increased. Her general health was also declining.

It having been decided in consultation that nothing short of amputation at the hip-joint would be of any service, the operation was proposed. I disarticulated the limb on the 11th of March, the patient being under the influence of chloroform. Not more than from four to five ounces of blood were lost in the operation. Up to the present time (the 18th) the case had proceeded most favourably.

The tumor was somewhat pear-shaped, the base being superior. It was bounded on the inside by the adductor muscles and femoral canal; and on the outside it invaded the vastus externus muscle, which was extended over the growth. It rested on the outer part of the femur, and extended close to the bone as high

as the great trochanter. There was no distinct capsule, only a slight condensation of the parts immediately surrounding the tumor. It was composed of masses of brain-like matter intermingled with large coagula, chiefly towards the lower part, and a number of imperfect cysts, some of considerable size, containing a bloody fluid. The outer and front surface of the upper portion of the middle third of the femur for about three inches, the part upon which the tumor rested, was very vascular, rough, and granular, and abraded to such an extent as to destroy the rounded outline of the bone. The periosteum covering this part was thinned and opened up. The tumor exhibited the microscopic elements of encephaloid cancer; and some of the masses were undergoing fatty degeneration*

Mr. Blizard Curling, 18*th of March*, 1856.

---

7. *Fibro-cystic Tumor involving the Condyles and Lower part of the Femur.*

H. H. æt. 23, brown haired and of rather pale complexion, clear skin, and delicate-looking, was admitted into the Hospital, under Mr. Child's care, on the 4th of December; her ailment being an enlargement of the lower part of the right thigh. To the eye, at first sight, the disease much resembled a chronic swelling of the joint itself, the enlargement being about equal in all parts and evenly rounded. On looking more carefully, however, it might be noticed that its boundaries above and below were too abrupt for joint-disease; the head of the tibia, just below the overhanging mass, being quite distinct, and the leg itself free from any trace of œdema or inflammation. The finger confirmed this impression; the patella being moveable, nowise lifted, and without any degree of swelling beneath its ligament. The lower fifth of the femur, on the contrary, was felt to be involved in a hard bone-like enlargement, which had greatly expanded its condyles, but which,

* The patient recovered from the operation, was discharged from the Hospital in the middle of May, and sent to the sea-side for the improvement of her general health. Up to this date there has been no evidence of a recurrence of the disease; 25th of June, 1856.—T. B. C.

superiorly, decreased rather gradually. The overlying skin was somewhat thickened, but not the least inflamed. The joint was moveable, though not so much so as natural, and no pain was complained of in the examination. The history she gave was, that about two years and a half ago (in March, 1853), she first began to feel occasional weakness and aching in the knee, which would at times "give way in walking," and cause great pain. Some months after the aching began, a little enlargement on the outer side was noticed, but no great increase in size took place until March, 1854. During March and April of that year, it increased rapidly, and then became almost stationary. Whilst increasing in size a good deal of pain was present, and the least jar to the leg used to cause a "wrenching pain;" when quiet, there was no material aching—but, for all this, at times she was kept awake by it. Her family is believed to be healthy, and no history of cancer having occurred was to be obtained. She, herself, had always had good health until the present affection, for which she knew no cause. The circumference of the swelling was nineteen inches and three-quarters.

Previous to coming under Mr. Childs' care, she had been an inmate of several Hospitals. In June, 1854, she was sent from the London Hospital to the Margate Sea Bathing Infirmary. Whilst at the latter she improved in health, and got to walk about on crutches, not, however, using the leg. Scot's dressing, and iodine paints were employed. Whilst at Margate it increased by measurement, according to her statement, an inch and a half in circumference. In March, 1855, she was again in the London Hospital, and the following note was taken:—"She has no pain in the part, sleeps well, and has no jumping of the limb. Cannot walk, as the limb aches when hung down. Catamenia quite regular. Pulse one hundred and six, full and soft, no degree of cachexia present. The hard swelling gives the idea of great expansion of the lower head of the femur, the tibia seems not affected. Circumference nineteen inches and three-quarters."

The summer of 1855 she spent at Margate, but without benefit. Her health did not materially give way, and it will

be observed that no increase in the size of the tumor occurred during the eight months prior to the amputation, its circumference, in December, being exactly what it had been in March. There was no enlargement of glands nor any symptoms of internal cancer.

On the 10th of December amputation was performed. A section made vertically through the bones constituting the knee-joint, showed the tibia and patella quite healthy, the joint also free from effusion, and excepting a few tough bands of old adhesions here and there, in a normal condition, there was no absorption of cartilage, but in parts, that over the condyles of the femur, was very thin from nodular enlargement of the surface. The disease was limited to the femur. The lower fifth of this bone was expanded into a swelling the size of four fists placed together. Its section showed a number of smooth lined cysts of various sizes, from a marble to a small orange. The cysts contained either blood-clot or a yellow opaque fluid; they had no intra-cystic growths, and their lining membrane, which was smooth and glistening, did not appear under the microscope to be more than simple basement membrane. Between the cysts was solid material of two kinds, the thickness of this inter-cystic structure varying in different parts, from a few lines to an inch. The first kind (the most plentiful) was of dull yellow colour, and from the way in which it tore up, was evidently partially decolourized blood-clot; this, in some parts, was softening down into a pulpy fluid. The second, from a solid structure, was firm, greyish, glistening, and semi-transparent. It consisted (under the microscope) of well-developed fibrous tissue, with a few elongating cells. It yielded no juice, and nothing in the least similating a cancer was discovered after much careful examination. The boundaries of the tumor were—in front, the compact bone-shaft partially destroyed from behind; below, the cartilage of the condyles and a thin layer of expanded bone-tissue; posteriorly, a thin lamella of bone-plates in the periosteum in most parts, and in a few parts the thickened periosteum only. In no place had the tumor escaped through its periosteal investment. It appeared as if originally developed between the periosteum

and bone, behind the shaft of the latter. Its increase had thus distended the periosteum behind, and pushed the shaft of the femur forward in front, also encroaching on its structure in many parts. Perhaps the opinion that it had begun in the cancellous structure of the condyles, and grown upwards and backwards, would be as probable, from the conditions found, as that of its sub-periosteal origin.

Mr. BORLASE CHILDS, 19*th of February*, 1856.

Report on this specimen.—The condyles and lower part of the shaft of the femur formed a nearly globular tumor, measuring about five inches and a half vertically, four inches and three-quarters from before backwards, and about the same from side to side. The greater part of its surface was tolerably smooth, and hard, and bony; but in the posterior region, and especially in the upper part, it was soft and yielding. The muscles and soft parts around were stretched over it, but not otherwise affected by it. There were strong adhesions between the tibia and patella and the condyles of the femur, but with the exception of these, and the alteration in shape which resulted from the position of the tumor, the joint seemed tolerably healthy.

The preparation had been bisected vertically from before backwards, and the following is a description of the structures taking part in the formation of the tumor and their arrangement, chiefly as displayed on the sectional surface.

1. Bone.

2. A white, slightly translucent, homogeneous, tough, elastic, fibroid substance, having some resemblance to fibro-cartilage.

3. A soft pulpy growth, which varied in consistence in different parts, and in colour from reddish-brown to grey, but it had evidently in the fresh state been much darker.

4. An opaque buff-coloured granular-looking material, which was for the most part soft and friable, and in some situations almost mortar-like.

5. Cysts.

6. Coagula.

1. The shaft of the femur was united obliquely with the upper

part of the tumor, and was prolonged for about three inches on its anterior surface. The portion connected with the tumor became gradually attenuated in its course downwards, at the expense of its posterior part; and its apex became continuous with a shell of bone that surrounded the growth in the greater part of its extent, but which was defective behind, and at the upper part totally deficient. The substance of the femur seemed compact and healthy, even to its posterior margin. The shell of bone varied in thickness from an inch to a line; its substance was tolerably compact, but the thicker portions contained cavities and prolongations from the internal parts of the tumor, of different sizes and shapes, filled with the softer tissues afterwards to be described.

The layer of bone connected with the joint was, on the average, a line in thickness, and was, for the most part, covered with healthy cartilage. That situated in front varied from an inch in thickness downwards; that behind from about a quarter of an inch downwards. Very little bone tissue was prolonged from the surface inwards; and there was none whatever in the interior of the tumor.

2. The fibroid substance occupied a considerable portion of the sectional surface. Towards the centre, but nearer the lower than the upper part, it formed an irregular mass, occupying an area of about two square inches. This gave origin to several prolongations, which, for the most part, had a rounded form; and it was connected by its upper, anterior, and lower margins, with several cysts, the parietes of which were formed chiefly of the same material, and were directly continuous with it. Several smaller isolated nodules and masses of the same substance were observed here and there on the surface, and sections that were subsequently made showed that they pervaded the whole of the tumor. The margins of these masses presented great variety; in some places they could be seen passing insensibly into the surrounding tissues; at others they were perfectly abrupt and well defined; and some portions could be distinctly enucleated.

3. The pulpy growth formed about an equal portion of the surface with the last. A large mass of it occupied the upper part of the tumor, and it was prolonged thence along the back,

and again formed a considerable accumulation at the lower and posterior part. Besides these there were several more or less isolated collections in connexion with the shell of bone in front and below. These varied in size from three-quarters of an inch in diameter downwards, and some of them were partially invested in a thin capsule of bone tissue. Small accumulations of the same kind of growth were scattered also here and there throughout the tumor.

4. The opaque buff-coloured material was rather extensively distributed, intervening between all the parts above described and the cysts, and separating them more or less completely from one another. It surrounded the greater part of the fibroid mass, and was in immediate contact with a large portion of the cyst walls. It did not appear to be connected in any way with the bone. It formed the greater part of the parietes of one of the cysts, and, in many places it could be seen extending into the fibroid mass, and blending with it; and a similar union could be observed taking place here and there between it and the pulpy growth.

5. The cysts were tolerably abundant, and varied for the most part in size between that of a pigeon's egg and that of a Spanish nut. They were scattered irregularly, but two or three of the largest were situated in the upper portion of the tumor. Some were round or ovoid, the majority were more or less irregular in form, and into one projected a sort of pulpy fibroid mass, which was prolonged from the fibroid tissues in which the cyst was embedded. The walls of one of them consisted partially or wholly of a dense fibroid material exactly like the fibroid tissue before described; and the walls of most of them were usually continuous at some part or other of the surface with a mass of that material. The parietes of one or two were formed partially of the opaque buff-coloured material; and those of some consisted of a condensed layer of the pulpy growth. The latter, in some situations, presented that orange-coloured deposit which is observed in apoplectic cysts. The parietes of the cysts were in contact externally with every variety of tissue. Most of them were more or less surrounded by the fibroid structure: a few abutted on bone; many of them were enve-

loped, to a greater or less extent by the buff-coloured material; and some were pretty completely invested in the pulpy growth. The contents of the cysts varied considerably: some of them were full of a turbid, opaque, buff-coloured fluid, that looked like a solution of the solid buff-coloured material; others were filled with a fluid similar in most respects, but more or less deeply blood-stained; and a few contained a grumous material that was distinctly altered blood.

6. In several parts of the tumor recent coagula were found, which varied from about the size of a filbert downwards. These were dark-coloured, irregular in shape, and occupied irregular cavities. In one or two situations were observed small isolated masses of soft yellow material, similar to that found in the walls of some of the cysts.

Microscopic examination.—1. The shell of bone investing the tumor exhibited no microscopic peculiarities. The soft tissues in its neighbourhood presented, here and there, small isolated nodular fragments containing lacunæ and canaliculi.

2. The fibroid structure presented, for the most part, tolerably uniform characters. It consisted of glistening, hard-looking trabeculæ of fibroid tissue (Plate XV. Fig. 9.), which lay, for the most part, parallel to one another in bundles, the bundles themselves taking various, but generally curvilinear directions. The trabeculæ were evidently blended more or less with one another. They presented but little appearance of fibrillation, but at the edge of a section one could see their margins and extremities rough with delicate irregular flocculi. Acetic acid rendered the fibres transparent, and caused them to swell a little, but did not bring any nuclei into view. In many situations the tissue was exactly in accordance with the above description, but, in some places, the interstices (apparently) between the trabeculæ were occupied more or less completely by oil, either in the form of molecules or globules, or of compound granular cells. In some parts (and these will be pointed out hereafter) the fibroid material displayed little or no trace of the trabecular arrangement, but consisted of a dense network of interlacing fibrillæ, which were occasionally so delicate as to present almost the characters of coagulated

fibrine. These fibrillæ seemed to be essentially of the same nature as the trabeculæ, and, indeed, the two were frequently intermixed, and they were similarly acted on by acetic acid. The amount of oil deposited among the fibrillæ was, for the most part, greater than that between the trabeculæ, and in some places myeloid cells were mixed up with them.

3. The pulpy growth consisted of a delicate fibroid reticulum, in which vessels were discovered in tolerable abundance, and cells in vast numbers. Many of the cells were small, and round or ovoid; others were irregularly fusiform, and such were frequently bifurcated or gave off one or several processes of different lengths and sizes; others, again, were very large, sometimes globular or ovoid, frequently more or less tuberculated or lobulated, and quite as frequently furnished with several more or less elongated processes. Some of these processes were distinctly rounded at their extremities, and perfect; others, however, were evidently broken; and occasionally there were strong indications of their forming a bond of union between contiguous cells. The smaller cells contained from one to three or four nuclei; the larger held frequently twenty or thirty, or even a greater number, but in the latter the nuclei were generally rendered very indistinct by the granular condition of the cell-contents. The nuclei were round or ovoid, and about $\frac{1}{3000}$th or $\frac{1}{4000}$th of an inch in diameter, and they contained from one to two or three nucleoli. The cells varied so greatly in size and shape, that it is difficult to give any estimate of their average dimensions. Some of the largest measured as much as $\frac{1}{200}$th of an inch in their long diameter. The cells seemed to be identical with those to which Paget has assigned the name of myeloid (Plate XV. Fig. 10.). The vessels passing through the pulpy growth appeared to be invested in a sheath of myeloid cells.

4. The opaque buff-coloured material consisted, in great measure, of a deposit of oil. This was partly granular and partly in the form of globules of various sizes, but, for the most part, it was collected into ovoid masses about $\frac{1}{800}$th of an inch in diameter, which occasionally were distinctly invested in cell-walls. The oil constituting these masses was in some

cases molecular; in some in the form of globules; but in the great majority of instances it formed a cluster of minute radiating acicular crystals. These masses, as well as the free oil, were all readily soluble in æther. In some places they were deposited in vast abundance; and, for the most part, they appeared to occupy the meshes of an indistinct fibroid reticulum. Where the buff-coloured material adjoined the fibroid structure, the ovoid fat masses of the former could be seen deposited among the fibres of the latter, and occasionally, though not so distinctly, a similar blending could be seen taking place between it and the pulpy growth. In some situations the buff-coloured structure contained large numbers of myeloid cells mingled with its other constituents.

5. The microscopic characters of the parietes of the cysts were in accordance with their naked-eye appearance. The greater portion of the walls of several of them consisted of trabecular fibroid tissue. Their lining membrane, however, was, in nearly all instances, fibrillated and thickly studded with compound granule cells and free oil, and wherever the cyst walls were in contact with the buff-coloured material, their outer surface presented characters similar to those of the inner. The same, too, was the structure of the softish white mass, before described as partially filling up one of the cysts. One at least of the cysts had its parietes formed by the buff-coloured material, and their microscopic structures was in conformity with this fact. The walls of those cysts which were developed in connexion with the myeloid growths consisted of fibrillated tissue, studded more or less thickly with oil, and presenting more or less distinct traces of myeloid cells, the cells sometimes, indeed, being very abundant. Those portions of the surface that had an orange-colour were found to present clusters of orange-coloured granules and globules, together with (here and there) ruby-coloured hæmatoid crystals.

The character of the cyst contents varied somewhat. In some cases they presented precisely the same elements as the solid buff-coloured material; in others they presented similar elements, but mixed with numbers of free myeloid cells; and

in some cases, again, the contents were clearly formed of blood in a more or less changed condition.

The orange-coloured masses that were discovered here and there in the substance of the tumor, presented large numbers of hæmatoid crystals, and orange-coloured granules and globules.

The recent clots had the usual characters of such formations, but the blood-globules were scarcely to be recognised. This probably depended on the mode in which the preparation had been preserved.

Remarks.—The above tumor being formed of several different elements, the relation between which is not at first sight very apparent, it is important to determine which of them were essential to it, and characteristic of it, and which were secondary, and, so to speak, accidental formations. The importance of this step becomes very manifest when it is considered how various and conflicting the reports might have been, had small sections merely been given, as is not unfrequently the case, to different gentlemen for examination. For judging of the whole tumor by the portion he had examined, one might have called it bony, another fibroid, a third might have considered it myeloid, a fourth an undescribed form of fatty growth, while those who had simply glanced at the sectional surface, might have deemed it a cystic tumor, and remained satisfied that its nature was sufficiently implied in the term.

The bone-tissue was clearly not an essential element of the growth; no more a part of it, in fact, than the liver structure around an hepatic tumor is a part of that tumor. The growth had originated within it, expanded it, and reduced it to a thin shell; but there was no formation of new bone in the substance of the growth. The buff-coloured material, judging both from its naked eye appearance and from its microscopic characters, was unquestionably the degenerated condition only of pre-existing tissues; and that the cysts had had a somewhat similar origin, I shall shortly endeavour to show. Hence it is to the fibroid substance, or to the myeloid tissue, that one must look to determine the nature of the tumor. Now the fibroid sub-

stance, though forming a very considerable portion of the tumor, presented nothing very remarkable in its character; it closely resembled the cartilage-like patches observed occasionally on the surface of the spleen and lungs; there was a good deal of similarity between it and that fibroid structure into which ossification is advancing, and it was not unlike, except as regards its arrangement, to the fibroid matrix of scirrhus. Its signification, therefore, may admit of some difference of opinion. Possibly it may have had the same relation to the more actively growing portions of the tumor that the matrix of scirrhus has to the cells which it encloses; but against this view is the fact that the fibroid tissue in the present case formed distinct masses, and was not blended with the other elements of the growth. On the whole I am disposed to consider that it was not an essential part, that it was accidental, and related rather to the bone than to any other tissue, and that it is to be looked upon, if I may use the expression, as an abortive attempt at the formation of bone in the interior of the tumor. Hence it follows that, in my opinion, the pulpy substance formed the essential part of the growth, and that the growth itself was what Paget terms myeloid. And the sequence of events in the formation of the tumor, according to the view I take, are the following:—1. The growth of myeloid tissue in the interior of the bone. 2. The expansion and absorption of the bone. 3. An abortive attempt at the development of new bone in the interior of the growth, resulting in the formation of fibroid tissues. 4. The degeneration of certain parts. 5. The formation of cysts.

There are two or three other points of interest, the consideration of which will tend somewhat to elucidate the subject under discussion.

1. The myeloid tissue. The varieties in size and form among the cells, making up the bulk of this tissue, and the vast numbers of nuclei which many of them contained, are certainly very remarkable facts; but the most interesting fact of all is the growth of finger-like and otherwise-shaped diverticula, from the cells themselves, and the occasionally, but distinctly, seen union of cells by apparently similarly formed processes. If this

be considered, as I believe it should be, the chief peculiarity in the growth of the cells, all of them, however, different in size and shape, may be looked upon as belonging to one type, and essentially similar to one another. Their mode of formation, and of multiplication, appears to have been as follows: a cell having been formed, grew, and ultimately sent off branches; these branches elongated, divided, and at length expanded at their extremities into cells of the same kind as that from which they had originated; and the same process being constantly repeated in the cells thus formed, a growth was at length produced, consisting of a series of cells, communicating with one another by bands and processes of various lengths and sizes; or, to speak in other words, a growth was formed, consisting of a network of branching fibres, which here and there were expanded into cells. This is a mode of growth, which, though it is indicated pretty clearly to my mind by the microscopic characters of the tumor under consideration, I have seen more clearly displayed in other myeloid tumors which I have examined, and especially in one that I have brought to the Society this evening. I believe that I have also observed it in more than one case of what was looked upon as epithelial cancer, and I think, too, that it is exemplified in a tumor of the brain, now before the Society,* and also in one that Mr. Toynbee reported on in vol. iv. of our "Transactions," and which I examined very carefully and illustrated. It is a mode of cell-growth exactly like that occurring in the sporules of fungi, and if it be allowed to extend the comparison further, I should be disposed to look upon the processes and fibrillæ of the myeloid cells as analogous to the mycelium; the cells, with their contents, to the fructification, and the nuclei to the sporules.

2. The buff-coloured material was clearly an extreme fatty degeneration of pre-existing tissues; and it comes to be a question, what were the tissues in which the degeneration originated, and what was the cause of that degeneration? Now from the recorded examination, it is clear that the degeneration encroached both on the fibroid tissue, and on the myeloid growth; and hence it was wide-spread, and not limited to one particular

* *Ante*, p. 28.

structure. The cause of it is not so easy to determine. It may be that the process of decay or degeneration in this case was simply of the same character as that which commonly occurs in the interior of cancerous tumors, the explanation of which it is unnecessary now to consider. It may be, however, that the cause here was different, and there is a great possibility that the appearance may have been due to extravasation of blood into the substance of the tumor; the blood having infiltrated the tissues, and having undergone those further changes which blood, thus circumstanced, sometimes undergoes. The objections to this view are, first, the great extent of the degeneration, and second, its uniformity of character; the reasons in its favour seem to be, 1. The compatibility of its microscopic characters with this explanation; 2. The existence of recent clots in some parts of the tumor; and 3. The presence of cysts, which there is every reason to believe originated in extravasations of blood.

3. The mode in which the cysts were formed in this case, is a point of extreme interest; and I may at once state that from a careful examination of the surface of that portion of the tumor which was first submitted to me, I came to the conclusion that some of the cysts were formed by the absorption of clots of extravasated blood, and that some were the result of a later stage of that sort of degeneration which was exemplified in the buff-coloured material just described, and these views were strengthened by subsequent examinations. The formation of some of the cysts by the absorption of clots is indicated by the following facts:—1. The existence here and there of recent dark-coloured clots. 2. The presence of small, solid, soft, orange-coloured deposits, which exhibited numerous hæmatoid crystals, and the orange-coloured granules and globules, so commonly found in connexion with clots in process of absorption. 3. The existence of similar orange-coloured bodies and hæmatoid crystals in the parietes of some of the cysts. 4. The contents of some of the cysts being distinctly blood in a more or less altered condition. The formation of other cysts by a process of degeneration, similar to that occurring in the buff-coloured material, is rendered probable:—1. By the inner surface of some of the cysts being formed by this material; and, 2. By the

contents of many of them being turbid and yellowish, and presenting precisely similar microscopic characters. I entertain no doubt whatever as to some of the cysts having originated in extravasions of blood, and from a natural wish to simplify matters, I am somewhat inclined to believe that the others had a similar origin. I consider that the microscopic characters of the cysts alluded to, both as regards their parietes and contents, are not adverse to this view; still I feel that the explanation of their origin, and that of the origin of the buff-coloured deposit, are so dependent on one another, that the blood origin of the former cannot be admitted without assigning a similar origin to the latter; and as this is a point which, though not improbable, I am not fully prepared to admit, I must beg, for the present, to express a qualified opinion.

The fibroid structure which bounded several of the cysts, I am disposed to look upon as merely the remains of that fibroid structure which happened to circumscribe wholly, or in part, those portions of tissue in which softening, and the formation of cysts was going on, and not as a new formation arising in connexion with the cysts.

Finally, I may mention, that I believe the formation of cysts by extravasation of blood is not at all rare. I have examined many tumors containing cysts, the origin of which I have traced to this cause: and in proof of it I may call your attention to two or three cases which I have recorded in the "Transactions" of the Society, which are illustrations of this point. 1. A tumor of the thigh, described at p. 451, vol. iii. 2. A malignant tumor in the pelvis, described at p. 224, vol. iv. And 3. A tumor connected with the spinal cord, described by Dr. Bennett at the last meeting,* and the cyst in connexion with which, I believe to have resulted from extravasation of blood.

I may here add that the tumor was examined also by Mr. W. Adams, who fully agrees with me as to its nature.

Dr. Bristowe, *4th of March*, 1856.

* *Ante*, p. 41.

8. *Report on a Specimen of Osteo-sarcoma, presented to the Society by Mr. Fergusson.*

The tumor submitted to us for examination, consisted of a large oval mass, partly of osseous, and partly of soft cartilaginous consistence, firmly embracing the upper two-thirds of the tibia. It was an enchondromatous growth. A vertical section of the tumor and the whole shaft of the bone gave an admirable illustration of the coarse anatomy and relations of the mass (Plate XVII. Fig. 1.).

In *form*, the tumor was a long oval, somewhat flattened on one side, and bulging on the other, and narrow at its lower extremity.

The *size* of the tumor was considerable, measuring nine inches in length; and the circumference of the limb, where the mass was largest, being about twenty-two inches.

The *exact position* of the morbid growth was very obvious; it completely embraced the tibia, and was in direct structural continuity with its outer surface, while itself it was covered in, and invested, by the periosteum, which was stretched over it.

The *coarse structure* of the tumor, as displayed by dissection (Plate XVII. Fig. 2.), was found to consist partly of soft cartilaginous portions, partly, and more abundantly, of portions of a bony character. The circumference of the tumor consisted wholly of soft cartilage: that in contact with the tibia consisted wholly of bone, while, in the intermediate parts, the one blended into the other, though with some irregularity.

The tibia ran vertically through the tumor, and the compact tissue of its shaft was clearly visible from end to end, but in some places, from the close density of the bone of the tumor, the one merged so completely into the other that its outer limit was not defined to the naked eye. Passing outwards, the bony structure became less compact, and more cancellated, and in some parts of the section gave way altogether to masses of cartilage, which increased in dimensions, and, further outwards, projecting irregularly into the bony masses, constituted the limit of the tumor. The cut surface of the

DESCRIPTION OF PLATE XVII.

The figures illustrate Dr. Ogle's and Mr. James Salter's report on Mr. Fergusson's case of Osteo-sarcoma, p. 372.

Fig. 1. Vertical section of the tibia, surrounded by the enchondromatous tumor (greatly reduced).

a a a. The soft cartilaginous limit of the tumor.

b. Position of the microscopical section.

c. Serous cyst.

Fig. 2. Vertical section of a portion of the tibia and enchondromatous bone, magnified 14 diameters.

d. Bone of the enchondroma.

e. Compact tissue of the shaft of the tibia.

f. Thin line of union.

Figs. 3 to 6 Represent the histological elements of the tumor as seen with a glass magnifying about 200 diameters.

Fig. 3. Isolated cartilage cells of various forms.

Fig. 4. Cells analogous to the secondary cartilage cells, floating in the serum of a cyst.

Fig. 5. Primary cells, with secondary cells, developed into lacunæ, in immediate contact with encondromatous bone, taken from a cancellus.

Fig. 6. Cells from the medullary canal.

Fig 2

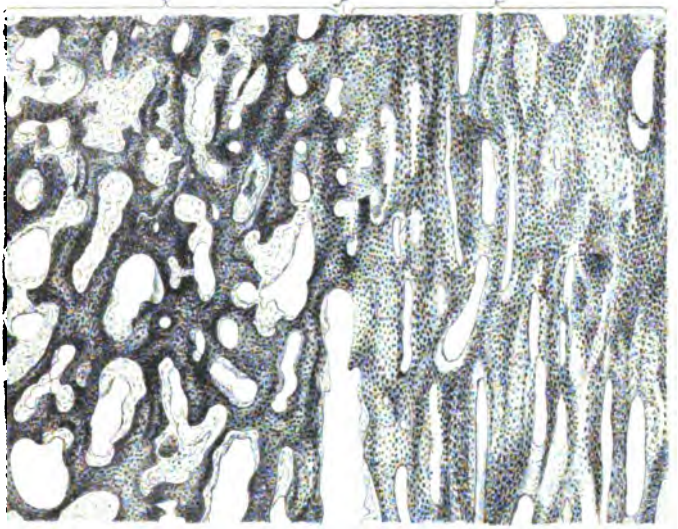

× 14

Fig 1

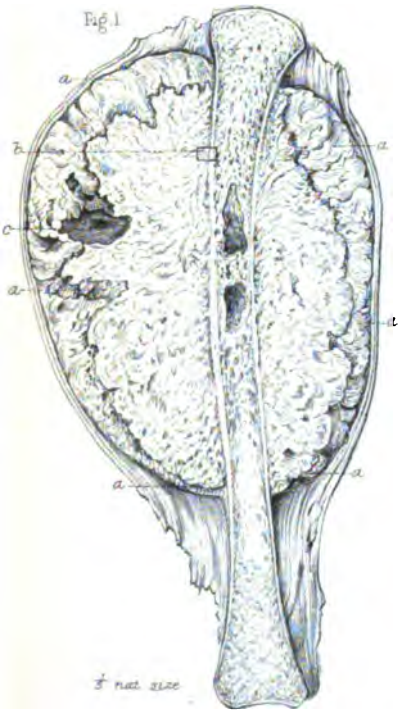

Fig 3

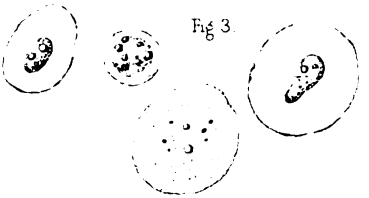

Fig 4

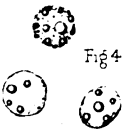

Fig 5

Fig 6

J Salter & E M Williams del. T West sc.

W Wert imp.

bony portions had much the appearance of ordinary cancellated bone, but the cancelli contained cartilage, and not medulla. The cartilaginous resembled in colour the grey matter of the brain; and, on the outer surface, where the periosteum was stripped off, it was irregularly lobulated like the cerebral convolutions.

In two or three situations, towards the outer parts of the tumor, some soft pultaceous masses of cartilage, surrounded by capsules of hardish bone, gave a sort of cystic appearance. There were, however, numerous serous cysts within the tumor: of these many were discovered, varying in size from a millet-seed to the dimensions of a small walnut. These cysts were limited by a thin but distinct lining of fibrous tissue, and most contained a somewhat viscid serum, yellow, and more or less tinged by blood. Others contained, with the viscid fluid, a quantity of blood-stained coagulum, and at the extremity of some of these cysts, apertures existed, permitting the passage for some inches of a bristle in a direction towards the surface.

Microscopical structures.—Upon submitting portions of the soft cartilage to the microscope, it was found to consist, for the greater part, of cells wholly without intercellular substance, therefore a parenchymatous cartilage; among the cells was a serum containing multitudes of minute fat globules. In a few specimens, however, were found a distinct intercellular fibrous tissue. The cells themselves (Plate XVII. Fig. 3.) were most of them large, many of them very large, reaching to the $\frac{1}{300}$th of an inch in diameter; others were as small as the $\frac{1}{1200}$th of an inch. Each cell consisted of a thick wall, a large nucleus, and frequently a nucleolus within it: or, more properly speaking, a *primary* cell, a *secondary* cell, and a nucleus,—the latter nomenclature being preferable, because the inner cell had a distinct wall of its own, and frequently an independent existence. The wall of the primary cells was very thick, and, we are inclined to think, reached from its outer limit to the secondary cell within it, having no proper cavity of its own. It was very transparent, and occasionally laminated like the wall of a starch grain, or, perhaps, more like the albuminous layers of a

microscopic hydatid cyst. Generally it constituted a broad clear area around the secondary cell, but occasionally a mere thin ring.

In one instance, a primary cell was found containing no secondary cell within it, but a few scattered granules of fat.

The form of the primary cell was usually spherical or oval, more commonly the latter.

The secondary cells (which had the relation of nucleus to the primary) were large in proportion to the outer cell, dark, and opaque, containing many oil-globules, and uniformly placed in the axis of the primary cell. They appeared to possess a thin, but very firm wall, and had a large cavity within them. Occasionally a nucleus was seen (Plate XVII. Fig. 4.).

Multitudes of these secondary cells were free; and as decomposition set in, the primary cells rapidly vanished, whilst the secondary remained unaltered. The secondary cells were, for the most part, oval, sometimes round, and occasionally exhibited projecting points.

In selecting a portion of the bone of the tumor for microscopical examination, a slice was sawn involving also a portion of the compact tissue of the shaft of the tibia.

The enchondromatous bone was found less tenacious and less even in structure than normal bone, and the reducing it to a proper thinness for microscopical examination was attended with much difficulty.

Upon placing a section, mounted in Canada balsam, under the microscope with low powers, the enchondromatous bone displayed an elaborate cancellated reticulation. The cancelli were very irregular in outline, and the whole structure was destitute of any appearance of axis or general direction. The laminæ of the bone were very opaque; and where they were texturally continuous with the normal compact bone of the tibia, this, as well as the previous character, was very apparent.

Seen with high powers, the lacunæ of the bone of the tumor were found very numerous, large, round, and with abundant canaliculi, different in all these respects from the contiguous normal bone.

In the cancelli, close to the edge of the forming bone, were

found occasionally cells, in which the secondary cells within them had apparently been converted into true lacunæ (Plate XVII. Fig. 5.).

In microscopical structure the serous cysts consisted of a web of fibrous tissue similar to the white fibrous element of areolar tissue, and which, when treated with acetic acid, became transparent, and disclosed many minute nuclei.

We also observed in those containing coagula multitudes of large, flat, pink-coloured crystals, apparently of hæmatine.

We conclude that the specimen was one of enchondroma, and that it originated external to the shaft of the tibia and beneath the periosteum.

Dr. J. W. Ogle and Mr. James Salter, 18*th of December*, 1856.

---

9. *Pulsating Erectile Tumor in the Cheek.*

The patient, a child æt. 20 months, had been under care in the Metropolitan Free Hospital. At birth, a small swelling had been noticed beneath the right lower eyelid, which had since increased so as to constitute a great deformity. The child had been under treatment at different Hospitals all its life, and pressure and other means had been tried without benefit. It possessed a feeble pulsation, and felt like a subcutaneous nævus, from which, however, it differed, in that pressure was not efficient to empty it beyond a certain point. Having reflected up the integument which covered it, Mr. Hutchinson had succeeded, by first ligaturing all points where vessels entered, in removing the whole without material loss of blood. The wound had healed well.

The pathological importance of the specimen consisted in the circumstance that it was composed of three distinct elements:—1, dilated veins and capillaries as of a nævus; 2, true erectile tissue; and 3, lobules of fibro-fatty tissue. The last mentioned were of considerable size, and accounted for the fact that the tumor had only been susceptible of very partial collapse under pressure. They would also have prevented the success of any measure of treatment other than that by complete excision.

Mr. Hutchinson, 1*st of January*, 1856.

10. *Mammary Glandular Tumor.*

Miss L. æt. 19, consulted Mr. Henry Thompson on the 8th of March, for a tumor in the left mamma. Her attention was first called to it eight months previously. Since that time it has been slowly but steadily increasing in size. There has been some pain of late, dull and heavy, especially after handling.

Examination.—Embedded in the upper part of the left mamma, is a hard incompressible tumor, apparently as large as a small orange. It is very free and moveable; no adhesion to skin or deep parts. No alteration in the appearance of the nipple as compared with that of the other breast. No enlargement of axillary or clavicular glands.

The general health is good; condition not impaired; menstruation regular.

The patient's friends having a strong objection to the removal of the tumor by operation, pressure by means of Dr. Arnott's air pad was kept up during four or five months, with the effect, as it appeared, of reducing its volume somewhat. At all events, at the end of that period it was no larger, but it certainly appeared even still more firm to the hand than at first. Mr. Thompson now declined advising any other treatment than that of excision; and performed the operation on the 22nd of August last. It formed a circumscribed tumor, but so adherent to the gland structure around (from the effect of pressure?), that it was necessary to remove small portions of this in parts.

The patient did remarkably well, the wound healing by the first intention, with the exception of a small sinus, which remained open for a short time.

Examination of the tumor.—Its external surface presents several markings and elevations corresponding to the existence of several lobes, of which it is made up; and it is invested with a dense cellular cyst, very firmly adhering to the structures both within and without. The section presents a very compact, slightly lobulated mass, of yellowish-white colour; a little juice exudes, which, under the microscope, shows nucleated cells, and nuclei full of granules. Sections also under the microscope exhibit the same bodies and tubular forms, the outline of which

is marked by a row of small nucleated cells. These bodies have a well-defined outline, and the nuclei and granules within become more distinct on the addition of acetic acid.

With these characters the tumor is doubtless an independent glandular growth, resembling in structure, and almost in extent of development, the natural tissue of the mamma in which it was embedded.

Mr. Henry Thompson, *20th of November*, 1855.

---

11. *Large Glandular Tumor from the Axilla, simulating the characters of Scirrhus.*

A pale, cachectic man, æt. 52, had been admitted under Mr. Hutchinson's care, into the Metropolitan Free Hospital, on account of a tumor in the right axilla, which had all the ostensible features of cancer. It was of almost stone-like hardness, painful, but partially moveable, and puckering in, by its growth, all surrounding parts. Tense bands of fascia could be felt dragged into its structure; and in several parts its margin was ill-defined. At first the skin did not adhere, but during the month the man remained under observation, it became involved, being then not in the least reddened, but puckered up by the adhesions, and assuming exactly the "saddle-leather" appearance usually so characteristic of cancer. The man's aspect was considered by all who saw him as a marked example of "cancerous cachexia." After a careful consultation with his colleagues, in which no doubt whatever was expressed as to the nature of the disease, Mr. Hutchinson determined to remove it. It was now becoming week by week more firmly attached to the deep structures, and its excision would very soon have become impracticable. In the operation a portion of adherent skin, a mass of consolidated glands the size of a turkey's egg, and eight other smaller glands not involved in the mass, were dissected out. The sheath of the vessels and part of the brachial plexus were laid bare, but no amount of blood was lost. The man had since done well.

The tumor, when cut across for inspection during the operation, was believed to be scirrhus, though not a very marked specimen.

In parts it cut quite crisply, and its section became somewhat cupped; its firmest parts, however, exuded very little juice. A subsequent and prolonged examination of the specimen, both by the naked eye and the microscope, had, however, led to the conclusion that it resulted only from the effects of chronic inflammatory induration, and did not possess any malignant structure whatever. The main mass consisted of four or five large glands, much indurated themselves, but embedded in thick layers of fibroid tissue yet more dense.

The man had suffered from nothing which could have been deemed the exciting cause; he had had no sore or abrasion on the arm or chest. About a year before the commencement of the disease, however, he stated that he had noticed a pea-like nodule, movable beneath the skin, over the mammary region. This could not be found when he came under care, but Mr. Hutchinson stated that as such a tumor had existed in two cases of primary carcinoma of the axillary lymphatics formerly under his notice, the account of it had tended somewhat to strengthen his erroneous diagnosis in the present instance.

Mr. HUTCHINSON, 1*st of January*, 1856.

---

12. *Case of Cystic Growth developed in the Mammary Gland.*

M. R. applied to me on the 25th of February, 1856, and showed me a tumor in the left breast. She has had seven children, and suckled all with both breasts. Of a nervous, excitable, sanguine temperament, she has yet enjoyed good health. The catamenia appear regularly. The mammary glands are well developed, rather shrunk and pendulous, and the nipples well-formed.

About October, 1851, when she was forty-one years of age, eighteen months after the birth of her last child, which she was then suckling, she accidentally observed a lump, about half an inch in diameter, close to the nipple, and beneath the areola. It was moveable, rather hard, painless, and slightly elevated the skin. This lump increased, and at last fluid ran out from the nipple when the swelling was pressed. This fluid was of the colour of sherry wine. It continued to flow away for about two

years and nine months; but it ceased a month before she came to me. The swellings could be very much diminished by thus emptying them, but they never disappeared entirely.

When I saw her, the surface of the left breast was remarkable on account of several elevated irregularities about the nipple. The existence of fluids in these was plain from fluctuation. The skin over them was of a healthy aspect. The nipple was misshapen, but otherwise healthy. The whole breast was rather indurated, and slightly pendulous. During the last month no fluid has escaped from the nipple; but when I pressed the part gently, I obtained four different kinds of fluid :—

1. Bright, clear yellow, tenacious serum.
2. Dark red clear fluid.
3. Yellow, unctuous, pus-like fluid, greasy.
4. Greenish, unctuous, greasy fluid.

Various methods of treatment had been adopted. A seton had been put through the tumor. Cotton wool had been applied. A chemist told her he would cure it; "he had seen many cases like it." His treatment, however, failed. The Oldfield Lane doctor said, "It's only skin deep, have it out." She had some stuff to rub it with from the Cancer Hospital; but it was so unpleasant she could not use it.

On the 8th of April, 1856, I excised the growth, together with the whole gland. A considerable number of large vessels required ligatures. When all the fat of the part was removed, the gland tissue of the breast was seen indurated and covered with small cysts containing a dark-brown fluid. The ducts near the nipple were dilated. Large cysts near the nipple showed a pinkish, red, and purplish tint. They were filled with fluid. The contents could not be expressed at the nipple.

The fluid which these cysts contained was serous, and the red corpuscles of the blood were mixed with it. Upon that surface of the cyst in close relation with the breast, was a rather soft, solid growth, dotted with minute points of blood, rather flocculent in some parts, and much broken up into minute particles, without, however, any definite arrangements. It grew from the wall of the cavity by a base as broad as its body.

Microscopical examination of the intra-cystic growth.—It was

composed of nucleated elements, very closely resembling, if not identical with, those seen in any part of the body in which a formative action is going on; as, for example, in healing ulcers, wounds, or in what is often termed "organised lymph" by older writers.

The elements were small, oval and round nucleated cells, fusiform nucleated elements, and others having an inclination, as it were, to form fibres. Not a trace of the compound nucleated elements existed, nor of those elementary bodies constituting the principal masses of carcinoma. I could not find any trace of the formations characterising an imperfectly developed gland tissue.

He was well in July 1860.

I believe this specimen to belong to a class of the cystic diseases of the breast which still requires elucidation. But this observation is interesting, as demonstrating the relation which the cyst, at one period of its development, seems to have had with the ducts. This disease is quite distinct, in its natural history, from adenocele, and from that variety of carcinoma in relation with which a cyst containing sanguineous fluid is developed, and, judging from those cases I have seen, its prognosis is most favourable. Mr. JOHN BIRKETT, 15*th of April*, 1856.

---

13. *Drawing of Warts which disappeared under the use of Magnesia.*

The subject of this case, æt. 21, was born in China, of European parents, and finished his education at Lausanne, in Switzerland. When about sixteen, without any cause of which he was aware, he began to be troubled with warts on various parts of both hands, but chiefly about the edges of the finger-nails. These gradually increased in size and number, until he could not put on a glove, and the appearance of his fingers was a source of continual annoyance to him. He sought the advice of an eminent Swiss operating surgeon, who repeatedly removed them by the knife, and then cauterized the roots. These means proved of no avail, and he had long given up his case as hopeless.

Having to consult me for another malady, my attention

was at once attracted to the warts on his fingers, and having seen an account of a case cured by magnesia, in vol. xxvii. of Braithwaite's "Retrospect," and quoted from "La Presse Medicale," of Brussels, I prevailed upon my patient to try the remedy. This was on the 2nd of August, 1855. The appearance of the hands at this time was very repulsive. Six or seven of the nails were almost entirely surrounded by the morbid growth, which has all the appearances of a common wart.

The treatment was continued until the beginning of November without any local or external application whatever, at which period the whole of the warts had entirely disappeared, and have not since returned. Although this disease may be deemed of little importance—in this case it had assumed a degree of inconvenience and annoyance which made the life of the patient wretched. Mr. PART, 1*st of April*, 1856.

---

14. *Case of Extensive Dissecting Abscess of the Lower Extremity from Pyæmia.*

The child from which the specimen was taken was born healthy and plump, of a healthy mother, æt. 32, and was her sixth child. The mother recovered well from her confinement, and states that she has never had any puriform discharge since, nor any leucorrhœa previous to that event. The umbilicus separated on the fifth day, and nothing unusual was remarkod about it.

The child appeared well until the fourth day after birth, when it was observed to draw up its legs on being washed, and to cry when any attempt was made to straighten them. It now refused to take the breast, cried when washed, and was continually moaning, as if in pain. The alvine evacuations were green and lumpy, and frequent in number; it gradually became paler, its features were pinched, and the countenance anxious and indicative of suffering.

On the eighth day an indistinct hard swelling was observed on the outer side of the right knee-joint, about the head of the tibia, and another over the lower end of the vastus internus; both were very slightly discoloured.

On the tenth day the child was considerably worse, having become excessively pale and emaciated, and evidently, from the incessant crying, in great pain. Several swellings had now made their appearance, with fluctuations; there was one above, and on the inside of the knee, as above described, which appeared connected with another below the knee, on the same side, extending to half way down the leg, and somewhat across the lower thigh. The swelling at the head of the tibia also contained pus. The two tumors below the knee were opened, and about a teacupful of thin sero-purulent fluid evacuated, which appeared to afford very great relief. The apparent benefit was, however, of short duration, for towards the evening of the day on which the abscesses were opened, the child appeared evidently sinking, and died on the following morning, twenty hours after the pus had been evacuated. The treatment consisted in the application of fomentations, poultices locally, and opiates to allay the pain.

Examination thirty hours after death.—Body much emaciated. The leg diminished in size since the abscesses were opened.

On laying open the seat of former abscesses, a cavity was found extending from behind the internal malleolus below, to within half an inch of Poupart's ligament above. The cellular tissue connecting the muscles together was completely broken down, and the greater portions of the sartorius above, and the gastrocnemius below, the knee, were entirely dissected out. The abscess appeared to have surrounded the patella, except at its outer side, but had not communicated with the knee-joint. Below the knee a portion of periosteum, about the size of a sixpence, was absorbed, and the bone laid bare. The whole of this immense cavity was lined with small lumps of the thicker portions of their former contents, which appeared to have been deposited there, from those serous portions which had been evacuated.

On opening the abdomen, the liver at once presented itself to the view, large, dark, and intensely congested. On its surface appeared numerous yellow spots, varying from the size of a pea to that of a small marble. These spots were most numerous along the margin of the liver, and contained a yellow homoge-

neous pus. The intestinal tube was healthy throughout its entire length. The kidneys also were healthy, without any indications of puriform defect.

Chest.—The pericardium was unusually dark and congested, and contained a small quantity of fluid, probably three drachms. The heart was covered entirely with a layer of coagulated lymph, which adhered somewhat tenaciously to it. The substance was perfectly healthy. The pleural cavities also contained a considerable quantity of fluid. The left lung was highly congested, and bound down to the diaphragm anteriorly, by a band of lymph the width of a little finger. The appearance of the right lung was singular. The general colour was pale, with about a dozen spots averaging the size of a marble, intensely red, which proved to be lobular pneumonia in the stage of congestion. A small quantity of blood taken from the external iliac vein, examined under the microscope, was found to contain pus globules.

The case presented several points of analogy to those recorded by Dr. Habershon in vol. vi. of the Society's "Transactions." The condition of the liver was similar, as was also that of the right lung, except that all the spots of lobular pneumonia were in the same stage; whereas in Dr. Habershon's case they were varied, probably from the longer duration of the disease. In Dr. Habershon's case both surfaces of the pericardium were covered with thick layers of lymph, while in this the pleural portion only was so covered. Mr. Part, 20*th of May*, 1856.

---

15. *Case of Carcinoma of the Bones of the Cranium, the Vertebræ, the Ribs, and most of the Internal Organs of the Body.*

The specimens exhibited, consisted of the lumbar vertebræ, the cranial bones, and the cranial and spinal dura mater. The bodies of all the vertebræ were considerably affected by the carcinomatous substance, and were greatly softened; those of the last two being almost completely destroyed by it. This substance encroached considerably upon the intervertebral foramina, and to a slight extent upon the spinal dura mater, to which it was very firmly adherent, though it did not seem to

have penetrated this membrane, or affected the nervous tissue beneath; but the various nerves issuing from between the vertebræ were much interfered with. Many of the bodies of the dorsal vertebræ were also slightly affected by the presence of the same material. The cranial bones exhibited several rounded soft carcinomatous masses, both on their outer and inner surfaces, and the bone around them was very vascular. Moreover, several portions of the diploe contained the same kind of material. Where the masses on the surfaces of the bones existed, it could be traced from the diploe to them, along with the minute vessels, passing through the same foramina, which were, however, greatly increased in size, giving to the bone, where cleaned, a decidedly cribriform character. One or two of the veins of the diploe, which were very dark, contained coagulated blood, in which existed cells of the same nature as those to be described as found in the carcinomatous masses. The cranial dura mater was affected in several places, on its outer surface only, by soft shreddy carcinomatous masses, which did not affect the brain except in the case of the right lobe of the cerebellum, which was slightly hollowed out on its surface by the pressure of a mass; but was not otherwise affected. Nor was the dura mater penetrated by the carcinoma, excepting where in one part on the left side it passed into the lateral sinus, presenting a shreddy mass in that vein, which was surrounded by blood coagulum, containing the cell elements to be described. The lungs, liver, kidneys, abdominal lymphatic glands, and (inner surface of) bladder, were all more or less occupied by the deposit.

The *microscopical examination* of the carcinomatous masses in all these parts showed the presence of almost entirely rounded cell-bodies (Plate XVIII. Fig. 1.), containing, in some cases, granular matter, but in most of them only apparently clear fluid material, the majority being a little larger than pus globules; some were twice the size. These nuclear bodies, after a slight maceration in spirit and water, assumed a decidedly granular appearance. In very few cases were there any other forms of cell, but here and there larger and nucleated cells were seen, and occasionally one or two elongating (Plate XVIII. Fig. 2.). The deposit in the lymphatic glands was modified

DESCRIPTION OF PLATE XVIII.

Figures 1 and 2 illustrate Dr. J. W. Ogle's case of Carcinoma of the Cranium, Vertebræ, and most of the Viscera, p. 383.

Fig. 1. Shows the simple nucleus-like character of the majority of the cells which composed the carcinomatous deposit; alike in all the parts affected. When quite recent these were chiefly translucent and void of any solid contents.

Fig. 2. Shows isolated cells which were few in number and of a more compound nature.

Figs. 3 and 4 represent the elements of carcinoma of the liver from another patient of Dr. Ogle's.

The deposit had the same general appearance as that from which Figs. 1 and 2 were taken, and these figures are intended to show the extreme variety of character which the cells of carcinoma may assume.

Figures 5 to 9 illustrate Dr. Bristowe's observations on the Seat of Cancer, p. 387.

Fig. 5. Section of the heart, showing fibres surrounded by nuclei.

Fig. 6. Nuclei magnified 420 diameters.

Fig. 7. Nuclei magnified 900 diameters.

Fig. 8. Section of the cortex of the kidney.

a. Section of a tube containing healthy epithelium.

b. Section of a healthy tube.

Fig. 9. Casts of tubes, showing the relative size of nuclei of the epithelial to those of the cancerous growth.

Figure 10 illustrates Mr. J. Hutchinson's remarks on a case of Peculiar Growth of the Fungus of Ringworm, p. 395.

a. Sporule (tricophyton tonsurans), of a rounded or oval shape, many of them larger in size than are usually seen in ringworm.

b. The same aggregated into clusters.

c. Fragments of filaments. Many of these show joints as if from the joining together of several individual sporules end to end.

d. Epidermic scales.

Figure 11 illustrates Mr. H. Thompson's remarks on the Fungus (Microsporon Furfurans) of Pityriasis Versicolor, p. 397.

a. Filaments.

b. Spores.

Figure 12 represents Melanotic Cancer Cells from the Distended Vesicula Seminalis of a horse, described by Dr. Black, p. 400.

The large cells were of a faint yellowish, or yellowish-brown colour. Acetic acid showed nuclei in some cells; but few nucleoli.

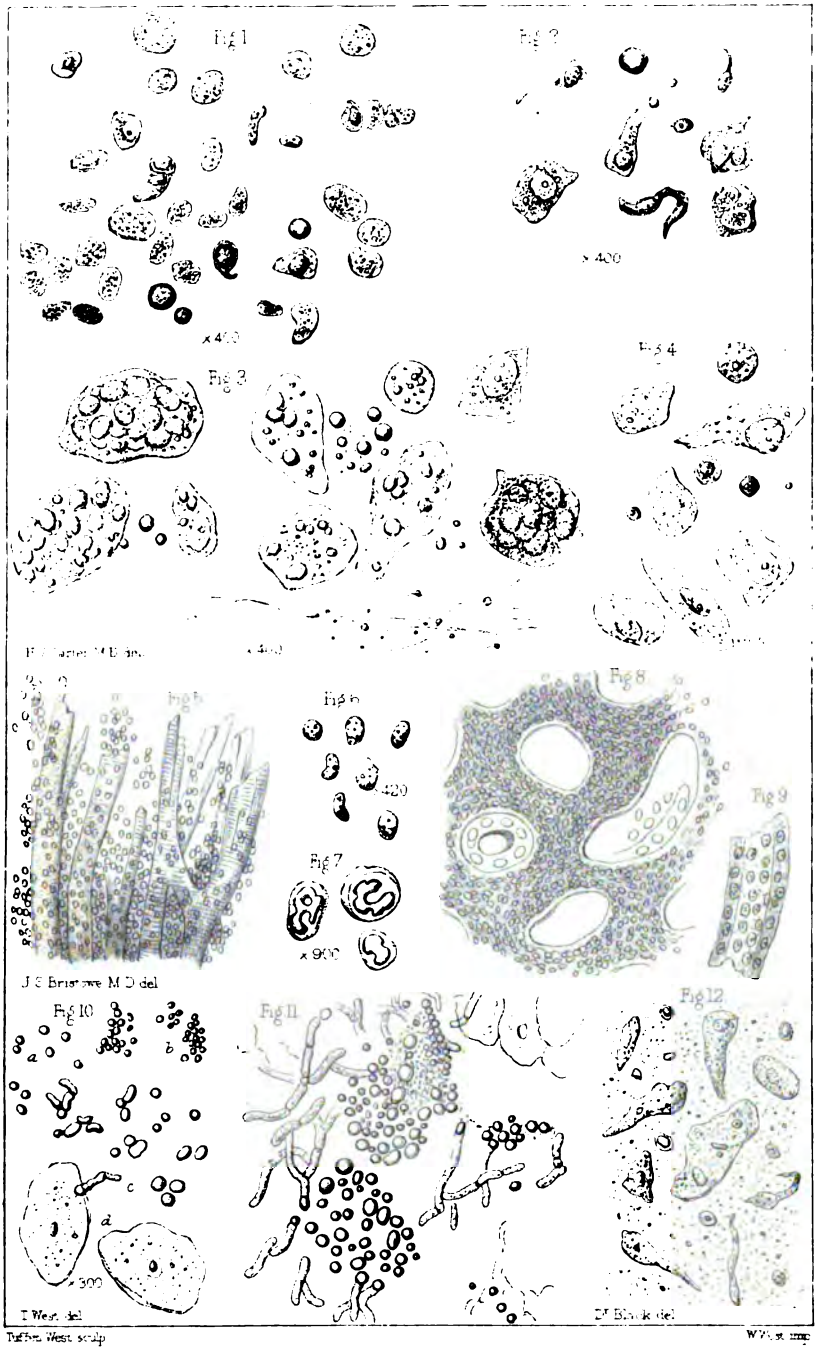

J S Bristowe M D del

T West del

Dr Black del

Tuffen West sculp

W West imp

by the presence of glandular elements amongst it. The same kind of cells was seen in the veins of the diploe, and in the left lateral sinus, mixed with coagulum of blood. The preparations were removed from the body of a woman, æt. 26, who said she had enjoyed good health until about four months before she was admitted into St. George's Hospital, at which period the urine became tinged with blood, owing, as she thought, to a strain which she had met with. At that time she had no pain. Two months before admission she suffered violent pain in the loins, which continued. On admission the pain existed, the tongue was coated, and bowels confined. The catamenia were regular. The urine dark, containing blood and pus. Cupping to the loins and aperients gave relief for a time; but subsequently, pain in all the limbs came on, unrelieved by morphia. After being in Hospital for about three weeks, loss of power came on in the lower extremities, which became complete; the urine became ammoniacal, and passed involuntarily. Hectic came on, and the patient sank and died, about one month after her admission.

Remarks.—The affection of the bony tissue was no doubt secondary to the bladder affection, as the symptoms would point out, and the paralysis was doubtless owing to the pressure of the carcinomatous masses on the lumbar nerves as they passed from the spinal canal. The case is interesting, owing to the rapid progress of the disease. It is also very interesting, by reason of the general uniformity of the microscopical appearance of the deposit in various parts of the body, which had not advanced beyond a nuclear condition in any part, as also from the fact that the same nuclear bodies were distinctly ascertained to exist in the blood circulating in the veins of the diploe and the cranial sinus. Dr. J. W. Ogle, *4th of December*, 1855.

---

16. *Portions of the Lumbar Glands, Liver, Lungs, and Heart of a Man who died five months after the removal of the Testicle for Malignant Disease.**

Mr. Henry Thompson removed the testicle on the 1st of May, 1855. The patient was discharged from the Infirmary on the 28th, the wound having perfectly healed. He was re-admitted to the medical wards in August, and died in September. The following are notes of the autopsy so far as they relate to the disease in question.

The cicatrix resulting from the operation was healthy, as was the vas deferens leading down to it. Along the course of the iliac vessels lay some enlarged glands. The same appearance was seen on the opposite side, but to a less extent. The situation of the lumbar glands was occupied by a large mass, equalling in size an ordinary melon, but elongated. The liver exhibited a large number of nodular masses of a whitish hue, slightly projecting from the surface, the size varying from that of a pea to a bean. On making a section of the liver, the inner part of the organ was almost free from these deposits. Both lungs exhibited similar appearances. On examining the heart a mass was found embedded in the walls of the right auricle, about the size of a large filbert. This was loose in texture, and from it sprang lobular projections about the size of a hemp seed. An aggregation of these formed a projecting body an inch long, hanging free in the auricular cavity.

On making a section of the mass in the situation of the lumbar glands, it would seem to be made up by the aggregation of a large number of small and independent portions united by cellular connexions. Under the microscope the tissue exhibited irregularly shaped cells in every variety of form, some resembling gland cells, intermixed with much amorphous and granular matter, free nuclei, and a few plates of cholesterine.

The growth in the heart, on making a section, was extremely soft and pulpy, and of a deep red colour. On examining this

* The testicle was exhibited to the Society on the 1st of May, 1855; and an account of the case is published in the "Transactions," vol. vi. pp. 240–5.

under the microscope, the following elements were observed. A large proportion of the field was filled with rounded and irregularly oval corpuscles from $\frac{1}{3000}$th to the $\frac{1}{750}$th of an inch. Many of these containing a well marked nucleus and nucleolus; some containing two very distinct nuclei. Among these a small quantity of granular matter, and some small irregularly formed granular cells. On attempting to tear up minutely the tissue of which the protruding intra-auricular growth consisted: this was found extremely difficult to accomplish. Under the microscope it exhibited elements much resembling those already described, the cells in general being smaller, and intermixed with more granular matter. Two or three crystals, resembling in form the triple phosphate, were observed in the field.

An examination of the masses in the liver presented the same result; but, in addition, there were great numbers of highly refractive globules of all sizes, the smallest of all being clustered into forms resembling large granular corpuscles.

Mr. Henry Thompson, *4th of December*, 1855.

---

17. *Specimens illustrating the seat of Cancer.*

The specimens which are here described, were removed from the same patient as was the cancerous tumor of the mediastinum which was exhibited by Dr. Barker at a former meeting; but as their microscopic examination was made subsequently to that meeting, and as the result of it seemed to throw some light upon the seat of cancer, it was thought advisable to bring them separately under the notice of the Society.

Heart.—The surface of the heart was somewhat roughened, and presented an opaque white appearance. The organ was about normal in size, but it was a little mis-shapen, and the right ventricle appeared to be disproportionately large. On section the walls of the left ventricle were found to be half an inch thick; those of the right three-eighths of an inch. Both cavities were contracted and empty, and all the valves sound. The muscular tissue of the external parietes of both ventricles was peculiarly pale, close grained, and hard, but otherwise had a healthy appearance. There was nothing like a tumor or

growth to be detected in them. The same characters were observed in the outer walls of the auricles, but the septum ventriculorum and the musculi papillares presented the ordinary characters, as to colour and consistence, of healthy muscular tissue.

On examining the heart with the microscope, it was found that all those portions, (*viz.:*—the external parietes of the auricles and ventricles) which to the naked eye were pale and dense, were infiltrated with the elements of cancer, while all those which at first sight looked healthy, proved to be really in a healthy condition. The amount of deposit in the affected parts varied considerably, being sometimes so great as nearly to conceal all the muscular fibres, sometimes so small as barely to be distinguishable. There was but little uniformity in its arrangement, though on the whole it was more abundant towards the outer surface than towards the inner. The diseased condition consisted in the deposit of cancer cells in the spaces between the muscular fibres (Plate XVIII. Fig. 5.). These bodies were congregated in greater or less abundance, and appeared to have a tendency to cohere, although very little fibroid tissue could be detected among them. They occupied the spaces between the muscular fibres, separated these fibres more or less completely from one another, and formed for them, as it were, a series of alveoli. The muscular fibres themselves, even where most beset by cancer cells, were healthy;—that is to say, there was no fatty degeneration in them, and the transverse striæ were tolerably distinct; and hence it may be concluded that the presence of the cancerous growth around them had as yet but little, if at all, interfered with the nutrition.

The bodies which I have called cancer cells were identical in all respects with those which made up the bulk of the mediastinal tumor, and with those observed in the diseased portions of the kidneys; and as they were precisely similar to the cells which are most commonly found in encephaloid tumors, and which I have examined carefully over and over again, I think they deserve a detailed description.

I have called them cells, but I look upon them as being essentially nuclei; they are round, ovoid, or somewhat irregular

in form, and, on the average, somewhat smaller than a blood corpuscle. They have a sharp, definite outline, and under a low magnifying power (one-fourth) appear to contain from one to two or three nucleoli (Plate XVIII. Fig. 6.). Under a high power (as 900 diameters) they appear to consist of two parts (Plate XVIII. Fig. 7.), a transparent, refractive, homogeneous, solid material, and a clear transparent fluid. The former constitutes the walls and nucleoli, the latter fills the central cavity. The walls have a very definite and measurable thickness. Their outer surface is perfectly smooth and sharp; but their inner is very uneven, presenting a series of elevations and depressions very irregular in form and distribution. Some of the elevations are small and barely perceptible, while others form elongated clavate processes, which extend into or beyond the centre of the cavity. When the latter are seen in profile, their connexion with the wall is manifest; but when they project towards, or from the eye of the observer, they appear to be isolated, and might easily pass for free nucleoli. I am inclined, however, to believe that in all cases they are united to the parietes, that they are identical with them in composition, and solid. From the characters presented by these bodies, it seems to me that their mode of formation is this:—That in the first place a solid homogeneous mass of the refractive material is formed; and that subsequently, by endosmose, fluid is absorbed into its interior, where a cavity is formed by laceration to receive it: and that hence is produced—by distension the smoothness and sharpness of the outer surface;—by laceration, the irregularity of the inner surface with its pseudo-nucleoli. I may add that, though I have noticed these characters perhaps more frequently and closely in the nuclei of cancer than in those of other growths and of healthy tissues, I have a strong impression that the latter, in the great majority of instances, present the same characters, the same mode of growth, and the same relation to the contained bodies called nucleoli.

Having already, in conjunction with Mr. S. Jones, described the structure of a tumor connected with the muscles of the scapula, and having, in opposition to some, come to the conclusion that it was not cancer, although it so far resembled the

present case as to consist essentially in the deposit of cells between the muscular fibres. I think it right to point out distinctly the reasons that influenced me in arriving at an opposite conclusion with regard to the case under consideration; and hence I close my observations by stating, that I regard the diseased condition in the heart I have been describing as malignant,—first, because the infiltrating material was made up of cells in all respects identical with those that characterized the undoubtedly cancerous growth in the mediastinum; and secondly, because they were also identical with the kind of cell which is more characteristic than any other of encephaloid cancer.

Kidneys.—The kidneys were very large, measuring about six inches and a half in the long diameter, and having their other dimensions proportionately increased. One weighed twenty-one ounces and a half, the other twenty-three ounces. Their capsules were but slightly adherent, and varied from a line to a line and a half in thickness. They were lacerable, opaque-white, and pulpy, and evidently infiltrated with cancerous deposit. The surfaces of the organs were found to be very smooth, and though universally pale, thickly studded with patches of a more complete whiteness. These patches varied considerably in size, had a tendency to assume a circular shape, but had coalesced more or less in all directions so as to form tracts of considerable extent. Their edges were shaded off gradually; there was no difference in consistence between them and the parts around; and they were elevated little, if at all, above the general level. They occupied at least two-thirds of the surface of the organs. On section, the whole cortical substance appeared to be infiltrated with a soft white brain-like material, and though this appearance was universal, yet the deposit had a tendency to become accumulated into globular masses, which blended more or less completely with one another, so that the sectional presented very nearly the same appearance as the external surfaces. For the most part, the original structure was still visible, though rendered indistinct by the growth that infiltrated it. Here and there, however, it was completely masked or destroyed. The cortical substance, on the whole, was perhaps rather softer than usual;

still it had a considerable degree of elasticity, and there was no difference in consistence between its different parts. The medullary substance appeared to be nearly healthy, and so also did the lining membrane.

Examined microscopically, it appeared that the substance of the diseased portions of the kidneys was infiltrated with cells precisely similar in size and all other respects to those that were observed in the mediastinum and in the heart. They were densely aggregated together, and were mixed with very little fibroid tissue. One could detect everywhere, more or less distinctly embedded among the cells, Malpighian bodies and renal tubes; and a careful examination of thin sections proved quite satisfactorily that the latter were in all cases healthy. It was clearly seen that the cancer-cells occupied the matrix of the organ exclusively, and that in consequence of their development, the tubes and Malpighian bodies were separated to an unusual distance from one another; that the capsules and capillary tufts of the Malpighian bodies were healthy, and that there was no formation of cancer within them; and also that the walls of the renal tubes were in a normal condition, and that they were lined by perfect epithelium (Plate XVIII. Fig. 8.). That the epithelium of the tubes was healthy was perfectly plain, for not only was it seen that the cells were normally arranged, and that the individual cells and their nuclei were natural in every respect, but a careful examination distinctly showed that the cancer-cells were considerably smaller than the nuclei of the epithelial cells (Plate XVIII. Fig. 9.).

I have never made out so satisfactorily as in the present case the seat of cancer in the kidney but guided by what this case teaches me, I entertain now no doubt whatever that in several other cases which I have examined of incipient cancer of this organ, the seat of the disease was the same. Of one of these cases I have drawings, and though they were made under the impression that the cancer-cells had invaded all the tissues, they bear witness against themselves, and show satisfactorily to my mind, that the diseased condition they were intended to illustrate was really confined to the matrix. I may add that the case is one recorded at p. 7 vol. iv. of our "Transactions,"

and that though the nature of the disease of the kidney is in that place briefly and doubtingly mentioned, I have since felt perfectly satisfied that it was cancer.

Should it turn out, as I suspect it will do, that most, if not all, cases of cancer of the kidney originate in the way I have described, and that the organ may attain very large dimensions and exhibit to the naked eye the extreme of disease without the essential elements of the organ being involved or affected otherwise than by pressure, it will be easy to understand how extensive malignant disease of that organ may exist without giving rise to the usual symptoms of renal disease, and how albuminous, or, at most, bloody urine may be the only signs of derangement of the urinary secretion even in the most advanced stages of the disease. It will also be understood, how little, at least in the earlier progress, is the likelihood of detecting cancerous elements in the urine at all, and even if they should mingle with that fluid at any period of the disease, how easy it would be to overlook, how difficult to recognise the small and inconspicuous corpuscles which characterise in most instances malignant disease of the kidney.

Dr. J. S. Bristowe, *15th of January*, 1856.

---

18. *Case of Talipes Equino Varus, with Disease of the Knee joint.*

S. C. æt. 76, died at the Lambeth Workhouse in the month of November, 1855, of cancerous ulceration of the mamma. Her body was sent to the medical school of St. Mary's Hospital for dissection. The body was of short stature, and much deformed. There was a lateral curvature of the vertebral column, the convexity of the curve being towards the right side. The right foot presented a well-marked, though not very extreme example of talipes varus, and there was a tendency to the same condition in the left foot. The right knee-joint also was much distorted, the right leg being bent outwards, so as to form an angle with the thigh.

Right foot.—The inner edge of the foot was drawn upwards and inwards, so that the outer edge would rest upon the ground, while at the same time the heel was drawn considerably up-

wards and backwards. On removing the skin, fasciæ, and fat from the ankle and foot, the following was found to be the altered relation of the bones and tendons.

The tuberosity of the *os calcis* was drawn upwards and backwards towards the posterior surface of the tibia, and in place of looking directly backwards, looked more towards the outer side than in the natural state.

The *astragalus* was considerably altered in position and form. In reference to its normal position, it was much more oblique. Its anterior extremity, by which it articulated with the scaphoid, in place of looking directly forwards, was turned obliquely inwards. The anterior part of the superior articulating surface was exposed in front of the ankle-joint. The articular surface for the external malleolus was well-marked, but only the posterior portion was in contact with that process, the exposed part in front being covered by the ligaments of the ankle-joint stretched over it. The angle of bone formed where the superior and external articular surfaces meet in front, was very prominent, and merely covered by the skin.

The tuberosity of the *scaphoid* bone was drawn inwards and considerably upwards, but not much backwards, being situated nearly three quarters of an inch in front of the inner malleolus, the average distance in the adult female being about one inch, or one inch and a quarter.

The dorsal aspects of the *cuneiform* and *metatarsal* bones, in place of looking upwards, were turned very obliquely or almost directly outwards.

The first *phalanges* of all the toes were drawn upwards towards the dorsum of the foot, while the second and third phalanges were curved downwards towards the sole.

As regards the *tendons*, those on the dorsum of the foot, the short and long *extensors* of the toes, and the *tibialis anticus* were turned considerably towards the inner side. The tendons of the long extensor of the great toe, and of the tibialis anticus, were very tense, the former drawing the first phalanx of the great toe upwards on the dorsum, the latter being inserted into the internal cuneiform bone one inch and a half in front of the inner malleolus. The tendon of the *tibialis posticus* lay in its

usual groove behind the inner malleolus, and then passed forwards and a little upwards, to be inserted into the tuberosity of the scaphoid bone three quarters of an inch in front of the anterior margin of the inner malleolus.

Immediately behind the tendon of the tibialis posticus, where it lay behind the inner malleolus, was the tendon of the *flexor longus digitorum*, and half an inch farther back, the tendon of the *flexor longus pollicis*, the posterior tibial nerve and artery supervening.

The *tendo Achillis* was extremely tense, drawing the tuberosity of the os calcis upwards and backwards. The central portion of the *plantar fascia* formed the inner margin of the sole of the foot, and was also very tense. The sheaths of the flexor tendons appeared to be the cause of the two last phalanges being curved downwards towards the sole, for when the sheath in one toe was divided, these immediately became straight.

The *right knee-joint* was much distorted, the right leg being bent outwards, so as to form an angle with the thigh, and the internal condyle producing a very prominent projection on the inner aspect of the joint. There was perfect freedom of motion between the articular surfaces, with great lengthening and relaxation of the internal lateral ligament. On opening the joint, a quantity of a transparent, yellowish, viscid, glairy fluid escaped, not unlike clarified honey. The head of the tibia was displaced slightly outwards from the lower end of the femur, the internal condyle of which was enlarged, and projected greatly inwards. The internal lateral ligament was stretched over the prominence formed by the internal condyle, and was extremely lax. The synovial membrane was thickened, and at several places, especially in the neighbourhood of the crucial ligaments, thrown into fimbriated vascular folds. Passing between the inner surface of the internal condyle and the capsular ligament, were several adhesions, in the form of firm fibrous-looking bands, about one inch in length. The articulating surface of the femur presented a remarkably irregular nodulated surface. The opposed surfaces of the external condyle, and outer part of the head of the tibia, were quite denuded of cartilage, and presented a smooth porcellainous aspect. The por-

tion of the articular cartilage which remained was softened in its structure, and exhibited a rough granular surface. The external semilunar cartilage was softened, and its inner margin split up into shreds. The lower extremity of the femur, besides being very uneven, presented two small bony prominences, resembling small exostoses. One of these, about the size of a small hazel nut, was attached anteriorly between the two condyles; the other smaller, about the size of a coffee bean, projected from the outer margin of the inner condyle into the inter-condyloid space. It was coated with cartilage, and a distinct groove, where it was attached to the condyle, gave the appearance of a slightly constricted neck.

Dr. MURCHISON, *4th of December*, 1855.

---

19. *Hairs and Crusts from a Case of Ringworm, showing Peculiarities in the Growth of the Characteristic Fungus.*

The conditions under which the fungus (tricophyton furfurans) existed in this specimen differed in some considerable particulars from those commonly observed. The patient, a girl, æt. 8, under the care of Mr. Filliter, in the Marylebone Infirmary, had her scalp almost covered by irregular patches of dryish furfuraceous crusts, some of them an eighth of an inch in thickness. Through these crusts many hairs might be seen projecting in an apparently healthy state. There were no patches in which the hairs had been entirely destroyed, though in most they were fewer in number than on other parts of the scalp. None of the crusts were purulent, but resembled to the naked eye accumulations of epidermis, as in chronic psoriasis, excepting that they were not so white and silvery. In all these particulars the case differed from one of ordinary ringworm, in which the patches were usually covered by the thinnest possible branny desquamation, and by the short stumps of broken-off hairs, having nothing that could be called a crust, and never showing any healthy hairs. The microscope, however, showed that the disease was nevertheless a true ringworm. The crusts were made up of epidermic scales and the sporules of fungus, the latter being in great abundance. In

some instances the hairs passed unaffected through these crusts with the sporules adhering all around, but not infiltrating them; in the greater proportion, however, the hairs were broken short off, swollen, and rendered opaque, by the parasitic developments within the structure. The sporules themselves, whilst not nearly so large as those of favus, were considerably larger than those most commonly seen in ringworm. In many instances they adhered in large masses to the epidermic scales, or even appeared to have been developed within their structure. In a few instances a well-marked formation of filaments was observed, a condition very rare in ringworm (Plate XVIII. Fig. 10.).

Mr. Hutchinson was inclined to attribute the peculiarities of this case (which, in more than a hundred examinations of ringworm hairs he had never before seen paralleled) not to any difference in the species of fungus present, as to the remarkable strength and thickness of the child's hair. The hairs were black and extremely strong, much more like those of an adult than of a child. On this account, he thought it likely that they had been invaded by the parasite with difficulty, and had in some instances resisted its attacks. The almost entire immunity of adults from ringworm of the scalp, and the rapidity with which it spreads on the scalps of very young children, whose hairs are soft and succulent, appeared confirmatory of the opinion. To the want of fitting location in the tissues of the hairs was probably to be attributed the circumstance that the fungus had produced so much more than usual of epidermic desquamation. This circumstance furnished another fact in disproof of the theory advanced by Mr. Erasmus Wilson, as to the disease being a fatty degeneration of the hair itself. The case was important as an illustration of the great value of the microscope in the diagnosis of affections of the scalp. Without its aid, it would have been impossible for the most experienced dermatologist to have conjectured the true nature of the disease.

Mr. HUTCHINSON, *5th of February*, 1856.

---

20. *The Vegetable Fungus of Common Ringworm, Tinea Tonsurans.*

From a child, æt. 10, diseased hairs from patches of the scalp affected by common ringworm, tinea tonsurans, showing the sporules of the fungus, trichophyton tonsurans, and also filaments, the latter being very rarely observed. The sporules are seen in the root and in the substance of the hair, from which they emerge, and are then observed to take a linear arrangement, ultimately becoming true filaments on the outside of the hair.

Mr. Henry Thompson, *6th of May*, 1856.

---

21. *Microscopic Specimens of the Vegetable Fungus found in two Cases of Pityriasis Versicolor.*

Mr. Henry Thompson has recently treated four cases of this skin disease by local applications only, of a saturated solution of sulphurous acid gas in water, and the eruption had been completely removed in all at periods varying from fourteen to twenty-one days. No internal remedies were given. The duration of the complaint had been respectively two months, five months, and four and five years. The preparations exhibited were from the last two cases.

The specimens consisted of the scales, obtained by lightly scraping the discoloured cuticle, treated with liquor potassæ, and placed under a quarter inch object glass. They are made up of tesselated epithelium, among which, running in all directions, and much interwoven, are seen numerous filaments (Plate XVIII. Fig. 11.) and groups of rounded spores. This parasitic fungus, first observed by Eichstedt in 1846, has been classified by Charles Robin as the "microsporon furfurans," and is considered by him to possess characteristic marks, which separate it from other species. It differs, he says, "a longitudine trichomatorum ac ramulorum, et forma sporidiorum semper rotunda."*

* "Histoire Naturelle des Végétaux Parasites." Par Chas. Robin. Paris, 1853, p. 436.

A point which is worthy of note appears to be one which relates to the question of the contagious or non-contagious character of the complaint. If it is to be regarded as contagious, on account of the parasitic nature of the constituent element of the disease, it could nevertheless be so only within certain limitations; one of which might be, that it is necessary that some morbid conditions of the secretions or excretions of the skin should pre-exist in order to render an individual liable to be the subject of the disease. Thus, in two of the instances referred to, the patient had been in the most favourable circumstances for communicating it by contact, *e.g.* in that of a husband and wife, and of a mother and sucking child; the last-named in each pair not having caught the complaint, although exposure had in the first lasted for years, and in the second for months. It might be held, then, that some skin secretions were favourable, while others were unfavourable, for becoming the appropriate nidus for the development of the germs brought into contact with the cutaneous surface.

Mr. Henry Thompson, *15th of April*, 1856.

---

22. *Extensive Scabs on the Mucous Membrane of the Colon, associated with Submucous Cysts containing Calcareous Particles in Herpes Phlyctenodes in the Horse.*

On the 19th of July, 1854, a horse was killed in the Veterinary School of Turin, because too old for work. He was emaciated and low, suffering from herpes phlyctenodes, a very common, though not serious, affection in the horse.

On the protected parts of the skin, especially where the hair was deficient, such as over the inside of the thighs, and even beneath and behind the elbows, were circumscribed herpetic patches, indicated, principally, by yellowish or brownish furfuraceous scales, loosely hanging to the scanty and erect hairs. In some parts scabs were seen covering red and inflamed portions of skin.

With Professor Ercolani, I instituted a *post-mortem* examination, and, to our astonishment, discovered most extensive scabby production closely studding the mucous surface of the

transverse colon Besides this lesion, we found hepatization of the posterior lobe of the right lung, apparently of recent date. The stomach, healthy, contained a few specimens of the *spiroptera megastoma.* The small intestines, liver, spleen, and other organs were healthy.

The mucous membrane of the transverse colon, of a portion of which I made a faithful drawing, was covered over a very large surface, in broad patches, by dark brown or greenish-coloured scabs, of considerable thickness and firmness. They were most developed on those portions of membrane, corresponding to the longitudinal muscular bands, and encrusting, as they did, the larger folds, they radiated laterally along the lesser rugæ. Here and there were separate, circumscribed scabs, some almost as small as an ordinary pin's head. In some situations the scabs had fallen off, and the exposed membrane was tumefied, red, and inflamed. Under, round, and about the scabs, were some worms, of the species *strongylus armatus,* in a state of development, wanting of their aculei. These worms I observed in other parts of the intestine, together with the *oxyuris vermicularis,* so commonly found in the horse's cæcum.

I prosecuted the inquiry further, to ascertain the condition of the coats of the intestine, and on dissecting away the peritoneal and muscular coats, the submucous tissue, always in the diseased parts, was the seat of numerous greyish-white specks, looking somewhat like nervous ganglia or Pacchionian corpuscles. One of these, placed under the microscope, was discovered to be a cyst with a central circular, granular, dark-coloured mass. The addition of hydrochloric acid caused the cyst to rupture, and the nucleus rapidly effervesced, leaving the bare circumscribing tissue. The cyst itself appears made up of a central delicate translucent structure, impregnated apparently with the earthy salts, and an outer, darker, and coarse fibrous envelope. Acetic acid causes this tissue to swell.

These calcareous particles reminded me of the phosphate of lime concretions which I had, in common with many others, so frequently observed in the choroid plexuses and Pacchionian bodies of aged people or aged animals, especially the horse.

These, however, often strikingly refracting light, are generally more uniform in structure and more brilliant than the intestinal ones, which were black, opaque, and tuberous spheres.

Mr. JOHN GAMGEE, 18*th of December*, 1854.

---

23. *Case of Melanic Cancer in the Horse.*

"This preparation was taken from a horse, the history of which I could not ascertain, but which was said, by the person who obtained the preparation, to be 'cancerated throughout.' It was, however, distinctly stated that numerous 'small black swellings' existed in various parts of the abdomen, along the course of the rectum, around the anus, beneath the skin, and in one orbit of the animal.

"In the preparation exhibited, it will be noticed that each vesicula seminalis is distended into the form of a sac, which almost equals in size the urinary bladder. On opening one of these sacs, it was found to contain a semi-fluid substance of the consistence of jelly, and of a deep brown or reddish-brown colour, in mass appearing almost black. It adhered somewhat tenaciously to the lining membrane of the sac, was from sixteen to twenty ounces in quantity, and contained twenty per cent of solid matter.

"One of the sacs was left undisturbed, and a ligature was placed on the vesical side of the termination of the vesicula seminalis in the urethra, to prevent any admixture of the preservative fluid with the contents of the sac. On removing, however, the preparation from the fluid, it was found that the ligature had become displaced, and that the fluid had found its way into the sac, from which it was now issuing by the canal of the urethra in a yellowish-brown liquid, the colour of which was due to its admixture with the contents of the sac."

A portion of this fluid exhibits the characteristic cell-structures, which are represented in Fig. 12. Plate XVIII. and which leave no doubt of the malignant nature of the disease from which the animal suffered.

Dr. QUAIN for Dr. BLACK, 1*st of January*, 1856.

---

24. *Calculus from the Bladder of a Field Mouse.—Mus Sylvaticus.*

The specimen was taken from the urinary bladder of an English field mouse, which was killed. No evidence of disease was present in other parts of the body. The calculus is of a circular form, somewhat flattened, weighs three grains, is of a greyish-white colour, and very firm texture. It is slightly roughened, and is principally composed of the oxalate of lime, with an intermixture of the carbonate of lime and uric acid.

Calculi are rare in the rodentia, but they are occasionally found in the rat and in the hare. The Museum of the College of Surgeons posseses one from the latter: and a small calculus from the bladder of a rat, weighing about two grains, I have examined in the Museum of St. Bartholomew's Hospital; it is very rough and irregular in shape, and composed most probably of phosphate of lime. Fourcroy and Vanquelin found oxalate of lime in the calculi of rats. The specimen from the mouse is most probably unique.

Dr. GIBB, *15th of April*, 1856.

---

25. *Tubercles in the Lungs of a Pony.*

The pony had had a cough for at least nine months. The cough got better while the animal was doing some light work in the South of England, but, on returning to town some three months ago, the cough got worse. The animal became lame first in one hind leg, then in the other, and finally the jaws became rigid. These symptoms were attributed by Dr. Babington to rheumatism. About a week since the animal's breathing became very difficult and hurried, and death took place three days ago. The only organs found affected after death were the lungs. They were much congested, almost hepatized in some parts, and they were studded throughout with yellowish masses, in size from a grain of shot to a pea. They resembled, but were larger than, miliary tubercles in the human subject. Many contained nodules about the size of pin's-heads, of a bony hardness. Before the blow-pipe these swelled, and then

dwindled away to a small portion, which, being heated, passed into pure lime. There were no cavities. Dr. Quain had examined the deposit with the microscope, and found it to consist of abortive cells, earthy, fatty, and granular particles, mixed with the elements of the pulmonary texture. The specimen very clearly showed the seat of the deposit in the pulmonary cells.*

Dr. QUAIN for Dr. BABINGTON, *4th of March*, 1856.

* The specimen was submitted to Professor Spooner, whose description very nearly corresponds with that above given.

INDEX.

Abdomen, contusion of the, causing laceration of the vena cava; with rupture, inversion, and invagination, in a tubular form, of portion of the inner and middle coats of the aorta, 131.

Abdominal viscera, case of triple umbilical hernia, containing various portions of the, 220.

Abscess, gangrenous, of the brain, induced by disease of the internal ear, 17.

„ not psoas, passing upwards and backwards, and opening externally, in a case of scrofulous necrosis and caries of dorsal and lumbar vertebræ, 290.

„ extensive dissecting, of the lower extremity of an infant, from pyæmia, 381.

Abscesses within the substance of the middle lobe of the brain, 14.

„ in the head of the tibia; the parts involved in an excision of the knee-joint, showing, 314.

Absorption and dilatation of the kidney, with stricture of the ureter, 262.

Almonds, essential oil of, stomach in a case of poisoning by, 189.

Aneurism, false, of the heart, formation of a, communicating with the aorta, probably also with the right auricle, and with the surface of the heart, 87.

„ of the heart, 96.

Aneurism, *continued.*

„ of the aorta compressing the pulmonary artery, and causing death by angina pectoris, 102.

„ of the ascending aorta, bulging into the right ventricle of the heart, and considerably obstructing the orifice of the pulmonary artery, associated with an aneurismal pouch of the septum of the ventricle, 104.

„ of the aorta, case of dissecting, 106.

„ of the basilar artery, associated with total deafness, 122.

„ of the middle cerebral artery, 125.

„ of the middle cerebral artery; extravasation of blood from bursting thereof; death in a few hours, 127.

„ of the posterior cerebral artery, forming a laminated tumor within the brain, 129.

Aneurismal dilatations of the coronary arteries of the heart and their branches, 98.

„ pouch of the root of the aorta, rupture of an; death by gradual hæmorrhage into the pericardium, 102.

Angina pectoris, aneurism of the aorta compressing the pulmonary artery, and causing death by, 102.

Ankylosis at the upper end of the spinal column, 285.

„ „ report on, 288.

Ankylosis, *continued.*
„ of the knee-joint in an aged male subject, 312.
„ softened, of the knee-joint, 313.
Anus, pendulous artificial, associated with unique congenital malformation, and umbilical hernia, 216.
Aorta, aneurism of the, compressing the pulmonary artery, and causing death by angina pectoris, 102.
„ aneurism of the ascending, bulging into the right ventricle of the heart, and considerably obstructing the orifice of the pulmonary artery, associated with an aneurismal pouch of the septum of the ventricle, 104.
„ dissecting aneurism of the, 106.
„ false aneurism of the heart communicating with the, and giving rise there to fibrinous-like vegetations of the, 87.
„ root of the, rupture of an aneurismal pouch of the, 102.
„ inner and middle coats of the, rupture, inversion, and invagination, in a tubular form, of portion of the, 131.
Aortic valves, disease of the, and of the adjoining texture of the heart; formation of a false aneurism of the heart, communicating with the aorta, giving rise there to fibrinous-like vegetations, and probably communicating also with the right auricle, and with the surface of the heart, 87.
„ „ diseased, 92.
„ „ vegetations on the, in connexion with obstruction of the middle cerebral artery by a fibrinous plug, 118.
„ „ report on, 120.
„ and mitral valves, disease of the, 91.
Apoplexy, cerebral, calcified pericardium in a case of, 72.
„ „ report on, 73.
„ „ and pulmonary; softening clots in the heart, &c. 134.
Appendix cæci, perforation of the, from an intestinal concretion, 210.
„ vermiformis, tuphlo-enteritis from hardened fæces in the, 211.
Arachnoid cavity, encysted coagulum in the, 6.
Arm, atrophy and partial paralysis of the right, in connexion with a large cyst in the left corpus striatum, 8.
Arteries, internal carotid, blocking up of both by coagulum, and consequent death, 111.
„ coronary, of the heart, and their branches, aneurismal dilatations of the, 98.
Artery, basilar, aneurism of the, associated with total deafness, 122.
„ middle cerebral, obstruction of the, by a fibrinous plug, in connexion with vegetations on the aortic valves, 118.
„ „ report on, 120.
„ middle cerebral, aneurism of the, 125.
„ middle cerebral, aneurism of the; extravasation of blood from bursting thereof; death in a few hours, 127.
„ posterior cerebral, aneurism of the, forming a laminated tumor within the brain, 129.
„ left common iliac, fibrinous coagulum obstructing the, and causing gangrene of the leg, 175.
„ pulmonary, and orifice, contraction of the, 83.
„ pulmonary, aneurism of the aorta compressing the, and causing death by angina pectoris, 102.
„ pulmonary, orifice of the, aneurism of the ascending aorta considerably obstructing the, 104.
Atrophied kidneys, 265.
„ „ report on, 265.
Atrophy and partial paralysis of

Atrophy, *continued.*
the right arm, in connexion with a large cyst in the left corpus striatum, 8.
„ of the optic nerves and tracts of both sides, and of the optic commissure; total blindness for twelve or fourteen years, 334.
Auricle, right, false aneurism of the heart, probably communicating with the, 87.
Axilla, large glandular tumor from the, simulating the characters of scirrhus, 377.

Basilar artery, aneurism of the, associated with total deafness, 122.
Bile-ducts, hæmorrhage proceeding along the, from one of the hydatid cysts, in a case of hydatids of the liver, 222.
Bladder, great hypertrophy and sacculation of, in a man æt. 42, 248.
„ diseased and sacculated, 253.
„ female, calculus in the, impeding parturition, removed by operation, 257.
„ of a lady, æt. about 40, lithic acid calculus removed from the, 260.
„ villous disease of the, 256.
„ of the field-mouse, calculus from the, 401.
Blindness, total, for twelve or fourteen years; atrophy of the optic nerves and tracts of both sides, and of the optic commissure, 334.
Blocking up of both internal carotid arteries by coagulum, and consequent death, 111.
„ of the middle cerebral artery by a fibrinous plug, in connexion with vegetations on the aortic valves, 118.
„ „ report on, 120.
Blood, extravasation of, from bursting of an aneurism of the middle cerebral artery; death in a few hours, 127.
Bone, deposit of, on the dura mater, 4.
„ new, development of, repairing the loss in a case of necrosis of the lower jaw, 284.
„ occipital, fracture of the, with bony union, 282.
„ temporal, extraction of greater part of the petrosal portion of the, from the left ear of a boy, including the meatus auditorius internus and labyrinth, separated by necrosis, 335.
Bones of the cranium, carcinoma of the, and of the vertebræ, &c. 383.
Bone-structure, true, in a calcareous deposit of unusual size, in an iliac vein, 133.
Bony union in fracture of the occipital bone, 282.
„ in longitudinal fracture through the great trochanter and upper part of the shaft of the femur; impacted fracture of the cervix ununited by bone, 301.
Bowel, invagination of a portion of, producing ileus, 199.
Bowels and stomach, hæmorrhage into the, from one of the hydatid cysts, in a case of hydatids of the liver, 222.
Brain, large circumscribed tumor from the, 7.
„ yellow softening and abscesses within the substance of the middle-lobe of the, 14.
„ gangrenous abscess of the, induced by disease of the internal ear, 17.
„ cases of tumor from the, 18, 21.
„ „ reports on, 20, 25.
„ laminated tumor within the, formed by an aneurism of the posterior cerebral artery, 129.
„ softening of the, with carditis; fibrinous deposits in the spleen, &c. from a case of, 168.
„ „ report on, 172.
Bronchial tubes, fibrinous casts of the, 56.

Cæcal appendix, perforation of,

Cæcal appendix, *continued.*
from an intestinal concretion, 210.
Cæcum, &c. intussusception of the, into the colon in an adult; death after four months' symptoms, 193.
Calcareous deposit of unusual size, containing true bone-structure, in an iliac vein, 133.
„ particles, submucous cysts containing, in herpes phlyctenodes in the horse, associated with extensive scabs on the mucous membrane of the colon, 398.
Calcified pericardium in a case of cerebral apoplexy, with a multitude of small gall-stones in the gall-bladder, 72.
„ „ report on the calcified pericardium, 73.
„ dentine, specimens of imperfectly, 178.
Calculous matter removed from a boy, æt. 10, by the operation of lithotrity, 258.
Calculus lithic acid, removed by dilatation from the bladder of a lady, æt. about 40, 260.
„ in the female bladder, impeding parturition, removed by operation 257.
„ from the bladder of the field-mouse; mus sylvaticus, 401.
„ impacted, with sacculated kidney, 263.
Cancer, seat of, specimens illustrating, 387.
„ (?) of the lungs, with irreducible omental hernia, 70.
„ intra-thoracic, 49.
„ melanic, in the horse, 400.
Cancerous growth, large, of the kidney, in a child, 268.
„ ulceration of the mamma, which perforated the walls of the chest, so as to form a free opening into the cavity of the pleura, 45.
Cancrum oris, necrosis of the symphysis, &c. of the lower jaw, consequent upon. Reparation of the loss by new bone, 284.
Capsules, supra-renal, diseased, 270.
Capsules, *continued.*
„ „ report on, 270.
Carbonate of lime, deposit of, on lining membrane of gall-bladder, 238.
Carditis, with softening of the brain, fibrinous deposits in the spleen, &c. from a case of, 168.
„ „ report on, 172.
Carcinoma of the bones of the cranium, the vertebræ, the ribs, and most of the internal organs of the body, 383.
Carcinomatous melanotic deposit connected with the dura mater, the lining of the ventricles, and the seventh and ninth pairs of cranial nerves, 5.
„ growth pressing upon the cervical part of the spinal cord, and producing paraplegia, 40.
Cardiac end of the œsophagus, malignant disease of the, 188.
„ clots, report on, 137.
„ appendix of cases, tabulated, 153.
Caries and scrofulous necrosis of dorsal and lumbar vertebræ, without psoas abscess, but with abscess passing upwards and backwards, and opening externally, 290.
Carnification, disseminated, with emphysema of the right lung, in an infant, 67.
Carotid arteries, blocking up of both internal, by coagulum, and consequent death, 111.
Cast, fibrinous, expectorated in a case of hæmoptysis, 54.
Casts, fibrinous, of the bronchial tubes, 56.
Cataracts of adults, on the cortical and nuclear, 330.
Cephaloma of the lungs, 69.
Cerebellum, tumor of the, 28.
„ large cyst pressing on the under surface of the, 33.
Cerebral apoplexy, calcified pericardium in a case of, 72.
„ „ report on, 73.
„ and pulmonary apoplexy; softening clots in the heart, &c. 134.

Cerebral, *continued.*
„ artery, middle, obstruction of the, by a fibrinous plug, in connexion with vegetations on the aortic valves, 118.
„ „ report on, 120.
„ „ middle, aneurism of the, 125.
„ „ middle, aneurism of the; extravasation of blood from bursting thereof; death in a few hours, 127.
„ „ posterior, aneurism of the, forming a laminated tumor within the brain, 129.
Cervix uteri and vagina, great elongation of the, in a case of enormous ovarian tumor, 273.
„ „ report on the case, 276.
Cheek, pulsating erectile tumor in the, 375.
Chronic inflammation and ossification of the membranes of the spinal cord, 35.
Circulation, diseases, &c. of the, 72–178.
Cirrhosis of the liver, accompanied with profuse hæmorrhage into the stomach and intestines, 227.
„ of liver; hypertrophied spleen; leuchœmia, &c. 238.
Clots, softening in the heart, in a case of associated renal disease; hypertrophy of the heart; pulmonary and cerebral apoplexy, 134.
„ softening, report on, 137.
„ „ appendix of cases, tabulated, 153.
Coagulum, blocking up of both internal carotid arteries by, and consequent death, 111.
„ encysted, in the arachnoid cavity, 6.
„ fibrinous, obstructing the left common iliac artery, and causing gangrene of the leg, 175.
Colon, intussusception of the cæcum and part of the ileum into the, in an adult; death after four months' symptoms, 193.
Colon, *continued.*
„ stricture of the sigmoid flexure of the, with perforating ulcer, fatal five weeks after labour, 206.
„ villous disease of the, 212.
„ extensive scabs on the mucous membrane of the, associated with submucous cysts containing calcareous particles in herpes phlyctenodes in the horse, 398.
Concretion, intestinal, perforation of the cæcal appendix from an, 210.
Congenital communication between a malformed œsophagus and trachea, 52.
„ malformation of the heart in a youth, 85.
„ malformation, unique, associated with umbilical hernia, and a pendulous artificial anus, 216.
„ probable, cystic disease of the testis, in an infant, 241.
„ absence of the uterus and its appendages, 271.
Contraction of the pulmonary orifice, 80.
„ of the pulmonary orifice and artery, 83.
Coronary arteries of the heart and their branches, aneurismal dilatations of the, 98.
Corpus striatum, the left, large cyst in the, 8.
Cranium, bones of the, carcinoma of the, and of the vertebræ, &c. 383.
Crural hernia, omental, spontaneously cured, 219.
Cyst, large, in the left corpus striatum, in connexion with atrophy and partial paralysis of the right arm. Also partial paralysis, without atrophy of the right leg, 8.
„ „ containing six ounces of fluid, pressing on the under surface of the cerebellum, and occupying the fourth ventricle, 33.
„ thick wall, in the tunica albuginea testis, 246.
Cystic growth developed in the mammary gland, 378.

Cystic disease of the liver, associated with similar disease of the kidneys, 229.
" " report on, 234.
" " of the liver and kidney, 235.
" " of the testis occurring in an infant, and probably congenital, 241.
Cysto-myeloid tumor of the upper head of the tibia, 318.
" " report on, 320.
Cysts, hydatid, hæmorrhage from one of the, in a case of hydatids of the liver, 222.
" submucous, containing calcareous particles in herpes phylctenodes in the horse, associated with extensive scabs on the mucous membrane of the colon, 398.

Deafness, total, associated with aneurism of the basilar artery, 122.
Dentine, imperfectly calcified, specimens of, 178.
" of repair, specimen of, 184.
Deposit of bone on the dura mater, 4.
" melanotic carcinomatous, connected with the dura mater, the lining of the ventricles, and the seventh and ninth pairs of cranial nerves, 5.
" fibrinous, in the substance of the heart, 167.
" " examination of, 168, 347.
" fibrinous, in the spleen, &c. from a case of carditis with softening of the brain, 168.
" " report on, 172.
" fibrinous, large quantity of, within the substance of the kidney, &c. perfectly converted into fat, 177.
" fibro-cellular, occupying the left optic thalamus, 12.
" calcareous, of unusual size, containing true bone-structure, in an iliac vein, 133.
" of carbonate of lime on lining membrane of gall-
Deposit, *continued.*
bladder; leuchœmia; cirrhosis of liver, &c. 238.
" of crystalline urate of soda in the cavity of the knee-joints, 311.
Digestion, diseases, &c. of the organs of, 178-240.
Dilatation and absorption of the kidney, with stricture of the ureter, 262.
Dilatations, aneurismal, of the coronary arteries of the heart and their branches, 95.
Dissecting aneurism of the aorta, 106.
" abscess, extensive, of the lower extremity, from pyæmia, 381.
Diverticulum, true, falling of some folds of intestine over a, and twist in the mesentery, producing fatal intestinal obstruction, 205.
Ductus arteriosus, osseous state of the, 80.
" " absence of the, 83.
Dura mater, fibro-fatty tumor of the, 1.
" " deposit of bone on the, 4.
" " melanotic carcinomatous deposit connected with the, 5.
" " &c. recurrent tumor on the, following a similar growth in the left orbit, 337.

Ear, left, of a boy, extraction from the, of greater part of the petrosal portion of the temporal bone, including the meatus auditorius internus and labyrinth, separated by necrosis, 335.
" the internal, gangrenous abscess of the brain induced by disease of, 17.
Effusion, extensive, in the pericardium, 79.
Elbow-joint, excision of the, parts removed in an, 321.
" ossific pendulous growths in the, 324.
Emphysema and disseminated car-

Emphysema, *continued.*
nification of the right lung in an infant, 67.
Encysted coagulum in the arachnoid cavity, 6.
Enlarged heart, specimen of, 95.
Enlargement of the prostate due to fibrous tumors; diseased and sacculated bladder, 253.
Enteritis from hardened fæces in the appendix vermiformis, 211.
Entozoa, tumors, &c. 337–402.
Epithelium, ciliated, covering intracystic growths, in a case of multilocular ovarian tumor, 280.
Erectile pulsating tumor in the cheek, 375.
Excision of the head of the femur, for disease of the hip-joint, 302.
„ of the knee-joint, the parts involved in an, showing abscesses in the head of the tibia, 314.
„ of the elbow-joint, parts removed in an, 321.

Fat, large quantity of fibrinous deposit perfectly converted into, 177.
Femoral hernia, strangulated, specimen of, 219.
Femoris, cervix, impacted fracture of the, ununited by bone; longitudinal fracture through the great trochanter and upper part of the shaft, with bony union, 301.
Femur, excision of the head of the, for disease of the hip-joint, 302.
„ both condyles of the, necrosis symmetrically affecting, and communicating with the knee-joint, 307.
„ fibro-cystic tumor involving the condyles and lower part of the, 358.
„ „ report on, 361.
„ *see also* Thigh-bone.
Fever, typhus, necrosis of the condyle, &c. of the lower jaw after, 283.
Fibrinous cast expectorated in a case of hæmoptysis, 54.
Fibrinous, *continued.*
„ casts of the bronchial tubes, 56.
„ coagulum, obstructing the left common iliac artery, and causing gangrene of the leg, 175.
„ deposit, large quantity of, within the substance of the kidney, the supra-renal capsule and the renal and supra-renal veins, perfectly converted into fat, 177.
„ deposits in the substance of the heart, 167.
„ „ examination of, 168.
„ deposits in the spleen, kidneys, &c. from a case of carditis, with softening of the brain, 168.
„ „ report on, 172.
„ plug, obstruction of the middle cerebral artery by a, in connexion with vegetations on the aortic valves, 118.
„ „ report on, 120.
Fibrinous-like vegetations of the aorta, 87.
Fibro-cellular deposit occupying the left optic thalamus, 12.
Fibro-cystic tumor involving the condyles and lower part of the femur, 358.
„ „ report on, 361.
Fibro-fatty tumor of the dura mater, 1.
Fibrous tumors, enlargement of the prostate due to, 253.
„ „ multiple, example of, 340.
Field-mouse, calculus from the bladder of the, 401.
Fracture of the occipital bone, with bony union, 282.
„ of the patella, cast showing a rupture of the ligamentum patellæ subsequent to, 315.
„ compound, of the thigh, with laceration of the main vessels, produced by a ramrod discharged from a cannon, 305.
„ „ impacted, of the cervix femoris ununited by bone; longitudinal fracture

Fracture, *continued.*
through the great trochanter and upper part of the shaft, with bony union, 301.
„ impacted, section of an, of the neck of the thigh-bone, from a subject diseased with mollities ossium, 302.
Fungus, the characteristic, of ringworm, hairs and crusts showing peculiarities in the, 395.
„ the vegetable, of common ringworm, 397.
„ vegetable, microscopic specimens of the, found in two cases of pityriasis versicolor, 397.

Gall-bladder, deposit of carbonate of lime on lining membrane of the, 238.
„ multitude of gall-stones in the, 72.
Gall-stones, multitude of in the gall-bladder, 72.
Gangrene of the leg, caused by a fibrinous coagulum obstructing the left common iliac artery, 175.
Gangrenous abscess of the brain, induced by disease of the internal ear, 17.
Gastric fluid, perforation of œsophagus by, in a case of hooping-cough, 65.
Generative organs, diseases, &c. of, 241–282.
Gland, prostate, tumor of the, 251.
„ „ enlargement of the, due to fibrous tumors, 253.
„ „ intra-glandular tumor of the, 256.
„ mammary, cystic growth developed in the, 378.
Glands, lumbar, liver, &c. portions of the, of a man who died five months after the removal of a testicle for malignant disease, 386.
Glandular mammary tumor, 376.
„ tumor, large, from the axilla, simulating the characters of scirrhus, 377.
Growth, cancerous, large, of the kidney, in a child, 268.
„ carcinomatous, pressing upon the cervical part of the spinal cord, and producing paraplegia, 40.
„ cystic, developed in the mammary gland, 378.
„ polypoid, from the verumontanum, 250.
„ warty, on the palate, 187.
Growths, intra-cystic, covered with ciliated epithelium, in a case of multilocular ovarian tumor, 280.
„ ossific pendulous, in the elbow-joint, 324.

Hæmorrhage into the stomach and bowels from one of the hydatid cysts, in a case of hydatids of the liver, 222.
„ profuse, into the stomach and intestines, accompanying cirrhosis of the liver, 227.
„ gradual, into the pericardium, death caused by, in a case of rupture of an aneurismal pouch of the root of the aorta, 102.
Hairs and crusts from a case of ringworm, showing peculiarities in the growth of the characteristic fungus, 395.
Head, recurrent tumor of the right side of the, on the dura mater, &c. following a similar growth in the opposite orbit, 337.
Heart, aneurism of the, 96.
„ diseased, specimens of, 88.
„ case of diseased, 97.
„ enlarged, specimen of, with the thickening of the mitral and tricuspid valves, 95.
„ fibrinous deposits in the substance of the, 167.
„ „ examination of, 168, 347.
„ hypertrophy of the, with diseased valves, 93.
„ hypertrophy of the, softening clots in the, &c. 134.
„ malformation of the, two cases of, 80.
„ congenital malformation of the, in a youth, 85.
„ softening clots in the, in a

Heart, *continued.*
case of associated renal disease, 134.
„ disease of the texture of the, adjoining the aortic valves, and formation of a false aneurism of the, 87.
„ right ventricle of the, aneurism of the ascending aorta bulging into the, 104.
„ coronary arteries of the, and their branches, aneurismal dilatations of the, 98.
„ liver, &c. portions of the of a man who died five months after the removal of a testicle for malignant disease, 386.
Hernia, strangulated femoral, specimen of, 219.
„ crural omental, spontaneously cured, 219.
„ umbilical, associated with unique congenital malformation, and a pendulous artificial anus, 216.
„ case of triple umbilical, containing various portions of the abdominal viscera, 220.
„ irreducible omental, 70.
Herpes phlyctenodes in the horse, extensive scabs on the mucous membrane of the colon, associated with submucous cysts, containing calcareous particles in, 398.
Hip-joint, disease of the, excision of the head of the femur for, 302.
„ amputation at the, for large malignant tumor of the thigh, 357.
Hooping-cough, lungs of four children who died from, 57; exhibiting — sub - pleural ecchymosis, 59; catarrhal or vesicular pneumonia, 59, 60, 63; collapse, 59, 60, 63, 65; double pleurisy, 63.
„ perforation of the œsophagus by gastric fluid in a case of, 65.
„ inflammation and ulceration of Peyerian and solitary glands of intestine in a case of, 63.
Horse, extensive scabs on the mucous membrane of the colon, associated with submucous cysts containing calcareous particles in herpes phlyctenodes in the horse, 398.
„ melanic cancer in the, 400.
Humerus, myeloid tumor of the, 351.
Hydatids of the liver, attended with hæmorrhage into the stomach and bowels, proceeding along the bile-ducts from one of the hydatid cysts, 222.
„ in the liver, 225.
Hypertrophied spleen; leuchœmia; cirrhosis of the liver, &c. 238.
Hypertrophy of the heart, with diseased valves, 93.
„ „ softening clots in the, &c. 134.
„ and sacculation, great, of of bladder, in a man, æt. 42, 248.

Ileum, part of the, &c. intussusception of the, into the colon, in an adult; death after four months' symptoms, 193.
Ileus, case of, produced by invagination of a portion of the bowel, which was subsequently discharged by stool, 199.
Iliac artery, left common, fibrinous coagulum obstructing the, and causing gangrene of the leg, 175.
„ vein, calcareous deposit of unusual size, containing true bone structure in an, 133.
Impacted calculus, with sacculated kidney, 263.
„ fracture of the cervix femoris ununited by bone; longitudinal fracture through the great trochanter and upper part of the shaft, with bony union, 301
„ fracture, section of an, of the neck of the thigh-bone, from a subject diseased with mollities ossium, 302.
Infant, cystic disease of the testis in an, probably congenital, 241.

Infant, *continued.*
„ lobar pneumonia of the whole of the left lung, and disseminated carnification, with emphysema of the right lung in an, 67.
„ extensive dissecting abscess in the lower extremity of an, 381.
Inflammation and ulceration of Peyerian and solitary glands of intestine, &c. in a case of hooping-cough, 63.
„ chronic, and ossification of the membranes of the spinal cord, 35.
Internal strangulation of small intestine, 198.
Intestinal concretion, perforation of the cæcal appendix from an, 210.
„ obstruction, fatal, in consequence of a twist in the mesentery, and the falling of some folds of intestine over a true diverticulum, 205.
Intestine, Peyerian and solitary glands of, inflammation and ulceration of, in a case of hooping-cough, 63.
„ falling of some folds of, over a true diverticulum, and twist in the mesentery, producing fatal intestinal obstruction, 205.
„ small, internal strangulation of, 198.
„ small, strangulation and ulceration of the, 222.
Intestines and stomach, profuse hæmorrhage into the, accompanying cirrhosis of the liver, 227.
Intra-glandular tumor of the prostate, 256.
Intussusception of the cæcum and part of the ileum into the colon, in an adult; death after four months' symptoms, 193.
Intra-thoracic cancer, 49.
Invagination of a portion of bowel, producing ileus, 199.
„ in a tubular form, rupture, and inversion, of portion of the inner and middle coats of the aorta, 131.
Inversion, rupture, and invagination, in a tubular form, of portion of the inner and middle coats of the aorta, 131.

Jaw, lower, necrosis of the condyle, the angle, and part of the horizontal ramus of the, after typhus fever, 283.
„ lower, necrosis of the symphysis and portions of the horizontal rami of the, consequent upon cancrum oris; reparation of the loss by new bone, 284.
Joint, elbow, parts removed in an excision of the, 321.
„ elbow, ossific pendulous growths in the, 324.
„ hip, amputation at the, for large malignant tumor of the thigh, 357.
„ knee, ankylosis of the, in an aged male subject, 312.
„ knee, softened ankylosis of the, 313.
„ knee, excision of the, parts involved in an, showing abscesses in the head of the tibia, 314.
„ knee, necrosis symmetrically affecting both condyles of the femur, and communicating with the, 307.
„ knee, disease of the, with talipes equino-varus, 392.
Joints, knee, deposit of crystalline urate of soda in the cavity of the, 311.

Kidney, absorption and dilatation of the, with stricture of the ureter, 262.
„ sacculated, with impacted calculus, 263.
„ a single, found in the body, of a horse-shoe shape, 264.
„ large cancerous growth of the, in a child, 268.
„ &c. large quantity of fibrinous deposit within the substance of the, perfectly converted into fat, 177.
„ and liver, cystic disease of the, 235.
Kidneys, atrophied, 265.

Kidneys, *continued.*
„ „ report on, 265.
„ cystic disease of the, associated with similar disease of the liver, 229.
„ „ report on, 234.
„ &c. fibrinous deposits in the, from a case of carditis with softening of the brain, 168.
„ „ report on, 172.
Knee-joint, ankylosis of the, in an aged male subject, 312.
„ softened ankylosis of the, 313.
„ excision of the, the parts involved in an, showing abscesses in the head of the tibia, 314.
„ necrosis symmetrically affecting both condyles of the femur, and communicating with the, 307.
„ disease of the, with talipes equino varus, 392.
Knee-joints, deposit of crystalline urate of soda in the cavity of the, 311.

Laceration of the vena cava caused by a contusion of the abdomen, 131.
„ of the main vessels, and compound fracture of the thigh, produced by a ramrod discharged from a cannon, 305.
Laminated tumor within the brain, formed by an aneurism of the posterior cerebral artery, 129.
Larynx, ulceration of the, in reference to local applications, 53.
Leg, partial paralysis of the right, in connexion with a large cyst in the left corpus striatum, 8.
Leuchœmia, hypertrophied spleen, cirrhosis of liver, &c. 238.
Ligamentum patellæ, rupture of the, cast showing a, subsequent to fracture of the patella, 315.
Lime, carbonate of, deposit of, on lining membrane of gall-bladder, 238.
Lithotrity, calculous matter removed from a boy, æt. 10, by the operation of, 258.
Liver, cirrhosis of the, accompanied with profuse hæmorrhage into the stomach and intestines, 227.
„ cirrhosis of, 238.
„ cystic disease of the, associated with similar disease of the kidney, 229.
„ „ report on, 234.
„ hydatids of the, attended with hæmorrhage from one of the hydatid cysts, 222.
„ hydatids in the, 225.
„ and kidney, cystic disease of the, 235.
„ lungs, &c. portions of the, of a man who died five months after the removal of a testicle for malignant disease, 386.
Lumbar glands, liver, lungs, and heart, portions of the, of a man, who died five months after the removal of a testicle for malignant disease, 386.
Lung, disseminated carnification, with emphysema of the right, and lobar pneumonia of the whole of the left, in an infant, 67.
Lungs, collapse of, in cases of hooping cough, 59, 60, 63, 65.
„ the, of four children who died from hooping-cough, 57.
„ cephaloma of the, 69.
„ cancer (?) of the, with irreducible omental hernia, 70.
„ of a pony, tubercles in the, 401.
„ liver, &c. portions of the, of a man who died five months after the removal of a testicle for malignant disease, 386.

Magnesia, drawing of warts which disappeared under the use of, 380.
Malformation of the heart, two cases of, 80.
„ congenital, of the heart, in a youth, 85.
„ unique congenital, associated with umbilical hernia, and a pendulous artificial anus, 216.

Malformed trachea and œsophagus, and congenital communication between them, 52.
Malignant disease in the anterior mediastinum and in other organs, 47.
" disease of the cardiac end of the œsophagus, 188.
" " portions of the lumbar glands, liver, &c. of a man who died five months after the removal of the testicle for, 386.
" tumor, large, growing from the orbit, 324.
" " report on, 327.
" tumor, large, of the thigh, for which amputation was performed at the hip-joint, 357.
Mamma, cancerous ulceration of the, which perforated the walls of the chest, forming a free opening into the cavity of the pleura, 45.
Mammary gland, cystic growth developed in the, 378.
" glandular tumor, 376.
Mediastinum, anterior, malignant disease in the, 47.
Melanic cancer in the horse, 400.
Melanotic carcinomatous deposit connected with the dura mater, the lining of the ventricles, and the seventh and ninth pairs of cranial nerves, 5.
Miscellaneous specimens, tumors, entozoa, &c. 337–402.
Mesentery, fatal intestinal obstruction in consequence of a twist in the, and the falling of some folds of intestine over a true diverticulum, 205.
Mitral and aortic valves, disease of the, 91.
" and tricuspid valves, thickening of the, 95.
Mollities ossium, section of an impacted fracture of the neck of the thigh-bone, from a case of, 302.
Mouse, field, calculus from the bladder of a, 401.
Mucous membrane of the colon, extensive scabs on the, associated with submucous cysts containing calcareous particles in herpes phlyctenodes in the horse, 398.
Mucous membrane, *continued.*
Myeloid tumor of the humerus, 351.
" " of the head of the tibia, 355.

Necrosis of the condyle, the angle, and part of the horizontal ramus of the lower jaw, after typhus fever, 283.
" of the symphysis and portions of the horizontal rami of the lower jaw, consequent upon cancrum oris; reparation of the loss by the development of new bone, 284.
" symmetrically affecting both condyles of the femur, and communicating with the knee-joint, 307.
" scrofulous, and caries of dorsal and lumbar vertebræ, without psoas abscess, but with abscess passing upwards and backwards, and opening externally, 290.
" meatus auditorius internus and labyrinth, separated by, extracted from the left ear of a boy, 335.
Nerves, cranial, melanotic carcinomatous deposit connected with the seventh and ninth pairs of, 5.
" and tracts, optic, of both sides, atrophy of the, and of the optic commissure, 334.
Nervous system, diseases, &c. of the, 1–45.

Obliteration, total, of the inferior vena cava of old standing, 177.
Obstruction of the middle cerebral artery by a fibrinous plug, in connexion with vegetations on the aortic valves, 118.
" " report on, 120.
" of both internal carotid arteries by coagulum, and consequent death, 111.
" fatal intestinal, in consequence of a twist in the me-

Obstruction, *continued.*
sentery, and the falling of some folds of intestine over a true diverticulum, 205.
Occipital bone, fracture of the, with bony union, 282.
Œsophagus, malignant disease of the cardiac end of the, 188.
„ perforation of, by gastric fluid, in a case of hooping-cough, 65.
„ and trachea, malformed, and congenital communication between them, 52.
Oil of almonds, essential; stomach in a case of poisoning by, 189.
Omental crural hernia, spontaneously cured by adhesion of the omentum around the neck of the sac, from a female, 219.
„ hernia, irreducible, 70.
Optic thalamus, the left, fibro-cellular deposit occupying, 12.
„ nerves and tracts of both sides, atrophy of the, and of the optic commissure, 334.
Orbit, large malignant tumor growing from the, 324.
„ „ report on, 327.
„ recurrent tumor of the, followed by similar growths on the other side of the head, on the dura mater, &c. 337.
Osseous system, diseases, &c. of the, 282–324.
„ state of the ductus arteriosus, 80.
Ossific growths, pendulous, in the elbow-joint, 324.
Ossification of the membranes of the spinal cord, 35.
Osteo-sarcoma, report on a specimen of, 372.
Ovarian tumor, weighing one-hundred and six pounds; great elongation of the cervix uteri and vagina, 273.
„ „ report on, 276.
„ tumor, multilocular, with intra-cystic growths covered with ciliated epithelium, 280.

Papilloma, or warty growth on the palate, 187.
Paralysis, partial, of the right arm
Paralysis, *continued.*
and leg, in connexion with a large cyst in the left corpus striatum, 8.
Paraplegia, produced by a carcinomatous growth pressing upon the cervical part of the spinal cord, 40.
Parturition, calculus in the bladder impeding, removed by operation, 257.
Patella, fracture of the, cast showing a rupture of the ligamentum patellæ subsequent to, 315.
Pelvis, oblique ovata, from a female subject, 292.
Perforating ulcer of the stomach, 191.
„ ulcer, with stricture of the sigmoid flexure of the colon, fatal five weeks after labour, 206.
Perforation of the œsophagus by gastric fluid, in a case of hooping-cough, 65.
„ of cæcal appendix from an intestinal concretion, 210.
Pericardium, extensive effusion in the, 79.
„ death caused by gradual hæmorrhage into the, in a case of rupture of an aneurismal pouch of the root of the aorta, 102.
„ calcified, in a case of cerebral apoplexy, 72.
„ „ report on, 73.
Peyerian and solitary glands of intestine, inflammation and ulceration of, in a case of hooping-cough, 63.
Pityriasis versicolor, microscopic specimens of the vegetable fungus found in two cases of, 397.
Pleura, cavity of the, free opening into the, formed by a cancerous ulceration of the mamma perforating the walls of the chest, 45.
„ costal, &c. recurrent tumor on the, following a similar growth in the left orbit, 337.
Pleurisy, double, &c. in a case of hooping-cough, 63.

Plug, fibrinous, obstructing the middle cerebral artery, in connexion with vegetations on the aortic valves, 118.
„ „ report on, 120.
Pneumonia, lobar, of the whole of the left lung, and disseminated carnification, with emphysema of the right lung, in an infant, 67.
„ catarrhal or vesicular, in cases of hooping-cough, 59, 60, 63.
Poisoning by essential oil of almonds, stomach in a case of, 189.
Polypoid growth from the verumontanum, 250.
Pons Varolii, tumor on the, 26.
Pony, tubercles in the lung of a, 401.
Pouch, aneurismal, rupture of an, of the root of the aorta, 102.
„ „ of the septum of the ventricle, associated with aneurism of the ascending aorta, 104.
Procidentia uteri of large size, 271.
Prostate gland, tumor of the, 251.
„ enlargement of the, due to fibrous tumors, 253.
„ intra-glandular tumor of the, 256.
Pulmonary artery, aneurism of the aorta compressing the, and causing death by angina pectoris, 102.
„ artery, orifice of the, aneurism of the ascending aorta considerably obstructing the, 104.
„ orifice, contraction of the, with imperfection of the septum ventriculorum, and an osseous state of the ductus arteriosus, 80.
„ orifice and artery, contraction of the, with imperfection of the septum ventriculorum, and absence of the ductus arteriosus, 83.
„ and cerebral apoplexy; softening clots in heart, &c. 134.
Pulsating erectile tumor in the cheek, 375.
Pyæmia, extensive dissecting abscess of the lower extremity from, 381.
Pyæmia, *continued.*

Recurrent tumor of the orbit, followed by similar growths on the other side of the head, on the dura mater, and under the costal pleura, 337.
Renal disease, softening clots in the heart in a case of associated, 134.
„ and supra-renal veins, &c. large quantity of fibrinous deposit within the substance of the, perfectly converted into fat, 177.
Repair, dentine, specimen of, 184.
Reparation of the loss in a case of necrosis of the lower jaw, by the development of new bone, 284.
Report on softening clots, 137.
„ „ appendix of cases, tabulated, 153.
„ on a case of tumor of the brain, 20; of ditto, 25; of calcified pericardium, in a case of cerebral apoplexy, 73; of obstruction of the middle cerebral artery by a fibrinous plug, in connexion with vegetations on the aortic valves, 120; of fibrinous deposits in the substance of the heart, 168, 347; of fibrinous deposits in the spleen, kidneys, &c. from a case of carditis, with softening of the brain, 172; of cystic disease of the liver, associated with similar disease of the kidneys, 234; of atrophied kidneys, 265; of diseased supra-renal bodies, 270; of ovarian tumor weighing one hundred and six pounds, 276; of crude tubercle in the tibia, 317; of cysto-myeloid tumor of the upper head of the tibia, 320; of large malignant tumor growing from the orbit, 327; of tumor in connexion with the scapula, 347; of fibro-cystic tumor involving the condyles and lower part

Report, *continued.*
of the femur, 361; of osteosarcoma, 372.
Respiration, diseases, &c. of the organs of, 45–72.
Ribs, carcinoma of the, and of the cranial bones, &c. 383.
Ringworm, hairs and crusts from a case of, showing peculiarities in the growth of the characteristic fungus, 395.
„ common, the vegetable fungus of, 397.
Rupture of an aneurismal pouch of the root of the aorta, 102.
„ cast showing a, of the ligamentum patellæ, subsequent to fracture of the patella, 315.
„ inversion, and invagination, in a tubular form, of portion of the inner and middle coats of the aorta, 131.

Sacculated kidney, with impacted calculus, 263.
„ and diseased bladder, 253.
Sacculation and hypertrophy, great, of bladder in a man æt. 42. 248.
Scapula, tumor in connexion with the, 346.
„ „ report on, 347.
Scirrhus, large glandular tumor in the axilla simulating the characters of, 377.
Scrofulous necrosis and caries of the two last dorsal and two upper lumbar vertebræ, without psoas abscess, but with abscess passing backwards and upwards, and opening externally, 290.
Septum ventriculorum, imperfection of the, 80, 83.
„ of the ventricle, aneurismal pouch of the, associated with aneurism of the ascending aorta, 104.
Sigmoid flexure of the colon, stricture of the, with perforating ulcer, fatal five weeks after labour, 206.
Softening, yellow, within the substance of the middle lobe of the brain, 14.
„ of the brain, with cardi-
Softening, *continued.*
tis, fibrinous deposits in the spleen, &c. from a case of, 168.
„ „ report on, 172.
„ clots in the heart, in a case of associated renal disease, 134.
„ clots, report on, 137.
„ „ appendix of cases, tabulated, 153.
Solitary glands of intestine, inflammation and ulceration of, in a case of hooping-cough, 63.
Special sense, diseases, &c. of the organs of, 324–337.
Specimens of imperfectly calcified dentine, 178.
Spinal cord, carcinomatous growth pressing upon the cervical part of the, and producing paraplegia, 40.
„ cord, chronic inflammation and ossification of the membranes of the, 35.
„ cord, tumor of the, 37.
„ „ tumor connected with the, 41.
„ column, ankylosis at the upper end of the, 285.
„ „ report on, 288.
Spleen, hypertrophied, 238.
„ &c. fibrinous deposits in the, from a case of carditis with softening of the brain, 168.
„ „ report on, 172.
Stomach in a case of poisoning by essential oil of almonds, 189.
„ perforating ulcer of the, 191.
„ and bowels, hæmorrhage into the, from one of the hydatid cysts in a case of hydatids of the liver, 222.
„ and intestines, profuse hæmorrhage into the, accompanying cirrhosis of the liver, 227.
Strangulated femoral hernia, specimen of, 219.
Strangulation, internal, of small intestine, 198.
„ and ulceration of the small intestine, 222.
Stricture of the sigmoid flexure of

Stricture, *continued.*
the colon, with perforating ulcer, fatal five weeks after labour, 206.
„ of the ureter, with extensive absorption and dilatation of the kidney, 262.
„ of the urethra; great hypertrophy and sacculation of bladder in a man æt. 42, 248.
Submucous cysts containing calcareous particles in herpes phlyctenodes in the horse, associated with extensive scabs on the mucous membrane of the colon, 398.
Supra-renal bodies, diseased, 270.
„ „ report on, 270.
„ capsule and veins, &c. large quantity of fibrinous deposit within the substance of the, perfectly converted into fat, 177.

Talipes equino-varus, with disease of the knee-joint, 392.
Temporal bone, extraction of greater part of the petrosal portion of the, from the left ear of a boy, including the meatus auditorius internus, and labyrinth, separated by necrosis, 335.
„ „ disease of the tympanic cavity of the, 14.
Testicle, portions of the lumbar glands, liver, &c. of a man who died five months after the removal of the, for malignant disease, 386.
Testis, cystic disease of the, occurring in an infant, and probably congenital, 241.
„ tunica albuginea, thick wall cyst in the, 246.
Thigh, large malignant tumor of the, for which amputation was performed at the hip-joint, 357.
Thigh-bone, compound fracture of the, with laceration of the main vessels, produced by a ramrod discharged from a cannon, 305.
„ impacted fracture of the neck of the, section of an, from a case of mollities ossuim, 302.
„ *see also* Femur.
Tibia, abscesses in the head of the, shown in the parts involved in an excision of the knee-joint, 314.
„ „ report on, 320.
„ crude tubercle in the, 316.
„ „ report on, 317.
„ myeloid tumor of the head of the, 355.
„ upper head of the, cysto-myeloid tumor of the, 318.
Tinea tonsurans, common ringworm, the vegetable fungus of, 397.
Trachea and œsophagus, malformed, and congenital communication between them, 52.
Tricuspid and mitral valves, thickening of the, 95.
Tubercle, crude, in the tibia, 316.
„ „ report on, 317.
Tubercles in the lungs of a pony, 401.
Tumor, large circumscribed, from the brain, 7.
„ from the brain, 18, 21; reports on, 20, 25.
„ on the pons Varolii, 26.
„ of the cerebellum, 28.
„ of the spinal cord, 37.
„ connected with the spinal cord, 41.
„ of the prostate gland, 251.
„ in connexion with the scapula, 346.
„ „ report on, 347.
„ fibro-cystic involving the condyles and lower part of the femur, 358.
„ „ report on, 361.
„ fibro-fatty, of the dura mater, 1.
„ intra-glandular of the prostate, 256.
„ large glandular, from the axilla, simulating the characters of scirrhus, 377.
„ mammary glandular, 376.
„ laminated, within the brain, formed by an aneurism of the posterior cerebral artery, 129.

Tumor, *continued.*
„ large malignant, growing from the orbit, 324.
„ „ report on, 327.
„ „ of the thigh, for which amputation was performed at the hip-joint, 357.
„ myeloid, of the humerus, 351.
„ myeloid, of the head of the tibia, 355.
„ cysto-myeloid of the upper head of the tibia, 318.
„ „ report on, 320.
„ ovarian, weighing one hundred and six pounds, 273.
„ „ report on, 276.
„ multilocular ovarian, with intra-cystic growths covered with ciliated epithelium, 280.
„ pulsating erectile, in the cheek, 375.
„ recurrent of the orbit, followed by similar growths on the other side of the head, on the dura mater, &c. 337.
Tumors, fibrous enlargement of the prostate due to, 253.
„ multiple fibrous, example of, 340.
„ entozoa, &c. 337–402.
Tunica albuginea testis, thick wall cyst in the, 246.
Tuphlo-enteritis from hardened fæces in the appendix vermiformis, 211.
Tympanic cavity of the temporal bone, disease of the, 14.
Typhus fever, necrosis of the condyle, &c. of the lower jaw after, 283.

Ulcer, perforating, of the stomach, 191.
„ perforating, with stricture of the sigmoid flexure of the colon, fatal five weeks after labour, 206.
Ulceration of the larynx in reference to local applications, 53.
„ of Peyerian and solitary glands of intestine, &c. in a case of hooping-cough, 63.
„ cancerous, of the mamma, which perforated the walls of the chest, forming a free opening into the cavity of the pleura, 45.
„ and strangulation of the small intestine, 222.
Umbilical hernia, associated with unique congenital malformation, and a pendulous artificial anus, 216.
„ hernia, triple, containing various portions of the abdominal viscera, 220.
Urate of soda, crystalline, deposit of, in the cavity of the knee-joints, 311.
Ureter, stricture of the, with extensive absorption and dilatation of the kidney, 262.
Ureters, abnormal, from a girl, æt. 10, 261.
Urethra, structure of the; great hypertrophy and sacculation of bladder, in a man, æt. 42, 248.
Urinary and generative organs, diseases, &c. of the, 241–282.
Uteri, procidentia, of large size, 271.
„ cervix, and vagina, great elongation of the, in a case of enormous ovarian tumor, 273.
„ „ report on the case, 276.
Uterus, congenital absence of the, and its appendages, 271.

Vagina and cervix uteri, great elongation of the, in a case of enormous ovarian tumor, 273.
„ „ report on the case, 276.
Valves, diseased, with hypertrophy of the heart, 93.
„ aortic, diseased, 87, 92.
„ aortic, vegetations on the, in connexion with obstruction of the middle cerebral artery by a fibrinous plug, 118.
„ „ report on, 120.
„ aortic and mitral, disease of the, 91.
„ mitral and tricuspid, thickening of the, 95.

Vegetable fungus, the, of common ringworm, tinea tonsurans, 397.
" " microscopic specimens of the, found in two cases of pityriasis versicolor, 397.
Vegetations, fibrinous-like, of the aorta, 87.
" on the aortic valves, in connexion with obstruction of the middle cerebral artery by a fibrinous plug, 118.
" " report on, 120.
Vein, iliac, calcareous deposit of unusual size, containing true bone-structure in an, 133.
Veins, renal and supra-renal, &c. large quantity of fibrinous deposit within the substance of the, perfectly converted into fat, 177.
Vena cava, laceration of the, caused by a contusion of the abdomen, 131.
" " inferior, total obliteration of the, of old standing, 177.
Ventricle, the fourth, large cyst occupying, 38.
" right, of the heart, aneurism of the ascending aorta bulging into the, 104.
Ventricle, *continued.*
" septum of the aneurismal pouch of the, associated with aneurism of the ascending aorta, 104.
Ventricles, melanotic carcinomatous deposit connected with the lining of the, 5.
" septum of the, imperfection of the, 80, 83.
Vertebræ, carcinoma of the, and of the cranial bones, &c. 383.
" two last dorsal and two upper lumbar, scrofulous necrosis and caries of the, without psoas abscess, but with abscess passing upwards and backwards, and opening externally, 290.
Verumontanum, polypoid growth from the, 250.
Villous disease of the bladder, 256.
" " of the colon, 212.
Viscera, abdominal, case of triple umbilical hernia, containing various portions of the, 220.

Warts, drawing of, which disappeared under the use of magnesia, 380.
Warty growth on the palate, 187.

Printed by J. W. Roche, 15, Cottage Row, Bermondsey.

J. HOLZER
BINDER
BOSTON, MASS.